



# Italian Journal of Gynæcology & Obstetrics

March 2026 - Vol. 38 - N. 1 - Quarterly - ISSN 2385 – 0868

## Hamman-Macklin syndrome during labour associated with pneumothorax: a case report and a possible management

Alessio Massaro<sup>1,2</sup>, Alessandro Messina<sup>1</sup>, Alessandro Libretti<sup>3,\*</sup>, Giuseppe Delogu<sup>1</sup>, Costanza Valentini<sup>1,2</sup>, Chiara Germano<sup>1</sup>, Alessia Cassarà<sup>4</sup>, Stefano Debernardi<sup>4</sup>, Livio Leo<sup>5</sup>, Valentino Remorgida<sup>3</sup>, Bianca Masturzo<sup>1</sup>

<sup>1</sup> Department of Maternal, Neonatal and Infant Medicine, University Hospital “Degli Infermi”, Ponderano, Italy.

<sup>2</sup> Department of Obstetrics and Gynecology IU, Città della Salute e della Scienza, Sant’Anna Hospital, Turin, Italy.

<sup>3</sup> Department of Obstetrics and Gynecology, University of Eastern Piedmont, University Hospital Maggiore della Carità, Novara, Italy.

<sup>4</sup> Department of Radiology, University Hospital “Degli Infermi”, Ponderano, Italy.

<sup>5</sup> Department of Gynecology and Obstetrics, Hopital Beauregard, AUSL Valleè d’Aoste, Aosta, Italy.

### ARTICLE INFO

#### History

Received: 06 August 2025

Received in revised form: N/A

Accepted: 13 October 2025

Available online: 31 March 2026

DOI: 10.36129/jog.2025.249

#### Key words

*Hamman-Macklin syndrome; pregnancy; pneumothorax; labour; case report.*

\*Corresponding author: Alessandro Libretti, M.D. Department of Gynaecology and Obstetrics, University Hospital Maggiore della Carità, corso Mazzini 18, 28100 Novara, Italy.

Email: libretti.a@gmail.com.

ORCID: 0000-0001-8478-5471.

### ABSTRACT

**Background.** We report a case of a primigravida who decided to undergo a Trial of Labor After Caesarean (TOLAC) and developed Hamman-Macklin syndrome, a rare medical condition characterized by the occurrence of spontaneous pneumomediastinum; in our case it was associated with pneumothorax, pneumopericardium in association with the presence of free air in the retroperitoneum. The patient was asymptomatic.

**Case presentation.** The pneumomediastinum was diagnosed the presence of free air with an X-ray scan and a CT, and it was ruled out the presence of an injury in the respiratory tract with a laryngoscopy and a bronchoscopy. We suggest a standard clinical management, whose aim is to quickly diagnose the presence of free air and to consider rapidly the necessity of transfer to ICU setting. We suggest ruling out the presence of an organic lesion with diagnostic procedures such as laryngoscopy or bronchoscopy. This information can lead to different approaches in case of the necessity of invasive ventilation. The use of oxygen should be considered after performing a blood gas analysis while we suggest using antibiotics to prevent any infection.

**Conclusions.** It is desirable that the case reports be reported clearly and uniformly about this topic so that studies can be conducted with the aim of defining a standardized clinical approach to reach a consensus on the treatment of this pathology. In this article we have proposed a case management of Hamman syndrome, further studies would be needed to confirm or refute our proposals.

### INTRODUCTION

Hamman-Macklin syndrome is a rare medical condition characterized by the occurrence of

spontaneous pneumomediastinum. As proposed by Charles Clifford Macklin, the initiating factor in pneumomediastinum is thought to be a sudden rise in intra-alveolar pressure, resulting in a tear in

the alveolar membrane, and subsequent tracking of the air along the perivascular interstitial spaces towards the mediastinum [1, 2]. This condition can occur because of pathological or physiological events, such as labour during which the incidence is estimated to be 1:100,000, whereas its incidence in the general population is 1:44,000 [3-5]. Labor is an event characterized by a prolonged maintenance of high interalveolar pressure, especially during the second stage [6]. The most frequently described clinical signs in literature are subcutaneous emphysema of the neck, shortness of breath, hoarse voice, vomiting, and chest discomfort; diagnosis is based on clinical presentation, in conjunction with instrumental tests useful for confirmation such as chest CT or chest X-ray [7]. There is no specific therapy for this condition; in clinical practice, the use of analgesics, oxygen therapy, bronchodilators, and antibiotics has been described [5, 8]. We present a case report of a patient who developed pneumomediastinum, pneumothorax, pneumopericardium and free air in retroperitoneal spaces following labour, evaluating the similarities and differences compared to the published literature on this topic and suggesting for the first time a possible standardized management approach. The patient was asymptomatic. She underwent laryngoscopy and bronchoscopy that ruled out the presence of a lesion in the larynx, trachea, and broncho. The blood gas analysis was normal. The conservative management led to the reabsorption of the free air. Remarkably, during the examination a cystic lesion was found in the left lung. We cannot exclude that it might have contributed to the development of the syndrome. The lesion, without signs of malignancy, has not been typed yet and seems to be unchanged at the follow up.

## CASE PRESENTATION

In September 2022 the Department of Obstetrics and Gynaecology at our hospital admitted a 27-year-old secundigravida for premature rupture of membranes (PROM) at 40 weeks and 3 days of gestational age. The pregnancy was uncomplicated, and the vaginal-rectal swab for Group B Streptococci was negative, as was the last urine culture. In 2017, she delivered via caesarean section at 37 weeks of gestational age. She denied having any familial history of noteworthy pathology, smoking, or drinking alcohol. She suffered from congenital

hypothyroidism and was taking Levothyroxine 100 mcg/day, which was increased to 175 mcg/day during hospitalization. She underwent a tonsillectomy in childhood and denied having any allergies. During the pregnancy, she expressed the desire to undergo a Trial of Labor After Caesarean (TOLAC). At the time of admission, the Bishop score was 2, and the amniotic fluid discharging from the vagina was clear. Her body temperature was 36.5 °C, and the maternal-foetal condition was reassuring. Labor began spontaneously the next morning, approximately 12 hours after admission. Upon admission to the delivery room, the Bishop score was 7, and the foetus had a vertex presentation. Continuous cardiotocography was initiated. The first stage of labour lasted for 3 hours, during which no pathological events occurred. The second stage of labour lasted for 1 hour and 58 minutes. Despite the maternal efforts, it was necessary to perform a mediolateral episiotomy for the delivery. No indicators of foetal distress were noticed by the cardiotocography performed during the delivery. The placenta was delivered in 15 minutes. The liveborn child was male, with Apgar scores of 9/9 at 1 and 5 minutes. The weight was 4,230 g, and blood loss after delivery was 500 ml.

During the episiorrhaphy, the doctor noticed rhinolalia and subcutaneous emphysema involving both supraclavicular regions, diffuse in the cervical region, and to a lesser extent, the cheeks, especially on the right. The woman was asymptomatic and eupnoeic in ambient air. Monitoring the woman's parameters was initiated immediately. Her blood pressure was 110/80 mmHg, heart rate was 85 bpm, and haemoglobin saturation was 98% in ambient air. Despite the patient's clinical stability, an Intensive Care and Otolaryngological consultation was immediately requested. Simultaneously, a neck and chest x-ray were performed in the delivery room, confirming the presence of free air in the subcutaneous tissue, mediastinum, and pleura. A chest and neck CT scan was then urgently requested.

The otolaryngologist ruled out the presence of lesions, swelling, or oedema in the oral cavity and oropharynx, with regular nasal passages. A laryngoscopy was performed, showing a regular nasopharynx without oedema or swelling, and absence of asymmetries of the pharyngo-laryngeal space. Vocal cord motility was preserved, and respiratory space was regular. The first tracheal rings were seen through the glottic plane, and no mucosal lesions were seen.

The CT scan revealed extensive subcutaneous emphysema dissecting into the deeper soft tissue and musculature, extending from chest wall to mediastinum and neck spaces bilaterally (Figure 1, panel A, B and C). Pneumopericardium (Figure 2, panel B and C), pneumomediastinum and bilateral pneumothorax were associated (Figure 2, panel A, B and C). Additionally, an oval formation with regular profiles and low and homogeneous density, approximately 3 cm in diameter, was found in the left lung. It appears to be a fluid-filled cystic lesion (Figure 2, panel B and C). Minimal retroperitoneal bubbles have also been described in the upper tract of the ilio-psoas muscles bilaterally (Figure 3, panel A). An apparent, millimetric continuous solution of the tracheal wall was described, but without certainty (Figure 3, panel B).

The woman was admitted to the ICU, where a pneumological consultation was required and a bronchoscopy was performed. The main, lobar, and segmental bronchial hemi systems were described as free and uninjured. The possible lesion of the mucosa at the level of the tracheal wall hypothesized on the CT was not confirmed. After

consulting with an infectious disease specialist, antibiotic therapy was started with Cefepime 2g three times per day. The first ABG analysis showed  $p/f > 400$ , pH 7.38,  $pCO_2$  26,  $pO_2$  148, and  $HCO_3^-$  15.9. The patient reported a feeling of chest heaviness, and oxygen therapy (nasal prongs, 3 l/min) was initiated. The next day, a chest x-ray revealed moderate resorption of subcutaneous emphysema in the supraclavicular site on the right, supra and sub clavicular on the left, and a reduction of the bilateral pneumothorax flap (maximum thickness 3 mm). A thin hyper diaphanous streak along the mediastinal profile, particularly on the left, was noted, which was compatible with pneumomediastinum.

After two days in the ICU, the feeling of chest heaviness disappeared, and the rhinolalia reduced. The patient was transferred back to the Obstetrics department, where the oxygen therapy was stopped, and the antibiotic therapy was completed. The last X-ray, performed six days after the event, revealed no signs of pneumothorax or subcutaneous emphysema, and the patient was asymptomatic and eupnoeic.

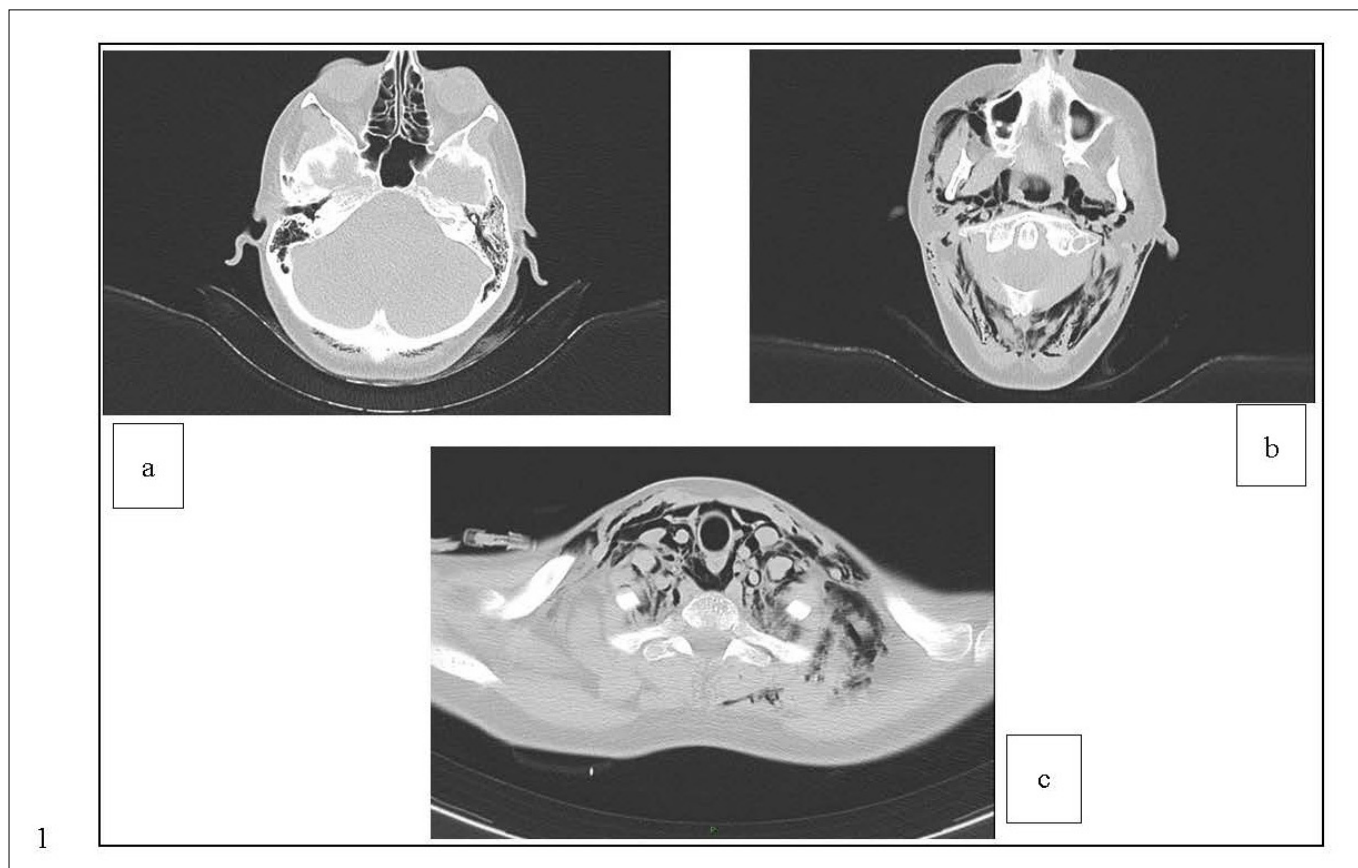
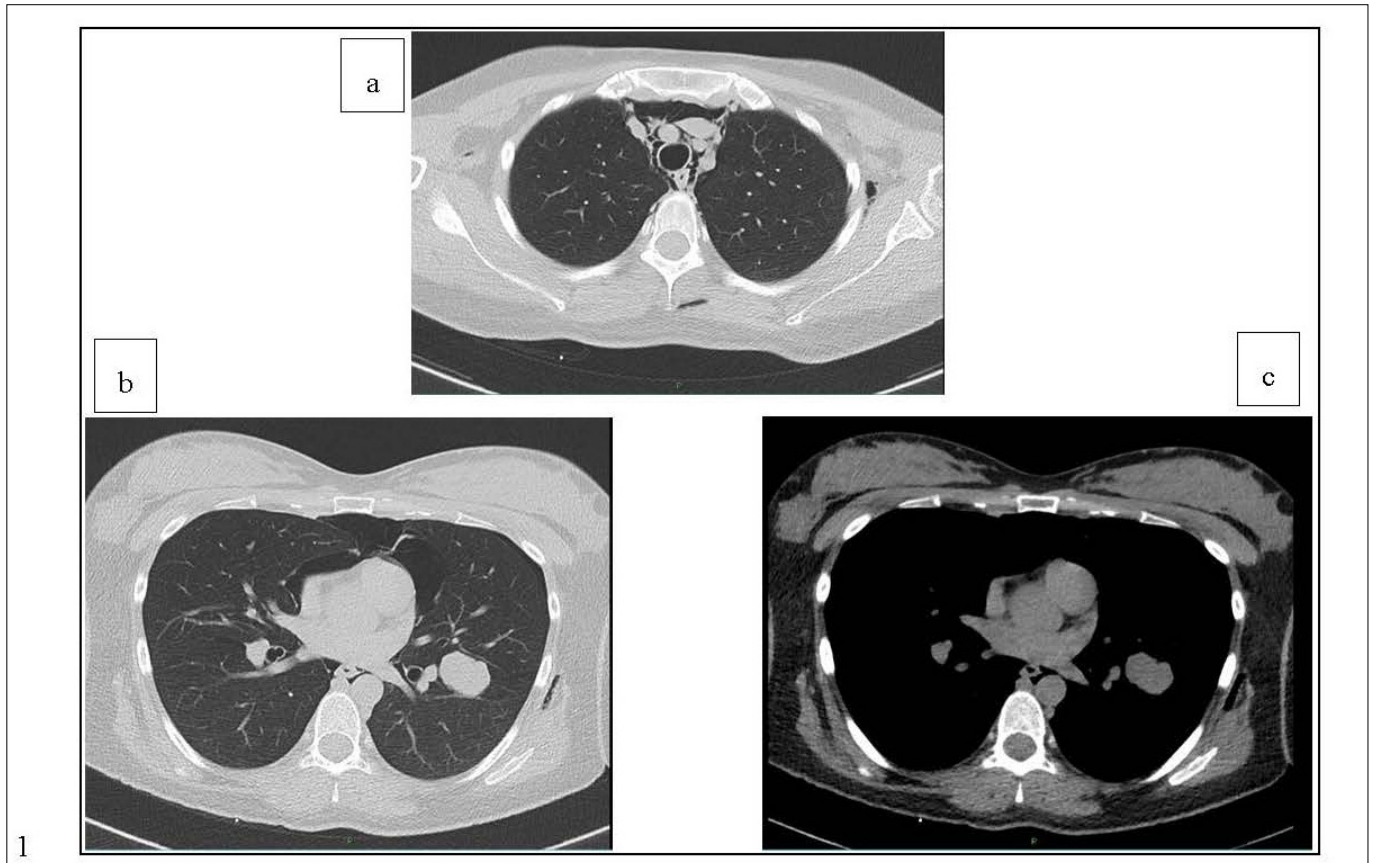
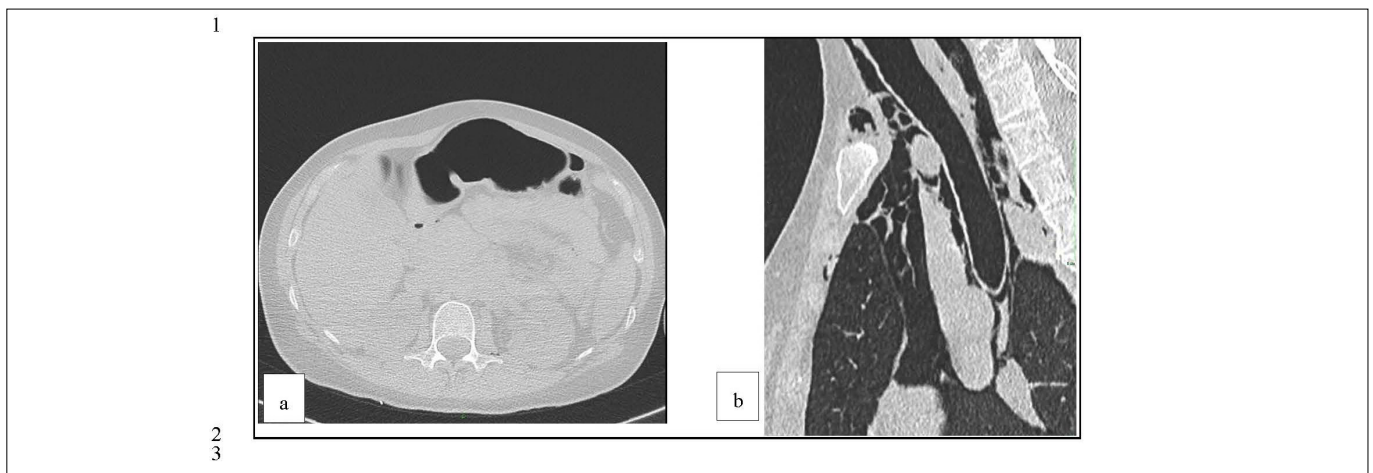


Figure 1. CT scan revealing extensive subcutaneous emphysema dissecting into deeper soft tissue and musculature, extending from chest wall to mediastinum and neck spaces bilaterally.



**Figure 2.** CT scan revealing pneumopericardium (b, c), pneumomediastinum, bilateral pneumothorax (a, b, c) and a fluid-filled cystic lesion in the left lung (b, c).



**Figure 3.** CT scan revealing minimal retroperitoneal bubbles in the upper tract of the ilio-psoas muscles bilaterally (a) and an apparent, millimetric continuous solution of the tracheal wall (b).

The woman was discharged to her home six days after delivery. At the time of discharge the woman was satisfied with the medical management; during his hospitalization his clinical conditions were always reassuring. The woman also declared that she wanted to investigate the possible aetiology of cystic formation in the lung. In agreement with the pulmonologist, she was recommended to perform a PET-CT to investigate the characteristics of the

oval formation in the left lung described in the angio-CT. The result of the PET-CT was negative. The patient underwent a CT scan with a contrast medium at the end of March 2023. CT shows complete resolution of the radiological picture (**Figure 4**, panels A, B and C) except for the stability of the lung lesion in size, morphological presentation and density, in absence of aggressive features even though it is not typed (**Figure 5**, panels A and B).

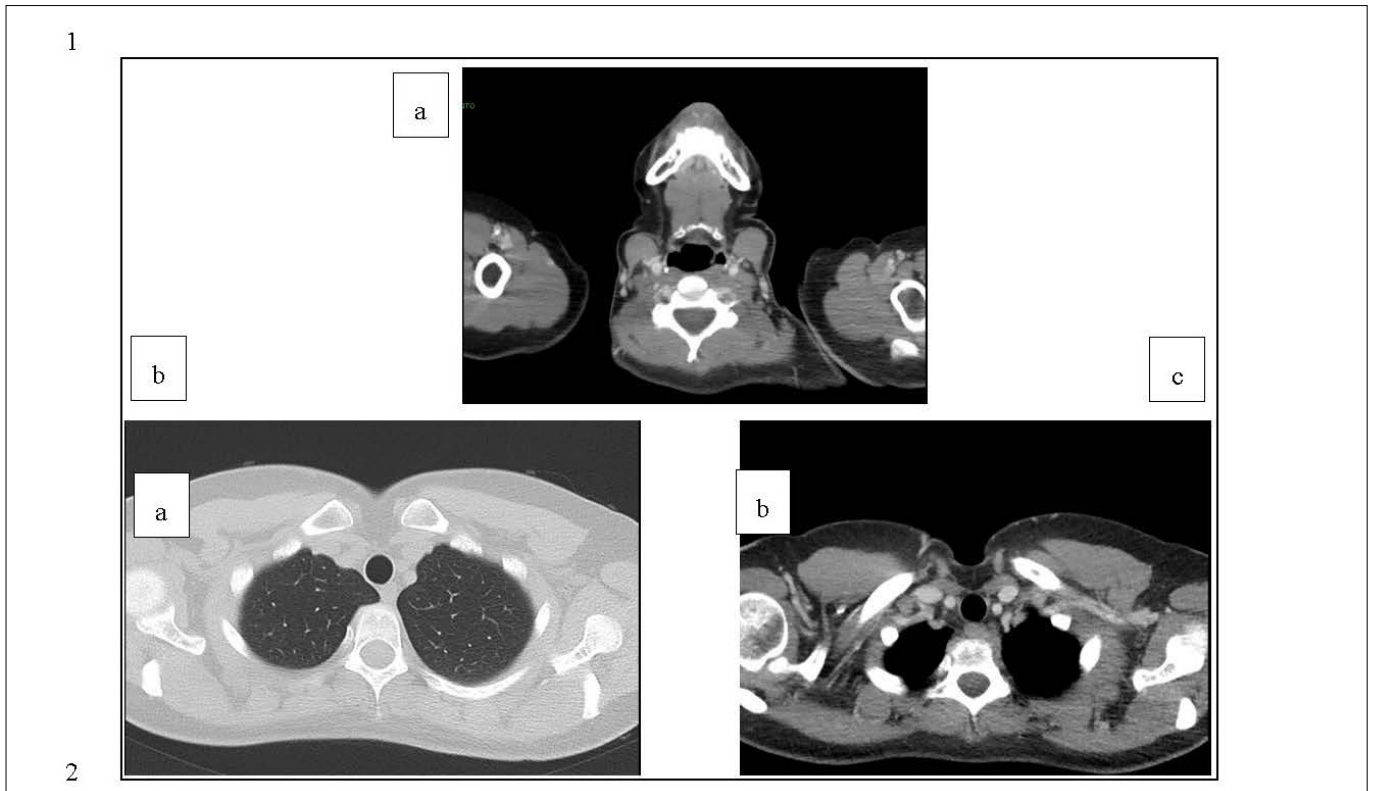


Figure 4. CT scan revealing the disappearance of free air at the cervical and thoracic levels.

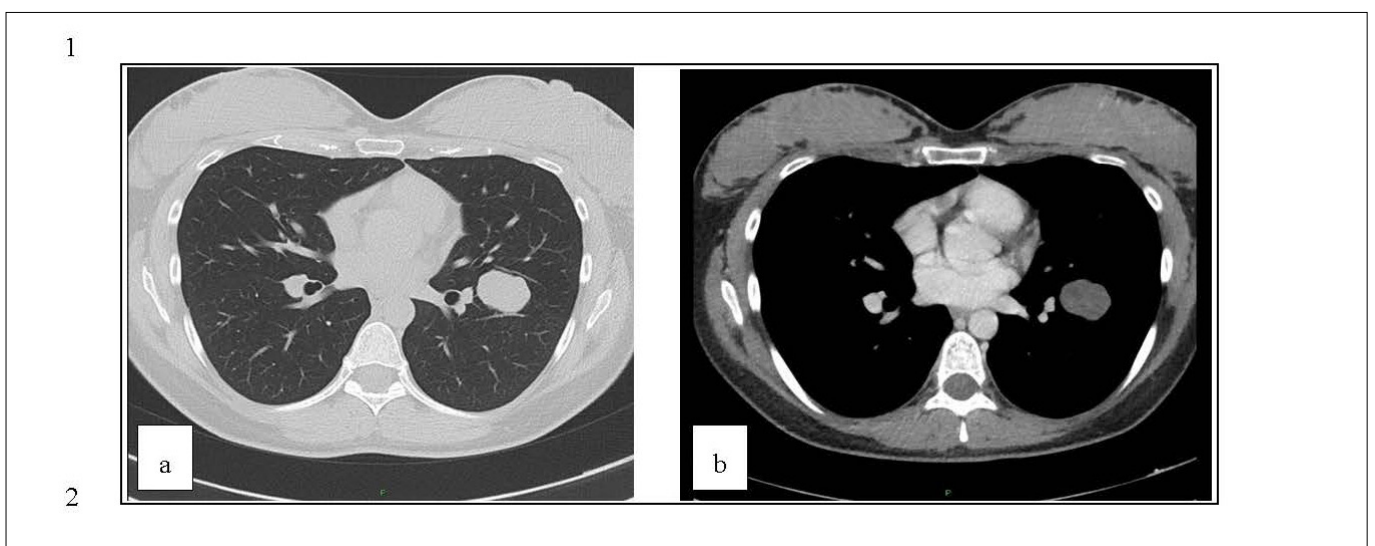


Figure 5. CT scan revealing the stability of the left lung lesion in size, morphological presentation and density 6 months after the delivery.

## DISCUSSION

We compared the characteristics of our clinical case with those that have emerged from the cases described in literature and a systematic review of the cases [3, 5, 9].

Regarding the demographic data of the mother, the woman in our clinical case is 27 years old, which is consistent with the age of  $24 \pm 5.4$  years

where this condition is most frequently observed. The complication occurred during the woman's second pregnancy, while in the literature, 61% of cases are described in primigravida. However, it should be noted that this is the patient's first vaginal delivery, as the previous delivery was done via the caesarean section. In our case, the duration of labour was 4.9 hours, while the literature reports an average duration of  $7.47 \pm 2.4$  hours. Therefore,

this is a finding that is in line with what has already been described.

In our case, the diagnosis was made in the fourth stage of labour, after delivery. In 55% of cases, complication occurs in the second stage, while in 16.25% of cases, it occurs in the fourth stage. In this regard, it should be specified that since the woman was asymptomatic, it is not possible to exclude that the condition occurred in the second stage, and the diagnosis was only made after delivery. In some cases, described in literature, the diagnosis of subcutaneous emphysema occurred during the second stage of labour, which led to an emergency C-section [9].

The clinical presentation was characterized by swelling and subcutaneous emphysema, chest pain, crepitus, and dysphonia, as described in 91.4%, 51.4%, 32.9%, and 14.3% of cases, respectively. However, the woman did not show other symptoms such as dyspnoea, which was described in 50% of cases published in the literature. Similarly, the woman did not show less frequently described symptoms such as tachycardia, vomiting, cough, or odynophagia.

Interventions were based on oxygen therapy and the administration of analgesics, as in 35.7% and 27.1% of cases described in literature, as well as the administration of conservative or symptomatic treatments. Antibiotics (Cefepime) were used as in 14.3% of cases already described. Invasive therapeutic procedures were not necessary.

Although in 70% of cases published pneumomediastinum is not associated with complications, in our case, it was associated with pneumothorax, as described in 16.7% of patients, and pneumopericardium, as described in 5% of patients. The described presence of bubbles in the retroperitoneal space has never been reported in literature. Pharyngeal rupture was described in 1.7% of cases published in the literature. In this case, although it was initially considered, the hypothesis was ruled out with diagnostic tests.

In our case, we also cannot exclude that the oval formation described in the context of the patient's lung may have contributed to the pathogenesis of the condition, which has not yet been definitively characterized. The lesion has a benign appearance, and we hypothesized it could be a congenital lesion.

### **Clinical management**

Hamman's syndrome is usually benign and resolves on its own within a few days. There is no consensus in the literature regarding the management of cases of Hamman-Macklin syndrome during labour [10, 11].

In this article we aim to suggest management based on symptoms and clinical conditions.

### **Diagnostic phase**

In patients in whom pneumomediastinum and/or spontaneous pneumothorax with subcutaneous emphysema are suspected (presence of cough, pain or discomfort, cyanosis or bluish discoloration, dyspnoea, rhinolalia, localized swelling), especially in the presence of a prolonged second stage of delivery, we suggest immediately initiating the monitoring of vital signs and to immediately require an intensive care consultation.

Contemporarily, we suggest careful and immediate physical examination in the delivery room for the evaluation of the clinical signs of emphysema and/or pneumothorax (palpable crepitus, use of accessory muscles, tachypnoea, decreased or absent breath sounds) and we suggest the immediate execution of an X-ray (preferably in the delivery room) and the urgent request for a CT scan.

### **Investigation phase**

If the diagnosis of emphysema, pneumomediastinum and/or pneumothorax or presence of free air in other compartments is confirmed the first step is to rule out the presence of organic lesions that may have caused pathological condition.

We deem it useful to perform a blood gas analysis for the evaluation of pulmonary exchanges. We suggest performing a laryngoscopy and a bronchoscopy especially in the case of patients at higher risk of tracheal/bronchial lesion (congenital abnormalities, long-term use of corticosteroids, chronic obstructive pulmonary disease, previous surgical procedures). We suggest performing the invasive procedures possibly in the ICU setting. In the case of a lesion, it is necessary to pay more attention to the methods of ventilation, if needed.

### **Therapeutic phase**

In the event of an organic lesion causing the presence of free air, treatment will be continued in the most appropriate setting based on the required level of care and the involvement of the necessary specialists.

After ruling out any serious underlying causes, the treatment is typically conservative, focusing mainly on reassuring the patient, along with the use of anti-anxiety medications, oxygen, and analgesics. Administering pure oxygen is particularly effective, as it facilitates the rapid absorption of free air [2,

5, 8, 10]. Any oxygen therapy should be based on the results of the blood gas analysis. The possible need for intubation must be carefully evaluated by the emergency specialist especially in relation to the possible lesion of the upper respiratory tract, as previously described. In extremely rare cases, compression of the great vessels may occur, necessitating a thoracotomy. For extensive subcutaneous emphysema, a small incision can be performed to insert a subcutaneous drainage tube or, if required, a chest tube [10, 12].

As suggested by some authors [10, 12], we believe it is useful to start a prophylactic antibiotic therapy to prevent possible infection especially in case of suspicion of mediastinitis even in consideration of the invasive diagnostic procedures and the setting. We suggest close monitoring of vital signs, possibly in the ICU in case of clinical instability, symptoms, or if deemed necessary by the emergency physician. Once the symptoms have resolved, transfer to the Obstetric area is possible.

#### *Follow up phase*

As a follow up to document clinical improvement we believe it is useful to perform a chest X-ray on the third, fifth and seventh day to evaluate the reabsorption of free air, in case the clinical condition does not fully resolve within a shorter time frame. The follow-up phase can be performed in the obstetrics department.

The suggested management approach is summarized in **Figure 1**.

#### *Obstetrical management*

Even the best management of subsequent deliveries is controversial [10].

Older publications favoured instrumental delivery to prevent an increase in mediastinal pressure or the development of massive subcutaneous emphysema. More recent opinions, however, support expectant management. These authors have suggested scheduling the delivery at 37 weeks or earlier in the case of a large foetus and implementing active management of the second stage of labour (operative delivery or caesarean section) only if labour is prolonged [10, 11].

## CONCLUSIONS

Hamman-Macklin syndrome is a rare condition that may be associated with labour and conditions

related to it, such as increased interalveolar pressure due to the Valsalva manoeuvre that patients perform in the second stage. Although the pathogenesis is not completely clear, we believe that studies should be carried out to characterize it more specifically by searching for any risk or predictive factors, since in some cases this condition can present severe clinical symptoms, and it could be useful to be able to identify at-risk patients.

We believe that, although it is a relatively uncommon condition, it is important to manage patients affected by this syndrome in a standardized manner and to quickly recognize its signs and symptoms. Although Hamman's syndrome is commonly referred to as the occurrence of spontaneous pneumomediastinum, in some cases, such as the one we described, this condition has been associated with pneumothorax, pneumopericardium, and the presence of free air in the retroperitoneal space. Despite the clinical presentation usually being free of complications, it is essential to increase awareness and diagnostic readiness for this condition.

It is desirable that the case reports be reported clearly and uniformly so that studies can be conducted with the aim of defining a standardized clinical approach to reach a consensus on the treatment of this pathology.

In this article we have proposed a management of Macklin-Hamman syndrome, further studies would be needed to confirm or refute our proposals.

## COMPLIANCE WITH ETHICAL STANDARDS

#### *Authors' contribution*

A.Ma., G.D., B.M.: Conceptualization. A.Ma., G.D., A.Me., A.L., C.G.: Methodology, investigation, data curation. A.Ma., A.Me., A.L., C.V., C.G., A.C.: Writing - original draft. S.D., L.L., V.R., B.M.: Writing - review & editing. S.D., V.R., B.M.: Supervision.

#### *Funding*

None.

#### *Study registration*

N/A.

#### *Disclosure of interests*

The authors declare that they have no conflict of interests.

**Ethical approval**

Ethical approval was not required for this study according to the institutional policy as the research involved anonymized data.

**Informed consent**

Written informed consent was obtained from the patient for the use of the clinical information, for the publication of this case report and any accompanying images.

**Data sharing**

Data are available under reasonable request to the corresponding author. Due to privacy and ethical restrictions, the full clinical dataset is not publicly available. However, anonymized data may be shared with qualified researchers upon justified request and with appropriate ethical approval. No new datasets were generated or analysed during the current study beyond those presented in the manuscript.

**REFERENCES**

1. Crean PA, Stronge JM, FitzGerald MX. Spontaneous pneumomediastinum in pregnancy. *Br J Obstet Gynaecol.* 1981;88(9):952-954. doi:10.1111/j.1471-0528.1981.tb02236.x.
2. Macklin CC. Transport of air along sheaths of pulmonic blood vessels from alveoli to mediastinum. *Arch Intern Med.* 1939;64(5):913-926. doi: 10.1001/archinte.1939.00190050019003.
3. La Verde M, Palmisano A, Iavarone I, Ronsini C, Labriola D, Cianci S, et al. A rare complication during vaginal delivery, Hamman's syndrome: a case report and systematic review of case reports. *Int J Environ Res Public Health.* 2022;19(8):4618. doi:10.3390/ijerph19084618.
4. Macia I, Moya J, Ramos R, Morera R, Escobar I, Saumench J, et al. Spontaneous pneumomediastinum: 41 cases. *Eur J Cardiothorac Surg.* 2007;31(6):1110-1114. doi: 10.1016/j.ejcts.2007.03.008.
5. Hülsemann P, Vollmann D, Kulenkampff D. Spontaneous pneumomediastinum-Hamman syndrome. *Dtsch Arztebl Int.* 2023;120(31-32):525. doi: 10.3238/arztebl.m2022.0394.
6. Riemma G, La Verde M, Schiattarella A, Cobellis L, De Franciscis P, Colacurci N, et al. Efficacy of hyoscine butyl-bromide in shortening the active phase of labor: systematic review and meta-analysis of randomized trials. *Eur J Obstet Gynecol Reprod Biol.* 2020;252:218-224. doi: 10.1016/j.ejogrb.2020.06.042.
7. Gregersen TL, Ulrik CS. Safety of bronchodilators and corticosteroids for asthma during pregnancy: what we know and what we need to do better. *J Asthma Allergy.* 2013;6:117-125. doi: 10.2147/JAA.S52592.
8. Abolnik I, Lossos IS, Breuer R. Spontaneous pneumomediastinum: a report of 25 cases. *Chest.* 1991;100(1):93-95. doi: 10.1378/chest.100.1.93.
9. Gomes S, Mogne T, Carvalho A, Pereira B, Ramos A. Post-partum Hamman's syndrome. *Cureus.* 2022;14(12):e33144. doi: 10.7759/cureus.33144.
10. Ait Amara Inesse A, Ruggiano I, Olivier C. Protracted labor complicated by pneumomediastinum and subcutaneous emphysema: a rare case report and management considerations. *Am J Case Rep.* 2023;24:e940989. doi: 10.12659/AJCR.940989.
11. Oshovskyy V, Poliakov Y. A rare case of spontaneous pneumothorax, pneumomediastinum and subcutaneous emphysema in the II stage of labour. *Int J Surg Case Rep.* 2020;70:130-132. doi: 10.1016/j.ijscr.2020.04.011.
12. Grapatsas K, Tsilogianni Z, Leivaditis V, Kotoulas S, Kotoulas C, Koletsis E, et al. Hamman's syndrome (spontaneous pneumomediastinum presenting as subcutaneous emphysema): a rare case of the emergency department and review of the literature. *Respir Med Case Rep.* 2017;23:63-65. doi: 10.1016/j.rmcr.2017.12.004.
13. Libretti A, Nicosia A, Troia L, Remorgida V. What does the cardiocography say about SARS-CoV-2 infection? *Cardiotocograph monitoring during the pandemic era: a narrative short review.* *Ital J Gynaecol Obstet* 2024;36(2):138-145. doi: 10.36129/jog.2024.150.