



Italian Journal of Gynæcology & Obstetrics

September 2025 - Vol. 37 - N. 3 - Quarterly - ISSN 2385 – 0868

Incarceration of a broken tip of Karman cannula: hysteroscopic removal as gold standard

Stefania Carlucci¹, Andrea Masotina¹, Guglielmo Stabile^{2*}, Antongiulio Del Bianco¹, Tamara Stampalija^{3,4}, Stefano Bettocchi¹

¹Department of Clinical and Experimental Medicine, University of Foggia, Foggia, Italy.

²Department of Medical and Surgical Sciences, Institute of Obstetrics and Gynaecology, University of Foggia, Foggia, Italy.

³Department of Obstetrics and Gynecology, Unit of Fetal Medicine and Prenatal Diagnosis, Institute for Maternal and Child Health, Scientific Institute for Research, Hospitalization and Healthcare Burlo Garofolo, Trieste, Italy.

⁴Department of Medicine, Surgery and Health Sciences, University of Trieste, Trieste, Italy.

ARTICLE INFO

History

Received: 15 January 2025

Received in revised form: 25 February 2025

Accepted: 10 April 2025

Available online: 30 September 2025

DOI: 10.36129/jog.2025.223

Key words

Uterine foreign bodies; hysteroscopic removal; Karman cannula's tip; hysteroscopy.

*Corresponding author: Guglielmo Stabile, M.D., PhD. Department of Medical and Surgical Sciences, Institute of Obstetrics and Gynecology, University of Foggia, viale Luigi Pinto 11, 71100 Foggia, Italy.
Email: guglielmost@gmail.com,
ORCID: 0000-0001-9266-3896.

ABSTRACT

Background. Vacuum aspiration is the most common surgical procedure during the first trimester abortion and has the lowest overall complication rate of surgical abortion procedures. This procedure is safe when done by an experienced practitioner; the rate of major complications is less than 1%. The breakage of the cannula with the tip retained in the uterus is a rare complication and, due to the few cases described in literature, the real estimation of the prevalence is not possible.

Case presentation. We present a case of a retained Karman cannula's tip after a dilatation and curettage (D&C) procedure for abortion. The patient underwent a series of unsuccessful attempts to remove the foreign body through curettage ultrasound guide, hysteroscopically and finally performing a laparotomy without success. After that, the patient was referred to our University Unit where the foreign body was removed by an office hysteroscopy and discharged the same day of the procedure.

Conclusions. This case report is to remark that hysteroscopy represents the gold standard in removing uterine foreign bodies, but it requires considerable operative experience.

INTRODUCTION

Worldwide, almost one in three pregnancies is terminated by induced abortion [1]. In countries where termination is legal and data are available, most induced abortions are done by vacuum aspiration

in the first 12 weeks of pregnancy [2, 3] done using generally a flexible plastic cannula of the type that was designed and popularized by Karman in the early 1970s [4].

This procedure is safe for surgical abortion in the first trimester when done by an experienced practi-

tioner; the rate of major complications is less than 1% [5, 6].

The main complications are haemorrhage (0-2.4%), trauma to the cervix (0-1.0%), uterine trauma (0-0.4%), and infection (0.6-2.5%) [7]. The breakage of the cannula with the tip retained in the uterus was first described by Domadia in 1976 [8] but the real estimation of the prevalence it is not possible. Foreign bodies in the uterus include contraceptive devices, tubal ligation clips, intrauterine devices, surgical packing and non-absorbable sutures [1]. Uterine foreign bodies can be removed using a hysteroscope under direct vision and in 1978 was described the first case of broken cannula's tip removed hysteroscopically [9]. This procedure reduces the chances of injury to the surrounding structures and almost all uterine foreign bodies can be removed using a hysteroscope. We describe here a case of retained broken tip of the "Karman cannula" during a suction curettage and its hysteroscopic treatment after several unsuccessful attempts through different approaches.

CASE PRESENTATION

A 28-year-old patient was referred to our University Department of Gynecology from a local hospital for a foreign body retained in the uterus. The patient underwent in an outpatient setting a D&C for abortion and, during the procedure, the tip of Karman's cannula broke and got retained in the uterus. Then, the patient underwent a hysteroscopy to find and remove the foreign body, but without any success.

The patient was hospitalized to monitor clinical conditions. Transvaginal ultrasound was performed and showed the presence of free fluid in Douglas. Afterwards an urgent abdominal computed tomography (TC) with and without contrast was performed and confirmed free fluid in the abdomen and the presence of a uterine isthmus lesion. At this stage the patient underwent urgent laparotomy surgery to suture the lesion and to drain the free fluid in abdomen. After a few days of hospitalization and monitoring the clinical conditions, the patient was transferred and admitted to our University Department of Gynecology.

On admission, the pelvic examination revealed slight cervical motion tenderness and smelly greenish vaginal discharge, mixed with blood clots. Then we performed a transvaginal ultrasound to confirm

the retained foreign body, which persisted despite several medical therapeutic efforts. The pelvic ultrasound showed a hyperechoic area in the uterine isthmus, with a cone-shaped shadow in the uterine cavity, suggestive of the foreign body retained.

Thus, we performed an office hysteroscopy using the vaginoscopic approach without speculum and anaesthesia. The procedure was performed using the 4 mm continuous-flow operative office hysteroscope with a 2.9 mm rod lens (Bettocchi office hysteroscope size 4, Karl Storz, Tuttlingen, Germany). Distension of the uterine cavity was achieved at 45 mmHg by using normal saline solution and intrauterine pressure was automatically controlled by an electronic irrigation and suction device (Endomat, Karl Storz, Tuttlingen, Germany). The uterine cavity appeared irregular for the presence of blood clots. After prolonged washing and careful observation, we were able to identify on the left posterior-lateral wall the Karman's cannula tip of about 2.5 cm (**Figure 1**) and remove it entirely by grasping it with a tenaculum hysteroscopic forceps (**Figure 2**).

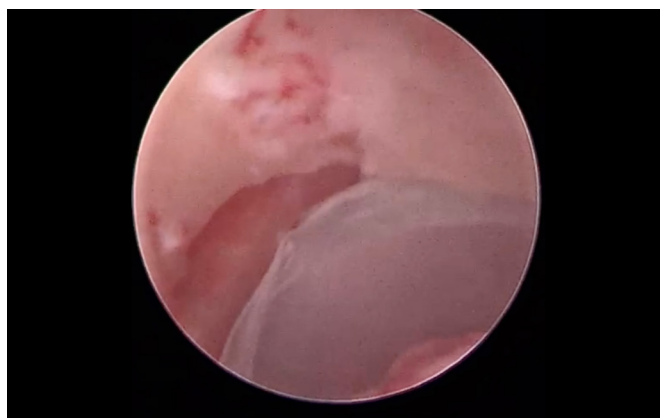


Figure 1. After entering the cavity, the tip of the broken cannula is found incarcerated in the posterior lateral wall (arrows).

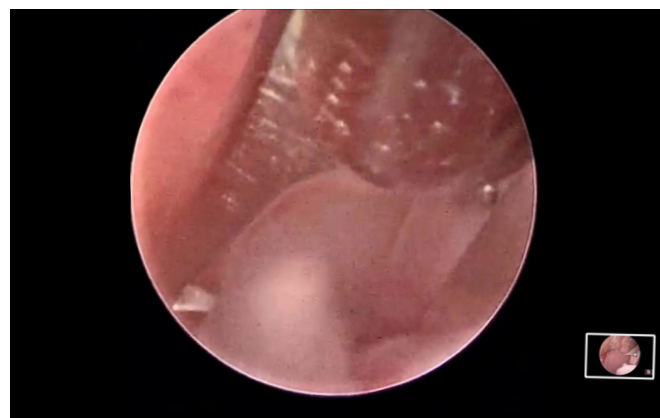


Figure 2. The tip of the Karman cannula is removed entirely by grasping it with the tenaculum hysteroscopic forceps and extracted from the uterine cavity.

Then, we performed, under general anaesthesia, using the 5 mm mini-resectoscope with a 90-degree loop electrode (Karl Storz, Tuttlingen, Germany) an operative procedure. Distension of the uterine cavity was achieved at 45 mmHg by using normal saline solution and intrauterine pressure was automatically controlled by an electronic irrigation and suction device (Endomat, Karl Storz, Tuttlingen, Germany). We removed purulent material mixed with blood clots present in the uterine cavity and performed endometrial ablation. During the procedure, we identified a small medial structure, probably a partial uterine septum. There were no visible breaks in continuity on the cavity walls. Due to the recent history of the patient and all the procedures she underwent, in absence of other complications, we decided to study the patient likable uterine anomaly with TVS 3D ultrasound and hysteroscopy after the restart of the normal menstrual cycle. The patient was discharged the same day of the procedure with antibiotic therapy for the following 7 days.

DISCUSSION

This case highlights the challenges of managing a retained foreign body in the uterus, a rare but potentially serious complication of uterine evacuation procedures. Despite multiple failed attempts with different approaches – including ultrasound-guided curettage, hysteroscopy, and laparotomy – the foreign body remained *in situ*, leading to an extended diagnostic and therapeutic course. Ultimately, successful removal was achieved through office hysteroscopy, reaffirming its role as the gold standard for managing intrauterine foreign bodies. This case underscores the importance of timely recognition, appropriate management, and operator expertise in ensuring patient safety and preserving fertility. The following discussion will contextualize this case within the existing literature, explore challenges in diagnosing and managing retained foreign bodies, and highlight key clinical takeaways to optimize patient outcomes.

Comparison with existing literature

To date, only five cases of retained Karman cannula tip removal via hysteroscopy have been reported in the literature [9-12]. Each case provides valuable insights into the diagnosis, management, and outco-

mes of this rare complication. Below, we compare our case with previous reports to highlight similarities, differences, and key clinical takeaways.

Diagnosis and initial management

The diagnosis of a retained Karman cannula tip remains challenging due to its rarity and the absence of standardized imaging techniques for immediate identification. Furthermore, the diagnosis could be very difficult in case of cannula fragments trapped in the myometrium without complete perforation of the uterine wall. In these cases, the laparoscopic or laparotomic diagnosis and resolution is impossible and the ultrasound diagnosis turns out to be difficult. McElin and Giese [9] were the first to report a case of intrauterine loss of a curette tip during a vacuum aspiration procedure. Their case was successfully managed with hysteroscopy, emphasizing its utility in retrieving intrauterine foreign bodies under direct visualization. In the case reported by Kumar and Kumar [10], as well as in our case, the diagnosis was not immediate, leading to multiple failed blind retrieval attempts before hysteroscopy was performed. Jain *et al.* [11] described a case where the retained cannula tip was identified through ultrasound before hysteroscopic removal, whereas Yazicioglu *et al.* [12] reported a more complex scenario where the foreign body had migrated beyond the uterus, necessitating an advanced endoscopic approach. In our case, despite early suspicion and imaging confirmation, initial management with ultrasound-guided curettage, hysteroscopy, and even laparotomy failed to retrieve the foreign body. This further emphasizes that an initial blind approach may be ineffective and potentially harmful, reinforcing the importance of direct hysteroscopic visualization.

Hysteroscopic retrieval and operator expertise

All previous reports highlight hysteroscopy as the gold standard for the removal of intrauterine foreign bodies. However, the success of hysteroscopic retrieval is highly dependent on operator expertise and appropriate instrumentation.

In McElin and Giese's [9] and Kumar and Kumar's [10] cases, the foreign body was successfully removed in a single hysteroscopic attempt. Similarly, Jain *et al.* [11] performed a successful retrieval without complications. However, in Yazicioglu *et al.*'s [12] case, the foreign body's unusual location complicated the procedure,

requiring advanced hysteroscopic techniques. In our case, despite prior hysteroscopic attempts at a different centre, the foreign body remained undetected and retained, suggesting that suboptimal visualization or inadequate instrumentation may have contributed to failure. When the patient was referred to our centre, successful removal was achieved through an office hysteroscopy, demonstrating the advantages of an experienced operator using a minimally invasive approach. In our centre there are 3 expert operators (like the one who performed the procedure), who perform approximately 10 hysteroscopies/week, both in office and operational.

Unlike previous reports where hysteroscopy was performed under general anaesthesia, our case underscores the feasibility of an office-based procedure, which reduced the need for hospitalization and anaesthesia-related risks.

Complications and patient outcomes

The potential complications of retained intrauterine foreign bodies include infection, uterine perforation, and intra-abdominal migration. Jain *et al.* [11] reported an uncomplicated retrieval, while McElin and Giese [9] also documented a successful case without sequelae. However, Kumar and Kumar [10] noted a case where hysteroscopic removal was delayed due to an initial misdiagnosis, emphasizing the risk of prolonged retention. Our case was particularly challenging due to secondary complications, including the presence of free fluid in the Douglas pouch and signs of infection (smelly greenish vaginal discharge, blood clots, and tenderness upon cervical examination). The patient underwent unnecessary laparotomy, which could have been avoided if hysteroscopy had been promptly and effectively utilized from the beginning. This aligns with Yazicioglu *et al.*'s [12] findings, where inadequate initial management contributed to an extended diagnostic and therapeutic course.

Ensuring safer procedures

Given the challenges associated with retained intrauterine foreign bodies, particularly in procedures like vacuum aspiration, implementing structured training programs and safety protocols is crucial to minimizing risks and ensuring effective management.

Hysteroscopy is a skill-dependent procedure requiring both theoretical knowledge and hands-on expertise.

While guidelines and existing literature do not specify an exact number of procedures required for competency, surely adequate and increased training is correlated with improved performance [13-15].

Furthermore, our case highlights the need of standardized procedural protocols. Implementing checklists and standardized protocols can significantly reduce the likelihood of intrauterine foreign body retention. Instrument count verification, similar to surgical instrument counting in laparotomies [16], should be mandatory also in case of minor surgical procedure, making use of pre- and post-procedure checklist ensuring that all instruments (including cannulae and curettes) are intact before and after the procedure.

Some potential solutions could be the use of radiopaque tip of the Karman cannulae or new technologies such as radiofrequency identification using tiny microchips embedded in surgical items [16]. In cases where retrieval difficulties are encountered, routine post-procedural ultrasound, using also 3-dimensional ultrasound, should immediately be performed to rule out retained fragments before discharging the patient [17].

Finally, ensuring safety can't help but implement ongoing quality improvement and reporting systems. Hospitals should conduct regular case audits and morbidity and mortality (M&M) meetings to review cases of retained intrauterine foreign bodies and identify areas for improvement [18]. Moreover establishing a complication registry for hysteroscopic procedures can help track outcomes and refine training strategies.

Clinical takeaways

Early diagnosis is crucial: our case and prior reports demonstrate that prompt recognition of a retained cannula tip is essential to avoid unnecessary interventions. The use of radiopaque suction cannulae could facilitate immediate detection via imaging. Hysteroscopy as the first-line approach: this case, along with those reported [9-11] and the existing literature [19-21] supports hysteroscopy as the gold standard for removal, reducing the risk of blind curettage or laparotomy.

Operator expertise matters: failed hysteroscopic attempts in our case suggest that hysteroscopy should only be performed by skilled practitioners with access to appropriate instrumentation.

Office *vs* operative hysteroscopy: unlike previous cases that required operative hysteroscopy under general anaesthesia, our successful removal in an

office setting demonstrates that office hysteroscopy can be a viable alternative, minimizing patient morbidity and healthcare costs [22, 23].

Safety: ensuring safer hysteroscopic procedures requires a combination of structured training, standardized protocols, and ongoing quality assessment.

CONCLUSIONS

Our case further reinforces that hysteroscopy is the gold-standard for removing intrauterine foreign bodies. However, early recognition, operator expertise, and appropriate instrumentation are key determinants of success. Furthermore, a more standardized approach, which includes operator training, competency and protocol improvements, such as routine inspections of surgical instruments post-procedure, is crucial to ensure safer procedures. Additionally, the potential use of radiopaque materials and real-time ultrasound assessment may help prevent and facilitate the management of such rare complications in the future.

COMPLIANCE WITH ETHICAL STANDARDS

Authors' contribution

S.C., S.B.: Conceptualization. A.M.: Methodology, software. G.S.: Investigation, resources, writing – review & editing. A.D.: Data curation, visualization. S.C.: Writing – original draft. T.S.: Writing – review & editing, visualization. S.B.: Supervision.

Funding

None.

Study registration

N/A.

Disclosures of interests

The authors declare that they have no conflict of interests.

Ethical approval

The study was conducted according to the guidelines of the Declaration of Helsinki.

Informed consent

Written informed consent with guarantees of confidentiality was obtained from the subject involved

in the study, and the principles of the Helsinki Declaration were followed.

Data sharing

Data are available along with the article.

REFERENCES

1. Sedgh G, Henshaw S, Singh S, Ahman E, Shah IH. Induced abortion: estimated rates and trends worldwide. *Lancet*. 2007;370(9595):1338-45. doi: 10.1016/S0140-6736(07)61575-X.
2. Medical methods for termination of pregnancy. Report of a WHO Scientific Group. *World Health Organ Tech Rep Ser*. 1997;871:i-vii, 1-110.
3. Pazol K, Gamble SB, Parker WY, Cook DA, Zane SB, Hamdan S; Centers for Disease Control and Prevention (CDC). Abortion surveillance - United States, 2006. *MMWR Surveill Summ*. 2009;58(8):1-35.
4. Karman H, Potts M. Very early abortion using syringe as vacuum source. *Lancet*. 1972;1(7759):1051-2. doi: 10.1016/s0140-6736(72)91225-1.
5. Safe Abortion: Technical and Policy Guidance for Health Systems. 2nd ed. Geneva: World Health Organization; 2012.
6. Bartlett LA, Berg CJ, Shulman HB, Zane SB, Green CA, Whitehead S, et al. Risk factors for legal induced abortion-related mortality in the United States. *Obstet Gynecol*. 2004;103(4):729-37. doi: 10.1097/01.AOG.0000116260.81570.60.
7. Munoz E, Robbins H. First-trimester bleeding: assessment, diagnosis, and management by the primary care nurse practitioner. In: Geri C Reeves, *Advances in Family Practice Nursing - Volume 1*. 2019. Elsevier, Nashville, 117-29.
8. Domadia MM, Thakker KD. Hazards of first trimester termination. *J Obstet Gynaecol India*. 1976; 916-921
9. McElin TW, Giese TM. Complication of abortion performed with plastic suction curet: intrauterine loss of the curet tip. *Am J Obstet Gynecol*. 1978;132(3):343-4. doi: 10.1016/0002-9378(78)90909-2.
10. Kumar A, Kumar A. Broken tip of Karman cannula removed at hysteroscopy. *J Minim Invasive Gynecol*. 2015;22(4):700-1. doi: 10.1016/j.jmig.2015.02.004.
11. Jain N, Sharma S, Kriplani I, Kriplani A. A Foreign Body (Broken Karman's Cannula Tip No. 8) in Uterus: Nightmare for an Obstetrician.

- J Obstet Gynaecol India. 2024;74(1):94-5. doi: 10.1007/s13224-023-01908-y.
12. Yazicioglu HF, Yasar L, Dülger O. Hysteroscopic removal of a foreign body from the subvesical space. *Int J Gynaecol Obstet.* 2004;86(1):48-9. doi: 10.1016/j.ijgo.2004.04.031.
 13. Savran MM, Sørensen SM, Konge L, Tolsgaard MG, Bjerrum F. Training and Assessment of Hysteroscopic Skills: A Systematic Review. *J Surg Educ.* 2016;73(5):906-18. doi: 10.1016/j.j Surg.2016.04.006.
 14. Issat T, Beta J, Januszewski M, Jakimiuk AJ. Cumulative summation test for learning curve (LC-CU-SUM) in outpatient hysteroscopy. *Ginekol Pol.* 2017;88(1):9-12. doi: 10.5603/GPa.2017.0002.
 15. Vitale SG, Caruso S, Vitagliano A, Vilos G, Di Gregorio LM, Zizolfi B, et al. The value of virtual reality simulators in hysteroscopy and training capacity: a systematic review. *Minim Invasive Ther Allied Technol.* 2020;29(4):185-93. doi: 10.1080/13645706.2019.1625404.
 16. Cobb TG. Iatrogenic retention of surgical objects: risk factors and prevention strategies. *JAAPA.* 2010;23(12):33-4, 39-40. doi: 10.1097/01720610-201012000-00008.
 17. Levine EM, Fernandez CM, Miller D, Locher S. Clinical Value of 3-Dimensional Ultrasound in Gynecology. *J Ultrasound Med.* 2018;37(10):2445-50. doi: 10.1002/jum.14587.
 18. Bal G, David S, Sellier E, François P. Intérêt des revues de mortalité et de morbidité pour la formation des médecins et l'amélioration de la qualité et de la sécurité des soins : revue de la littérature [Value of morbidity and mortality review conferences for physician education and improvement of care quality and safety: a literature review]. *Presse Med.* 2010;39(2):161-8. French. doi: 10.1016/j.lpm.2009.11.005.
 19. Stabile G, Godina C, Cracco F, Mangino FP, Canton M, Romano F, et al. Hysteroscopic removal of intrauterine device in early pregnancy. *BMC Womens Health.* 2022;22(1):425. doi: 10.1186/s12905-022-02012-5.
 20. Stabile G, Cracco F, Nappi L, Sorrentino F, Vitale SG, Angioni S, et al. Hysteroscopic Removal of Intrauterine Device in Pregnancy: A Scoping Review to Guide Personalized Care. *Medicina (Kaunas).* 2022;58(11):1688. doi: 10.3390/medicina58111688.
 21. Sonnenfeld MM, Moscovitz T, Kesselring RFS, Fernandes CE, Tcherniakovsky M. Analysis of the routine of medical specialists in hysteroscopies. *Ital J Gynaecol Obstet.* 2025;37(1):105-15. doi: 10.36129/jog.2024.188.
 22. Bettocchi S, Nappi L, Ceci O, Selvaggi L. Office hysteroscopy. *Obstet Gynecol Clin North Am.* 2004;31(3):641-54, xi. doi: 10.1016/j.ogc.2004.05.007.
 23. Crescini C. Spontaneous intrauterine fragmentation of intrauterine device (IUD Novaplast T 380 Ag Normal): uncommon reported case. *Ital J Gynaecol Obstet.* 2025;37(2):119-21. doi: 10.36129/jog.2024.184.