

Letter of explanation

Dear editorial office members,

I am Sally ELTawab, author of the article:

" Performance of the IQTA ADNEX model in preoperative assessment of suspicious adnexal masses with high-risk of malignancy index in Alexandria University Gynecology Oncology Center: A prospective study " Of which you accepted the publication.

On behalf of my co-authors, I would like to thank you very much for that. *As the lead on this project, I submitted the manuscript honestly and without questioning the underlying data. However, I have since discovered some potential data-entry errors. As I can no longer personally vouch for the accuracy of the results contained. I wish to **withdraw** the paper from publication.*

We would be very grateful and we hope, as an academic researcher you understand our situation.


Best regards,

Sally ELTawab

Ayat S. Hamed

Tawfik A. S. Tawfik

Rehab E. S. Nour El Din

The image shows four handwritten signatures in blue ink, corresponding to the names listed on the left. The first signature is for Sally ELTawab, the second for Ayat S. Hamed, the third for Tawfik A. S. Tawfik, and the fourth for Rehab E. S. Nour El Din.

ORIGINAL ARTICLE

Performance of the IOTA ADNEX model in preoperative assessment of suspicious adnexal masses with high-risk of malignancy index in Alexandria University Gynecology Oncology Center: a prospective study

Performance of the IOTA-ADNEX model in an Egyptian setting

Sally S. **ELTawab**^{1,2,*}, Ayat S. **Hamed**¹, Tawfik A. S. **Tawfik**¹, Rehab E. S. **Nour El Din**¹

¹ ElShatby Maternity University Hospital, Gynaecology Oncology center, Faculty of Medicine, Alexandria University, Alexandria, Egypt.

² Oxford Gynaecological Cancer Centre, Churchill Hospital, Oxford University, Hospitals Foundation Trust, Oxford, United Kingdom.

Corresponding author: Sally **ELTawab**, MRCOG, MD. Churchill Hospital, Gynaecology Oncology Cancer Center, Old Road, Headington, Oxford, OX3 7LE

Email: Sally_eltawab@hotmail.com; Sally.eltawab@ouh.nhs.uk

Orcid: 0000-0002-9335-8890.

Doi: 10.36129/jog.2024.158

ABSTRACT

Objective. Despite the advanced surgical techniques in managing ovarian cancer, there is no improvement in its early detection. This study aims to evaluate the performance of the IOTA-ADNEX Model in adnexal masses with high-risk malignancy index in correlation with the gold standard histopathological diagnosis in Egyptian sitting.

Materials and Methods. A prospective study included 150 women with ultrasound diagnosis of unilateral or bilateral adnexal mass and had a high-risk malignancy index, for which surgery was planned. Ultrasound was performed using the IOTA-ADNEX model and a total score was given to each patient. All patients had surgical staging, and a definitive histopathological diagnosis was reached.

Results. Moderate agreement between the IOTA-ADNEX Model and the histopathological results where the Kappa coefficient = 0.487. The IOTA score cut-off value of 42 had a sensitivity of 83.6% and a specificity of 75%. The performance of the IOTA-ADNEX model showed excellent discrimination between benign ovarian and malignant ovarian stage II-IV and between borderline and stage II-IV with AUC 0.877 and 0.875, respectively. The performance was good effective in distinguishing between benign and malignant stage I with AUC 0.82 and less effective in distinguishing borderline and stage II-IV. However, it showed fair discrimination between benign and borderline and between stage I and stage II-IV with AUC 0.564 and 0.681, respectively.

Conclusions. The study found the IOTA ADNEX model had high sensitivity and specificity for detecting malignancy in suspicious adnexal masses with a high-risk malignancy index and showed moderate agreement with the histopathological assessment of adnexal masses.

Keywords

IOTA- ADNEX mode; RMI 2; pre-operative adnexal mass assessment; CA 125.

Introduction

Ovarian cancer remains a significant health concern, as early detection and screening programs have yet to be established. Unfortunately, most cases are not diagnosed until the disease is advanced, resulting in a poor overall prognosis [1]. Accurately characterizing newly diagnosed adnexal lesions and predicting possible malignant subtypes are crucial in defining appropriate treatment pathways and potentially improving survival rates [2].

The risk of malignancy index (RMI) is a scoring system used to characterize adnexal lesions and predict possible malignant subtypes accurately. In 1990, Jacobs et al. introduced the risk of malignancy index RMI I, which includes menopausal status, ultrasound findings, and serum CA-125 level [3,4]. Since then, modified versions of RMI, including RMI II, RMI III, and RMI IV, have been introduced [5,6,7]. However, RMI I is the most widely used and validated triaging system for adnexal masses [8]. The formula for RMI calculation is $RMI = M \times US \times \text{serum CA-125}$, where M refers to the patient's menopausal status, US refers to the ultrasound score, and serum CA-125 is the assayed level expressed in U/ml. Unfortunately, pre-operative differentiation between benign and malignant ovarian masses is challenging due to the relative insensitivity of radiological imaging and serum markers, particularly in the differentiation of stage I epithelial ovarian cancer. It is important to note that differentiating between benign and malignant ovarian masses cannot be achieved with a single ultrasound finding [9].

In addition to the widely used and validated RMI scoring system, the IOTA Group (International Ovarian Tumour Analysis Group) developed the ADNEX model in 2014 for a more detailed characterization of adnexal masses [10]. The model includes nine variables, including age, serum CA-125 level, type of center (oncology referral center vs non-oncology center), the maximum diameter of the lesion, the maximum diameter of the largest solid part of the lesion, more than ten cyst locules, number of papillary projections, presence or absence of acoustic shadows, and presence or absence of ascites. With all variables input, the ADNEX model provides results in graphic and numerical forms to present the likelihood of malignancy. This model uses five histopathology groups: benign, borderline tumors, stage I invasive, stage II-IV invasive ovarian cancer, and secondary metastatic cancer. The ADNEX model is available to the public on the IOTA website (<http://www.iotagroup.org/adnexmodel/>) [11].

Recently, the ESGO/ISUOG/IOTA/ESGE Consensus Statement on the pre-operative diagnosis of ovarian tumors, published in February 2021, states that treatment decision-making processes should be based on a combination of the patient's overall clinical picture. Symptoms, preferences, previous medical and surgical history, tumor markers, and clinical and radiological findings should also be included. A single diagnostic modality alone should not determine the patient's journey [12].

Our study aimed to evaluate the performance of the IOTA-ADNEX Model in the pre-operative assessment of adnexal masses with high-risk of malignancy index (using RMI 2) in ESGO- accredited ELShatby Gynecological Oncology center in Egypt in correlation with the gold standard histopathological diagnosis.

Methods

Study design, setting, and ethical considerations:

This prospective observational study was conducted at ELShatby Maternity Hospital in Gynaecology Oncology Center- an ESGO-accredited tertiary center for managing ovarian cancer and Ultrasound Unit in Alexandria, Egypt. This study followed the ethical standards of the responsible committee on human experimentation (institutional and national) and with the Helsinki Declaration of 1975, as revised in 2008. The Faculty of Medicine, Alexandria University's ethical committee approved the study protocol.

The study included 150 women of any age, with ultrasound diagnosis of unilateral or bilateral adnexal mass for which surgery was planned and had a high calculated risk malignancy index ovarian mass (according to RMI 2). The exclusion criteria were pregnancy at the time of diagnosis, any history of gynecology cancer or previous chemotherapy or radiotherapy, and any other gynecological surgical conditions, e.g., fibroids.

Patients and methodology:

Cases were recruited from outpatient Gyne-oncology clinics or cases referred to the Gyne-oncology center. Thorough history taking and a comprehensive, complete examination were done. A venous blood sample was obtained from the selected patients to evaluate the serum CA-125 using a solid-phase enzyme-linked immunosorbent assay (American Laboratory Products Company, Windham, NH, USA). The cut-off level of CA 125 has been set at 30 U/ml.

Transvaginal and transabdominal sonography was performed for all patients using a transvaginal probe (TVUS) 2.5 MHz and a transabdominal probe 5/6 MHz color, power, and pulsed Doppler capabilities. Voluson P8 (GE Health Care Women's Health Ultrasound) was the ultrasound machine used. The same expert gynecologist ultra-sonographer with more than 15 years of experience in gynecological ultrasound assessed the sonographic tumor morphology in all patients based on the nomenclature and methodology proposed by the IOTA Group [13] (IOTA-ADNEX model), and a total score based on the scoring system has been given to each patient. ADNEX estimates the probability that an adnexal tumor is benign, borderline, stage I, stage II-IV, or secondary metastatic cancer (i.e., metastasis of non-adnexal cancer to the ovary).

In this study, RMI 2 was used because it showed the highest accuracy or diagnostic performance. RMI 2 has a cut-off point of 90, an under-chart area of 86.7, 79.36% sensitivity, 78.95% specificity, 58.44% positive predictive value, 90.08% negative predictive value, and 78.93% accuracy, and a p-value of 0.004 [14]. The cut-off point 90 of RMI 2 is tighter than the standard 200 of RMI 1 to avoid missing any malignant case. However, in a minority of cases, it may overestimate benign masses being malignant (false positive). RMI 1 was also calculated for comparison.

All patients had surgical staging, and a definitive diagnosis was reached after a histopathological examination of the surgically removed adnexal mass. The histopathological diagnosis was used as the reference standard.

Statistical analysis of the data

Data were analyzed using a Statistical package (IBM, Armonk, NY, USA, SPSS version 23). Data were described using either number and percentage for qualitative (categorical) data or mean and standard deviation for quantitative normally distributed data. On the other hand, median and interquartile ranges were used to describe variables that were not normally distributed (Skewness coefficient $> \pm 1$).

Testing for agreement (interrater reliability) between histopathological and IOTA classification was conducted using Cohen's Kappa coefficient using the following cut-off values (0.21-0.4 as fair, 0.41 to 0.6 as moderate, 0.61 to 0.8 as substantial, more than 0.8 as perfect agreement)

Testing diagnostic accuracy for RMI 1, RMI 2, and IOTA-ADENX model against the gold standard (Histopathology) was done using the receiver operating characteristic curve (ROC curve) with the estimation of the most accurate cut-off value with its sensitivity, specificity, and area under the curve (AUC).

Results

Table (1): Histopathological findings in 150 women with adnexal mass

Table (2): Diagnostic accuracy of RMI 1 and RMI2 in predicting malignancy.

Table (3): Clinical characteristics and ultrasound findings in 150 women with an adnexal mass, according to tumor histopathology subclassification:

Table (4): IOTA-ADNEX Model classification versus histopathology.

The degree of agreement between IOTA-ADNEX Model classification and histopathology was estimated using the Kappa Coefficient. The result showed moderate agreement between the IOTA-ADNEX Model and the histopathological results where the Kappa coefficient = 0.487.

Table (5): The degree of agreement (inter-rater reliability) between IOTA-ADNEX Model classification and histopathology

To identify an optimal threshold for the IOTAADNEX model in predicting malignancy, ROC Curve analysis was performed for the IOTA score. (Figure 2).

The estimated IOTAADENEX has suggested the importance of the IOTA score in malignancy prediction as the IOTA score AUC value was high (AUC, 81%; 95% CI 70.1%-91.9%). The ROC curve of the IOTA score is shown in Figure 2.

The estimated IOTA score cut-off value that showed the maximum accuracy was 42.0 for the predicted probability of malignancy. The IOTA score cut-off value had a sensitivity of 83.6% and a specificity of 75%. This denotes that the IOTAADENEX model is a good negative test.

Table (6): Diagnostic accuracy of the IOTAADENEX model in predicting malignancy:

Table (7) shows the accuracy of the IOTAADENEX model in differentiating between benign tumors and each stage of malignant tumor as well as its accuracy in differentiating between malignant tumors of different stages.

Table (8): Pairwise AUC for the IOTA ADENEX model

Examples of the ADNEX model from our study:

Case 1: 52y, married G0P0, hypertensive, complaining of pelvic pain, and heaviness. CA125: 246 U/ml, RMI 1= 2214, RMI 2= 3936. US findings: Bilateral multilocular ovarian lesions with multiple septae, solid contents, right side 17x14cm, left side 14x15cm (with solid part 7cm), Color score2, abnormal intracavitary uterine, Polyp, and Ascites. IOTA's risk of malignancy: 49.9% (40.7% stage 11-1V). The patient had a staging laparotomy. Histopathology confirmed high-grade serous carcinoma of the ovary, uterus, and positive ascites (stage IIc).

Case 2: 53y, G4P4, complaining of pelvic pain, and heaviness. CA125: 38 U/ml, RMI 1=144, RMI 2= 152. US findings: right adnexal multilocular cyst (13x11cm) with thin septations, no solid part, avascular, no ascites. IOTA's risk of malignancy: Benign 80%. Staging laparotomy was done and histopathology confirmed right mucinous cystadenoma.

Case 3: 48y, G2P2, previous 1, previous splenectomy for hypersplenism complaining of abdominal distention. CA125: 57, RMI 1=171, RMI 2= 228, ultrasound findings: right large unilocular solid pelviabdominal mass 142x102mm, solid part 76 mm, Adenomyotic Uterus. IOTA's risk of malignancy: 74.5 % Malignant (31.5 % stage 1). A staging laparotomy was done, and histopathology confirmed Clear cell carcinoma of the right Ovary, tube, and omental deposits (stage III).

Discussion:

Commonly used IOTA simple rules are a simple and efficient tool, that can be used in discrete hospitals where experienced radiologists in gynecology are not available [15]. The rationale behind using the ADNEX model in cancer centers is that it could estimate the risks for a specific patient and allows better triaging and even prediction of possible histopathology groups. As a result, this improves management decisions and decreases the adnexal pathology's morbidity and mortality. Of the four groups of malignant tumors in the ADNEX model, secondary metastasis and borderline tumors are particularly interesting to identify preoperatively [16,17].

In the current study, it was found that the malignancy risk increased with age, where the highest mean age was among the borderline group (53.86 ± 13.73) while the lowest was among the benign group (47.85 ± 1.67), with 34.7% were premenopausal, while 65.3% were postmenopausal. This finding agrees with a study of 165 patients with suspected adnexal mass made by Rai et al. [18], finding that benign lesions were significantly more common in patients below the age of 50 years and malignant above 50 years.

In our study, the CA125 level ranges (9-4000) with a mean of 475 and a median of 117. In 122 cases (81.3%) showed elevated CA 125 levels. The CA 125 level was elevated in the benign, borderline, stage I, and tumor stage II-IV in percentages of 75% (most are mildly elevated), 57.1%, 83.3%, and 91.7%, respectively.

In our study, RMI I ranged between (25-3600), with a mean of 3590, while RMI II ranged between (25-64000) with a mean of 6161. With RMI I, a high tendency for malignancy was calculated in 66.7% of our cases, jumping to 88% when RMI II was used. Both indices were shown to have an acceptable association with malignancy prediction with an accuracy of 76.5 and 76.7, respectively. The estimated RMI 1 cut-off value was 217.5 for the predicted probability of malignancy, with a sensitivity of 74.5% and a specificity of 70.0%, with histopathological examination as a gold standard. The estimated RMI 2 cut-off value was

340 for the predicted probability of malignant status with a sensitivity of 72.0 % and a specificity of 70.0 % with histopathological examination as a gold standard.

Similarly, in a retrospective study including 155 patients diagnosed with adnexal masses, Hada et al. [19] revealed the usefulness of all malignancy risk indices, including RMI 1 and RMI 2, in differentiating benign/borderline adnexal masses from malignant ones, to determine the best therapy. The sensitivity, specificity, and AUC for overall tumors were 63, 93.8%, and 0.844 for RMI1, and 66.7, 89.1%, and 0.851 for RMI 2. In another study, Sumathi [20] found that RMI 2 has an advantage over RMI 1 in distinguishing between benign and malignant ovarian tumors. The cut-off value for differentiating between benign and malignant tumors was 200. The sensitivity and negative predictive value is 100% for RMI 1 and RMI 2. The specificity of RMI 2 and RMI 1 was 52.5% and 47.5%, respectively. The accuracy of RMI 1 and RMI 2 was 58% and 62%, respectively. Sumathi concluded that RMI 2 is a simple scoring system more reliable than RMI 1 in detecting malignant ovarian tumors.

In Our study, analysis of ultrasound features found that most benign tumors measured with a mean of 12 cm \pm 4.3 SD, malignant lesions diameter a mean of 16.9 cm \pm 13.1 SD. Previous studies stated that both mass size and the presence of solid components are associated with malignancy risk, while all masses less than 5 cm and larger masses with no solid areas are of low malignancy risk [21,22].

The pattern of papillary projections among our study groups (shown in tab 3) was like the pattern described by Moro et al. [23] In their study, only one benign tumor out of 57 had a single papillary projection. In their borderline group, 67% had a single papillary projection, 33% had > 3 projections, and all the malignant tumors had > 3 papillary projections. Carvalho et al. [24] reported that papillary projections during transvaginal ultrasound examination suggest malignancy. Khurana et al. [25] found that papillary projections as a predictor of malignancy had a very high sensitivity of 93.33 % but lower specificity of 54.29%.

This disagreed with Mascilini et al. [26], who found the occurrence of single papillary projection in the malignant group was 33%, being more than both the borderline (25%) and benign groups (24%). In comparison, they found papillary projections > 4 in 47%, 58%, and 33% of the benign, borderline, and malignant tumors, respectively.

In our study, IOTA adnexa agreed in the classification of tumors with the histopathological results in 70% of the begin tumors, 28.6% of the borderline tumors, 8.3% of tumors stage I, and 70.8% of the malignant tumors stages II-VI. The reliability of IOTA classes was estimated using the Kappa Coefficient. The result showed moderate agreement between the IOTA score and the histopathological results where the Kappa coefficient = 0.487, which means moderate agreement according to Cohen's suggestion of Kappa result interpretation [27]. In our study, the estimated IOTA score cut-off value was 42.0 for the predicted probability of malignancy with a sensitivity of 83.6% and a specificity of 75%.

In a similar study, Jeong et al. [28] validated the efficacy of the IOTA-ADNEX model in discriminating characteristics of adnexal masses. They reported that the IOTA-ADNEX model was highly influential in differentiating between benign and malignant ovarian tumors as the IOTA-ADNEX AUC value was high (AUC, 0.924; 95% CI 0.880-0.999). Besides, the optimal cut-off value of the IOTA-ADNEX model for excluding benign diseases was 47.3, with a specificity of 97.7%. Another similar study by Tug et al. [29] using the cut-off of 14 showed sensitivity and specificity of 88.5% and 84.6%, respectively (AUC 0.865 \pm 0.039).

They stated that the ADNEX model showed superior sensitivity and specificity compared to all four RMI models.

In our study, regarding the performance of the IOTA-ADNEX model in discriminating between benign and malignant masses and between different types of malignancies, it showed excellent discrimination between benign and malignant stage II-IV and between borderline and stage II-IV with AUC 0.877 and 0.875 respectively. The performance was good in distinguishing between benign and malignant stage I with AUC 0.82 and less effective in distinguishing borderline and stage II-IV. However, it showed fair discrimination between benign and borderline and between stage I and stage II-IV with AUC 0.564 and 0.681, respectively.

In a study conducted in a gynecological oncology center in China by Chen et al. [29] on 278 women with ovarian tumors, the IOTA-ADNEX model showed excellent performance, with a sensitivity of 93.3% (95% CI, 85.0–98.0%), a specificity of 77.8% (95% CI, 72.0–83.0%) and a diagnostic odds ratio of 46.8, which is a better performance than what we obtained in our study. Moreover, in their study, the performance of the IOTA ADNEX model was good for discriminating between benign and malignant tumors, with an AUC of 0.94 (95% CI, 0.91–0.97) when CA 125 was included. The model performed excellently discriminating between a benign ovarian tumor and Stages II–IV and between malignant stage I and stage II-IV, with an AUC of 0.99 and 0.92, respectively. The model's performance was less effective at distinguishing between borderline tumors and Stage I, with AUC values of 0.61[30].

This also coincides with the extensive study conducted by Van Calster et al. [10], including 5909 patients with ovarian masses, which stated that at a cut-off value of 10%, the IOTA-ADNEX model showed a performance with 96.5% sensitivity and 71.3% specificity. AUC for the classic discrimination between benign and malignant tumors was 0.94 (0.93 to 0.95) on temporal validation. The AUC was 0.92 for benign versus stage I and 0.99 for benign versus stage II-IV. AUCs between malignant subtypes varied between 0.71 and 0.95, with an AUC of 0.75 for borderline versus stage I cancer. Again, it performed better than our study in discriminating benign versus borderline with an AUC of 0.85.

In a retrospective study- including 514 women with adnexal masses- three diagnostic predictive models including Simple Rules, 0-RADS, ANDEX and Simple Rule Risk assessment SRR models were validated. The study concluded that simple rules and the ADNEX model presented higher performance accuracy with higher specificity and positive predictive value [31]. A meta-analysis including 11 studies using the IOTA-ADNEX model demonstrated that the MR-ADNEX scoring system had higher specificity but lower sensitivity when compared to the IOTA ADNEX model discriminating adnexal masses [32].

An interesting study evaluating the barriers to wider use of (IOTA) models in Dutch gynecological practice was recently published. The study concluded the need for more training and research on sensitivity, specificity, and cost-effectiveness to improve further implementation of the IOTA-ADNEX model [33].

Strength and Limitations

The Main point of strength of our study is that it is a prospective study, allowing rigorous data collection, methodology, and strict inclusion criteria. Clinicians compiled All collected information at each step of the patient's journey, ensuring the completeness and correctness of the data reported. All cases were scanned by the same sonographer, highly experienced in the IOTA ADNEX Model and with a special interest in gynecology scanning, eliminating any probable inter-observer variability.

Certainly, our study was not free of some limitations. The first is related to sample size and study duration, including a total of 150 patients (larger studies, over more prolonged periods, and preferably multicentric are needed). In addition, our study was conducted in a tertiary university hospital oncologic center, which may not be the real presentation when more widespread implementation is applied, limiting the broad application of our findings.

Conclusion

In our study, the IOTAADNEX model had high sensitivity and specificity for the detection of malignancy in preoperative assessment of suspicious adnexal masses with a high risk of malignancy index and showed moderate agreement with the histopathological assessment of adnexal masses in an Egyptian setting. The model's performance in distinguishing between the histology subtypes differed compared to different studies. More studies, preferably multicentric ones involving different continents, are needed to modify the model to yield uniform agreement when validated in different cancer centers worldwide.

Compliance with Ethical Standards:

Authors contribution

SSE, ASH, TAT, REN Conceptualization and Methodology. ASH Data curation. ASH and REN Project administration. ASH Formal Analysis. TAT Supervision, Validation. SSE, ASH Writing – original draft. All authors have read, reviewed, edited, and approved the final published version of the manuscript.

Funding

The study did not receive any funding grant.

Study Registration

N/A

Disclosure of interest

All authors declare they have no conflict of interest.

Ethical Approval

This study followed the ethical standards of the responsible committee on human experimentation (institutional and national) and with the Helsinki Declaration of 1975, as revised in 2008. The Faculty of Medicine, Alexandria University's ethical committee approved the study protocol.

Informed consent

Informed consent was obtained from all patients before being included in the study.

Data Sharing

N/A

References

1. Fitch M, Deane K, Howell D, Gray RE. Women's experiences with ovarian cancer: reflections on being diagnosed. *Can Oncol Nurs J* 2002; 12(3):152-68. doi:10.5737/1181912x123152159
2. Hakansson F, Hogdall EV, Nedergaard L, Lundvall L, Engelholm SA, Pedersen AT, et al. Risk of malignancy index used as a diagnostic tool in a tertiary centre for patients with a pelvic mass. *Acta Obstet Gynecol Scand* 2012; 91(4):496-502. doi: 10.1111/j.1600-0412.2012.01359.x. Epub 2012 Feb 22. PMID: 22229703.
3. Simsek HS, Tokmak A, Ozgu E, Doganay M, Danisman N, Erkaya S, et al. Role of a risk of malignancy index in clinical approaches to adnexal masses. *Asian Pac J Cancer Prev* 2014; 15(18):7793-7. doi: 10.7314/apjcp.2014.15.18.7793. PMID: 25292065.
4. Jacobs I, Oram D, Fairbanks J, Turner J, Frost C, Grudzinskas JG. A risk of malignancy index incorporating CA 125, ultrasound and menopausal status for the accurate preoperative diagnosis of ovarian cancer. *Br J Obstet Gynaecol* 1990; 97(10):922-9. doi: 10.1111/j.1471-0528.1990.tb02448.x
5. Tingulstad S, Hagen B, Skjeldestad FE, Onsrud M, Kiserud T, Halvorsen T, et al. Evaluation of a risk of malignancy index based on serum CA125, ultrasound findings and menopausal status in the pre-operative diagnosis of pelvic masses. *Br J Obstet Gynaecol* 1996; 103(8):826-31. doi: 10.1111/j.1471-0528.1996.tb09882.x. PMID: 8760716.
6. Tingulstad S, Hagen B, Skjeldestad FE, Halvorsen T, Nustad K, Onsrud M. The risk-of-malignancy index to evaluate potential ovarian cancers in local hospitals. *Obstet Gynecol* 1999; 93(3):448-52. PMID: 10074998.
7. Yamamoto Y, Yamada R, Oguri H, Maeda N, Fukaya T. Comparison of four malignancy risk indices in the preoperative evaluation of patients with pelvic masses. *Eur J Obstet Gynecol Reprod Biol* 2009; 144(2):163-7. doi: 10.1016/j.ejogrb.2009.02.048. Epub 2009 Mar 27. PMID: 19327881.
8. Ueland FR, DePriest PD, Pavlik EJ, Kryscio RJ, van Nagell JR. Preoperative differentiation of malignant from benign ovarian tumors: the efficacy of morphology indexing and Doppler flow sonography. *Gynecol Oncol* 2003; 91(1):46-50. doi: 10.1016/s0090-8258(03)00414-1. PMID: 14529661.
9. Kaloo P, Loudon K, Khazali S, Hoy D, Sadoon S. Management of suspected ovarian masses in premenopausal women. London: Royal College of Obstetricians and Gynaecologists; 2011. RCOG/BSGE National Green Top Guidelines No: 62
10. Van Calster B, Van Hoorde K, Valentin L, Testa AC, Fischerova D, Van Holsbeke C *et al.* Evaluating the risk of ovarian cancer before surgery using the ADNEX model to differentiate between benign, borderline, early and advanced stage invasive, and secondary metastatic tumours: prospective multicentre diagnostic study. *BMJ* 2014;15; 349:g5920. doi: 10.1136/bmj.g5920. PMID: 25320247; PMCID: PMC4198550.

11. Van Holsbeke C, Van Calster B, Testa AC, Domali E, Lu C, Van Huffel S, et al. Prospective internal validation of mathematical models to predict malignancy in adnexal masses: results from the international ovarian tumor analysis study. *Clin Cancer Res* 2009; 15(2):684-91. doi: 10.1158/1078-0432.CCR-08-0113. PMID: 19147775.
12. Timmerman D, Planchamp F, Bourne T, Landolfo C, du Bois A, Chiva L, et al. ESGO/ISUOG/IOTA/ESGE Consensus Statement on pre-operative diagnosis of ovarian tumors. *Int J Gynecol Cancer*. 2021 Jul;31(7):961-982. doi: 10.1136/ijgc-2021-002565. Epub 2021 Jun 10. PMID: 34112736; PMCID: PMC8273689.
13. Timmerman D, Valentin L, Bourne TH, Collins WP, Verrelst H, Vergote I. Terms, definitions and measurements to describe the sonographic features of adnexal tumors: a consensus opinion from the International Ovarian Tumor Analysis (IOTA) Group. *Ultrasound Obstet Gynecol* 2000; 16: 500–505. doi: 10.1046/j.1469-0705.2000.00287.x. PMID: 11169340.
14. Varga D, Deniz M, Schwentner L, Wiesmuller L. Ovarian cancer: in search of better marker systems based on DNA repair defects. *Int J Mol Sci* 2013; 14(1):640-73. doi: 10.3390/ijms14010640. PMID: 23344037; PMCID: PMC3565287.
15. Dang Thi Minh, N., Nguyen Van, T., Duong Duc, H., Nguyen Tuan, M., Duong Thi Tra, G., Do Tuan, D., & Nguyen Tai, D. (2024). IOTA simple rules: An efficient tool for evaluation of ovarian tumors by non-experienced but trained examiners - A prospective study. *Heliyon*, 10(2), e24262. <https://doi.org/10.1016/j.heliyon.2024.e24262>
16. Sayasneh A, Ferrara L, De Cock B, Saso S, Al-Memar M, Johnson S, et al. Evaluating the risk of ovarian cancer before surgery using the ADNEX model: a multicentre external validation study. *Br J Cancer* 2016; 115(5):542-8. doi: 10.1038/bjc.2016.227. Epub 2016 Aug 2. PMID: 27482647; PMCID: PMC4997550.
17. Joyeux E, Miras T, Masquin I, Duglet PE, Astruc K, Douvier S. [Before surgery predictability of malignant ovarian tumors based on ADNEX model and its use in clinical practice]. *Gynecol Obstet Fertil* 2016; 44(10):557-64. doi: 10.1016/j.gyobfe.2016.07.007. Epub 2016 Aug 24. PMID: 27568408.
18. Rai R, Bhutia PC, Tshomo U. Clinicopathological profile of adnexal masses presenting to a tertiary-care hospital in Bhutan. *South Asian J Cancer* 2019; 8(3):168-72. doi: 10.4103/sajc.sajc_303_18. PMID: 31489290; PMCID: PMC6699236.
19. Hada A, Han LP, Chen Y, Hu QH, Yuan Y, Liu L. Comparison of the predictive performance of risk of malignancy indexes 1-4, HE4 and risk of malignancy algorithm in the triage of adnexal masses. *J Ovarian Res* 2020; 13(1):46. doi: 10.1186/s13048-020-00643-6. PMID: 32334618; PMCID: PMC7183707.
20. Sumathi S. A Comparative study of RMI 1 and RMI 2 to Discriminate between Benign and Malignant Ovarian Tumors. Masters Thesis. Coimbatore: Coimbatore Medical College; 2019.
21. Suh-Burgmann E, Kinney W. The Value of Ultrasound Monitoring of Adnexal Masses for Early Detection of Ovarian Cancer. *Front Oncol* 2016; 6:25. doi: 10.3389/fonc.2016.00025. PMID: 26904503; PMCID: PMC4748035.

22. Valentini AL, Gui B, Miccò M, Mingote MC, De Gaetano AM, Ninivaggi V, et al. Benign and Suspicious Ovarian Masses-MR Imaging Criteria for Characterization: Pictorial Review. *J Oncol* 2012; 2012:481806. doi: 10.1155/2012/481806. Epub 2012 Mar 22. PMID: 22536238; PMCID: PMC3321462.
23. Moro F, Zannoni GF, Arciuolo D, Pasciuto T, Amoroso S, Mascilini F, et al. Imaging in gynecological disease (11): clinical and ultrasound features of mucinous ovarian tumors. *Ultrasound Obstet Gynecol* 2017; 50(2):261-70. doi: 10.1002/uog.17222. Epub 2017 Jun 22. PMID: 28782867.
24. Carvalho JP, Moretti-Marques R, Filho A. Adnexal mass: diagnosis and management. *Rev Bras Ginecol Obstet* 2020; 42(7):438-43. doi: 10.1055/s-0040-1715547. Epub 2020 Jul 31. PMID: 32736396; PMCID: PMC10316833.
25. Khurana I, Satia MN. Preoperative evaluation of ovarian masses with color Doppler and its correlation with pathological finding. *Int J Reprod Contracept Obstet Gynecol* 2016; 5(7):2084-92.
26. Mascilini F, Savelli L, Scifo MC, Exacoustos C, Timor-Tritsch IE, De Blasis I, et al. Ovarian masses with papillary projections diagnosed and removed during pregnancy: ultrasound features and histological diagnosis. *Ultrasound Obstet Gynecol* 2017; 50(1):116-23. doi: 10.1002/uog.17216. PMID: 27484484.
27. McHugh ML. Interrater reliability: the kappa statistic. *Biochem Med (Zagreb)* 2012; 22(3):276-82. PMID: 23092060; PMCID: PMC3900052.
28. Jeong SY, Park BK, Kim TJ, Lee YY. Validation of IOTA-ADNEX Model in Discriminating Characteristics of Adnexal Masses: A Comparison with Subjective Assessment. *J Clin Med* 2020; 9(6):2010. doi: 10.3390/jcm9062010. PMID: 32604883; PMCID: PMC7356034.
29. Tug N, Yassa M, Sargin MA, Taymur BD, Sandal K, Mega E. Preoperative discriminating performance of the IOTA-ADNEX model and comparison with Risk of Malignancy Index: an external validation in a non-gynecologic oncology tertiary center. *Eur J Gynaecol Oncol* 2020; 41(2):200-7. DOI: 10.31083/j.ejgo.2020.02.4971
30. Chen H, Qian L, Jiang M, Du Q, Yuan F, Feng W. Performance of IOTA ADNEX model in evaluating adnexal masses in a gynecological oncology center in China. *Ultrasound Obstet Gynecol* 2019; 54(6):815-22. doi: 10.1002/uog.20363. Epub 2019 Nov 11. PMID: 31152572.
31. Spagnol, G., Marchetti, M., De Tommasi, O., Vitagliano, A., Cavallin, F., Tozzi, R., Saccardi, C., & Noventa, M. (2023). Simple rules, O-RADS, ADNEX and SRR model: Single oncologic center validation of diagnostic predictive models alone and combined (two-step strategy) to estimate the risk of malignancy in adnexal masses and ovarian tumors. *Gynecologic Oncology*, 177, 109-116. <https://doi.org/10.1016/j.ygyno.2023.08.012>
32. Cui, L., Xu, H., & Zhang, Y. (2022). Diagnostic Accuracies of the Ultrasound and Magnetic Resonance Imaging ADNEX Scoring Systems For Ovarian Adnexal Mass: Systematic Review and Meta-Analysis. *Academic Radiology*, 29(6), 897-908. <https://doi.org/10.1016/j.acra.2021.05.029>.

33. Lems, E., Leemans, J., Lok, C., Bongers, M., & Geomini, P. (2023). Current uptake and barriers to wider use of the International Ovarian Tumor Analysis (IOTA) models in Dutch gynaecological practice. *European Journal of Obstetrics & Gynecology and Reproductive Biology*, 291, 240-246. <https://doi.org/10.1016/j.ejogrb.2023.09.018>.

Withdrawn

Tables:**Tab (1):** Histopathological findings in 150 women with adnexal mass

<i>Histological type</i>	n (%)
Benign (26.6%)	40
Endometrioma	6
Mucinous cystadenoma	6
Serous cystadenoma	16
Fibroma	8
Fibro-thecoma	4
Borderline ovarian tumour	14 (9.33%)
Serous	10
Mucinous	4
Primary Malignant ovarian tumours	90 (60 %)
Serous adenocarcinoma	30
Mucinous adenocarcinoma	14
Endometrioid carcinoma	14
Sero-mucinous carcinoma	4
Clear cell carcinoma	4
Granulosa cell tumor	16
Malignant teratoma	2
Carcinosarcoma	2
Malignant benner tumor	2
Undifferentiated ovarian carcinoma	2
Metastatic Ovarian tumours	6 (4%)

Table (2): Diagnostic accuracy of RMI 1 and RMI2 in predicting malignancy.

	Cutoff value	Sensitivity	Specificity	AUC	95% CI AUC
I 1	217.5	74.5	70.0	76.5	65.7-87.4
I 2	340	72.0	70.0	76.7	65.8-87.7

Table (3): Clinical characteristics and ultrasound findings in 150 women with adnexal masses, according to tumour histopathology subclassification :

Characteristics	Benign N= 40	Borderline N= 14	OC stage I N= 48	OC stage II-IV N= 48
Age (years)				
Min-max	21-47	37-50	14-46	33-60
Mean \pm SD	37.85 \pm 1.67	43.86 \pm 9.73	38.79 \pm 11.67	32.37 \pm 9.4
Menopausal State				
Pre-menopause				
Post-menopause	16 (40.0) 24 (60.0)	6 (42.9) 8 (57.1)	12 (25) 36 (75)	18 (37.5) 30 (62.5)
Elevated CA 125				
Yes	30 (75.0)	8 (57.1)	40 (83.3)	44 (91.7)
No	10 (25.0)	6 (42.9)	8 (16.7)	4 (8.3)
Presence of >10 locules				
Yes	4(10.0)	0(0)	6(12.5)	8(16.7)
No	36(90.0)	14(100)	42(87.5)	40(83.3)
No. of papillary projections				
No	28 (70.0)	12 (85.7)	34 (70.8)	30 (62.5)
One	6 (15.0)	0 (0)	2 (4.2)	2 (4.2)
Two	2 (5.0)	2 (14.3)	0 (0)	0 (0)
Three or more				

	4 (10.0)	0 (0)	6 (25.0)	16 (33.3)
Maximum diameter(mm)				
Min-max	30-210	70-230	80-750	48-30
Mean ±SD	120.5± 43.76	150± 62.05	169.16± 131.43	124.2± 58.5
Max diameter of the solid part				
Min-max	0-450	0-70	0-400	0-110
Mean ±SD	47.2 105.39	22.6 ±31.44	76.3± 81.09	58.71± 27.69
Ascites				
Yes	2 (5.0)	0 (0)	12 (25.0)	20 (41.7)
No	38 (95.0)	14 (100)	36 (75.0)	28 (58.3)
Bilaterality				
Yes	12 (30.0)	4 (28.5)	6 (12.5)	16 (33.3)
No	28 (70.0)	10 (71.4)	42 (87.5)	32 (66.7)

Table (4): IOTA-ADNEX Model classification versus histopathology

IOTA-ADNEX Model classes	Benign tumor n=40	Malignant tumor		
		Borderline tumor n=14	Tumor stage I n=48	Tumor stage II-IV n=48
	n(%)	n(%)	n(%)	n(%)
Benign	28(70.0)	8(57.1)	8(16.7)	4(8.3)
Borderline	4(10.0)	4(28.6)	14(29.2)	8(16.7)
Malignant stage I	0	0	4(8.3)	2(4.2)
Malignant stage II-IV	8(20.0)	2(14.3)	22(45.8)	34(70.8)

Table (5): The degree of agreement (inter-rater reliability) between IOTA-ADNEX Model classification and histopathology

IOTA-ADNEX Model based classification	Benign tumor n=40	Malignant tumor n=110	Kappa coefficient
	n(%)	n(%)	
Benign (n=48)	28	20	Kappa= 0.487
Percentage within histological type	70.0%	18.2%	
Percentage within IOTA classes	58.3%	41.7%	
Malignant (112)	12	90	
Percentage within histological type	30.0%	81.8%	
Percentage within IOTA classes	11.8%	88.2%	

Table (6): Diagnostic accuracy of IOTA ADENEX model in predicting malignancy:

	Cut off value	Sensitivity	Specificity	AUC	AUC 95% CI
IOTA MODEL score	42.0	83.6	75.0	81.0	70.1-91.9

Table (7): Pairwise AUC for IOTA ADENEX model

	Area under the curve (95% CI)
Benign versus borderline	0.564 (0.296-0.832)
Benign versus malignant stage I	0.815 (0.680-0.949)
Benign versus malignant stage II to IV	0.877 (0.767-0.987)
Borderline versus malignant stage I	0.798 (0.613-0.982)
Borderline versus malignant stage II-IV	0.875 (0.740-1)
Malignant stage I versus stage II-IV	0.681 (0.527-0.834)

Figure (1): Comparison between histopathological classification and IOTA-Adenex Model classification.

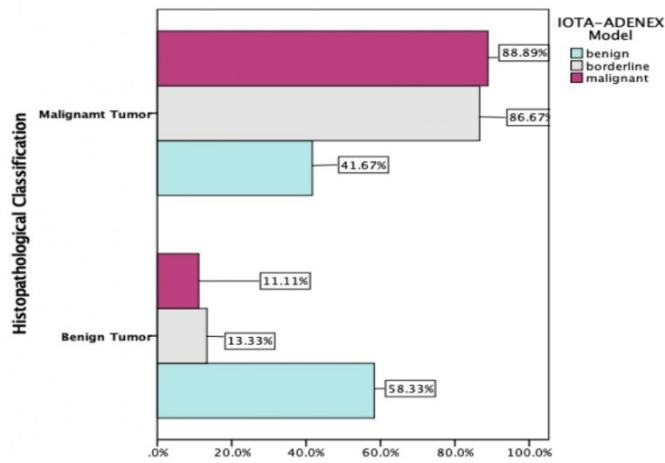


Figure (2): ROC curve analysis for diagnostic accuracy of IOTA-ADENEX model in predicting malignancy. **Figure (3):** IOTA-ADNEX of case 1

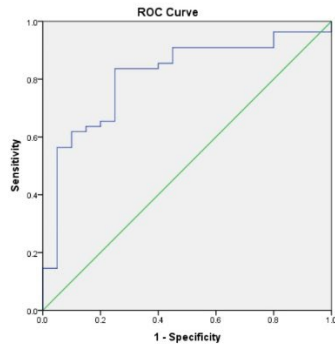


Figure (2): ROC curve analysis for diagnostic accuracy of IOTA-ADENEX model in predicting malignancy.

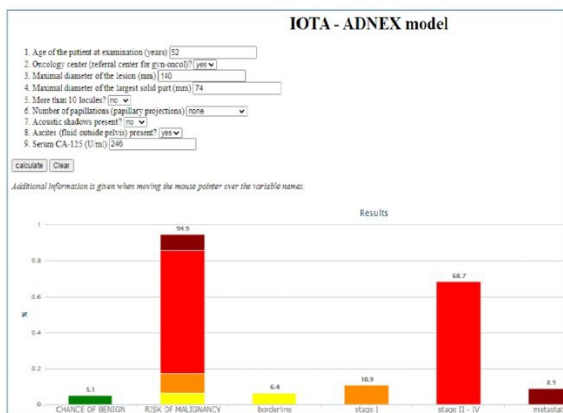


Figure (3): IOTA-ADNEX of case 1

Figure (4): TV-US of case 1 showing bilateral multilocular ovarian lesions with multiple septae, and solid contents. **Figure (5):** Gross pathology specimen of case1 (serous carcinoma of ovary and uterus)

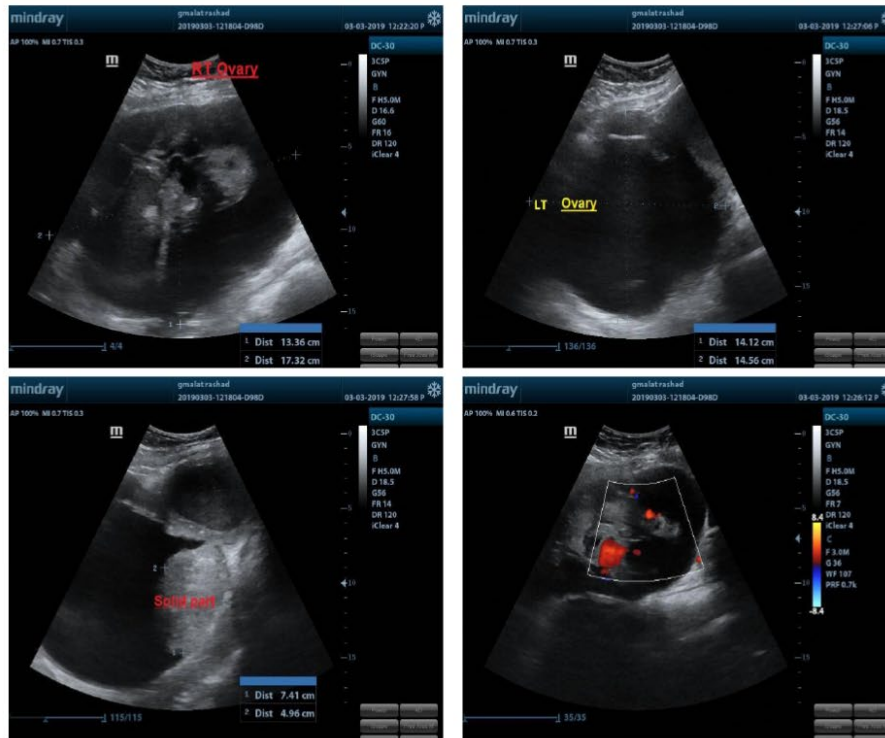


Figure (4): TV-US of case 1 showing bilateral multilocular ovarian lesions with multiple septae, and solid contents.

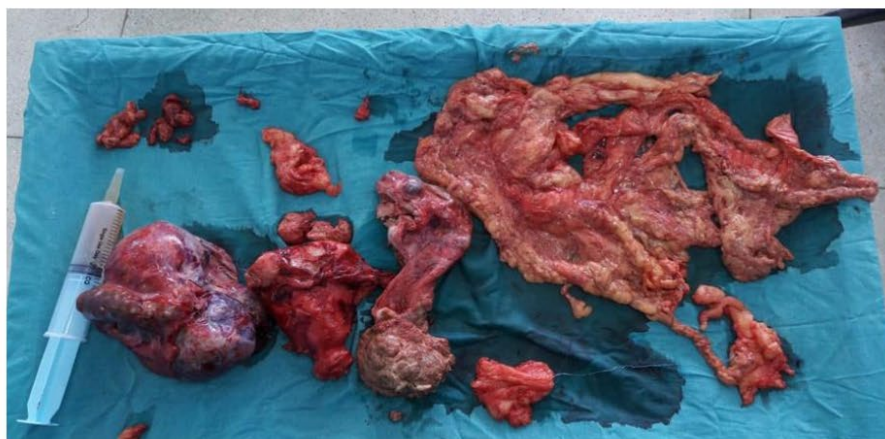

Figure (6): IOTA-ADNEX of case 2

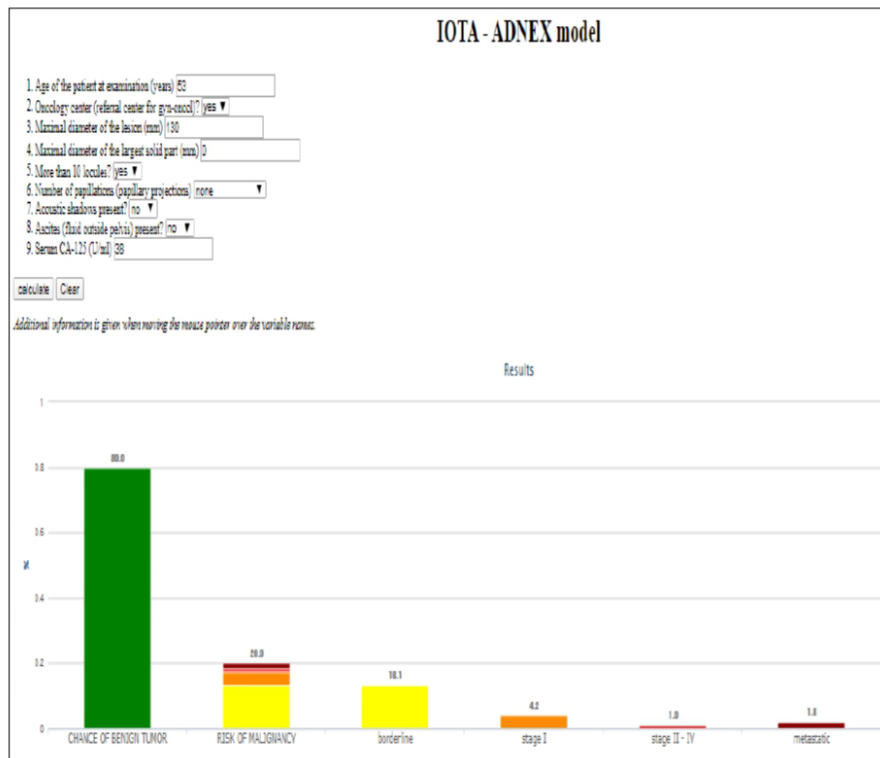


Figure (7): TV-US of case 2 showing right adnexal multilocular cyst.

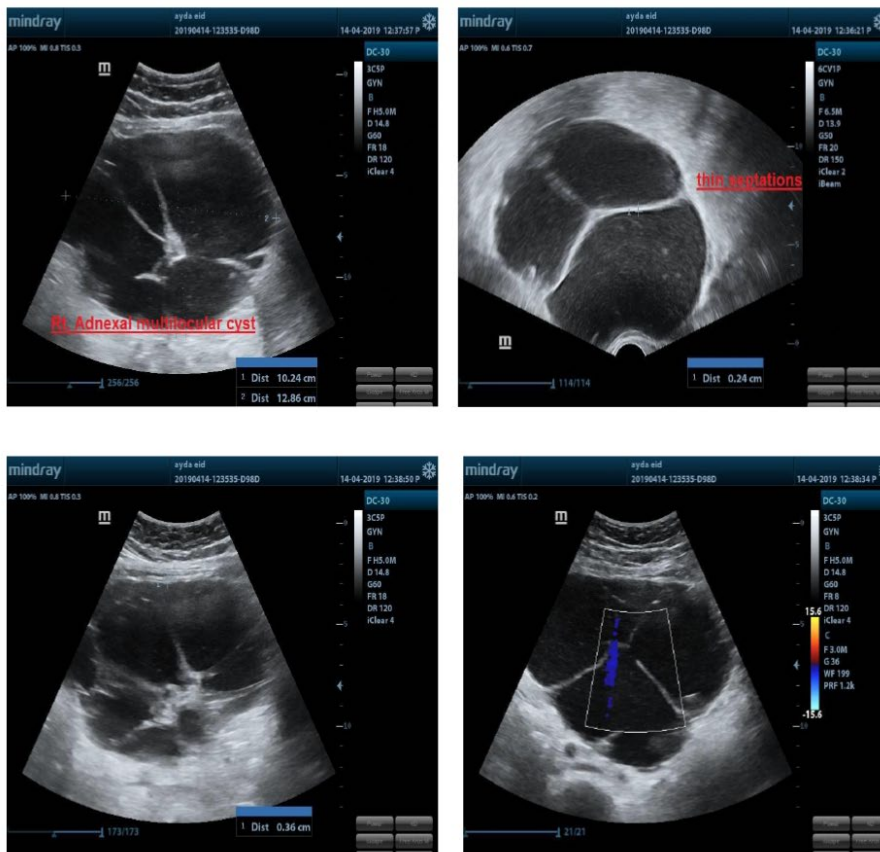


Figure (8): IOTA-ADNEX of case 3

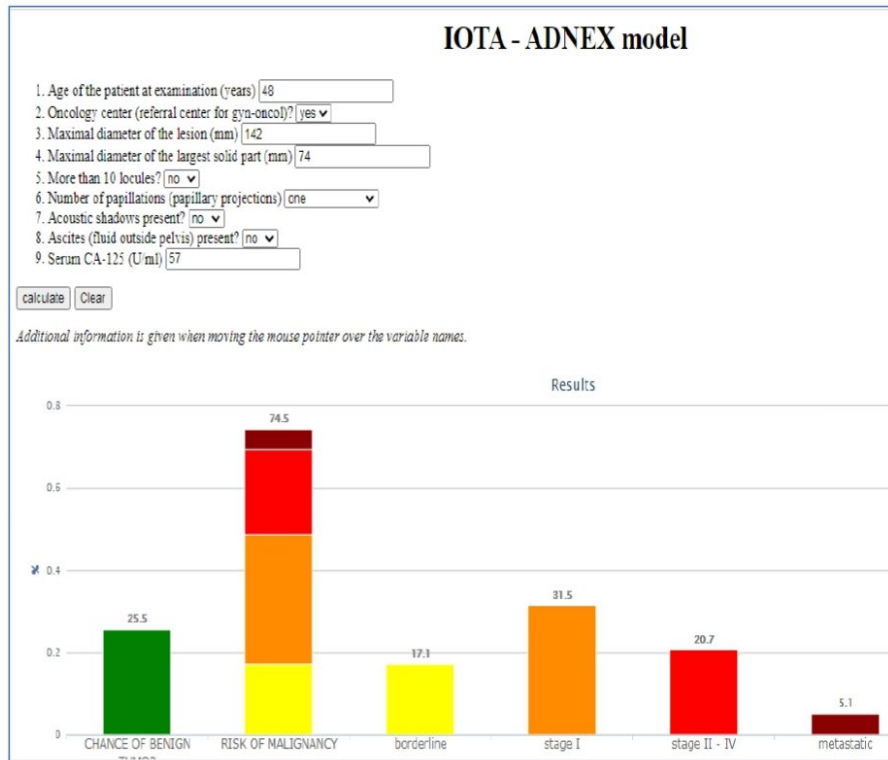


Figure (9): TV-US of case 3 showing Rt. Large unilocular solid pelviabdominal mass.

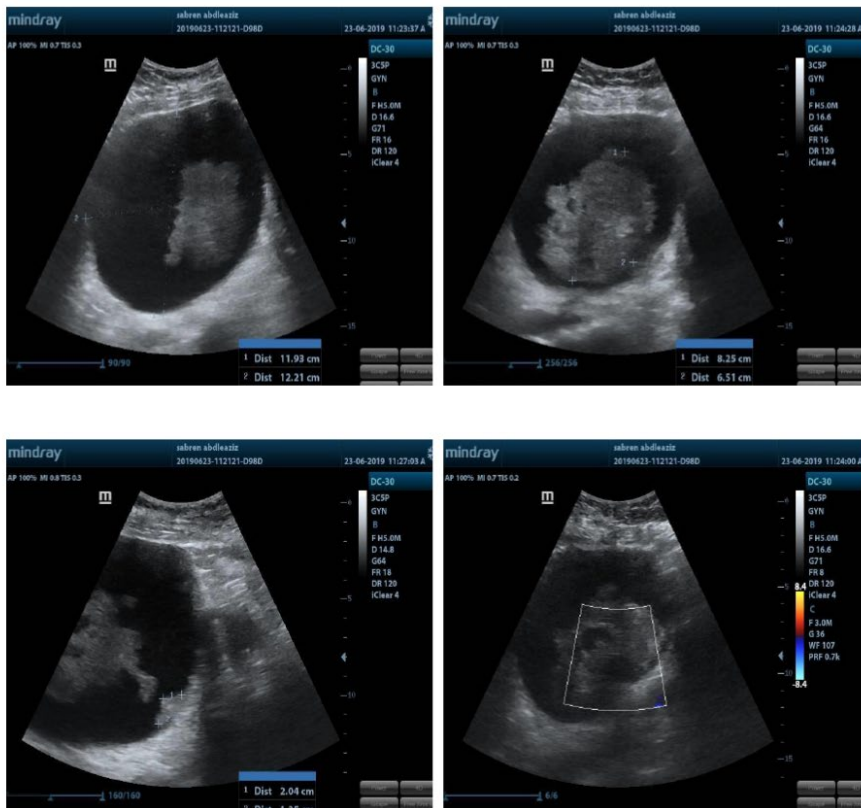


Figure (10): Gross pathology specimen of case 3 (Clear cell carcinoma of the Rt. Ovary & tube).

