

























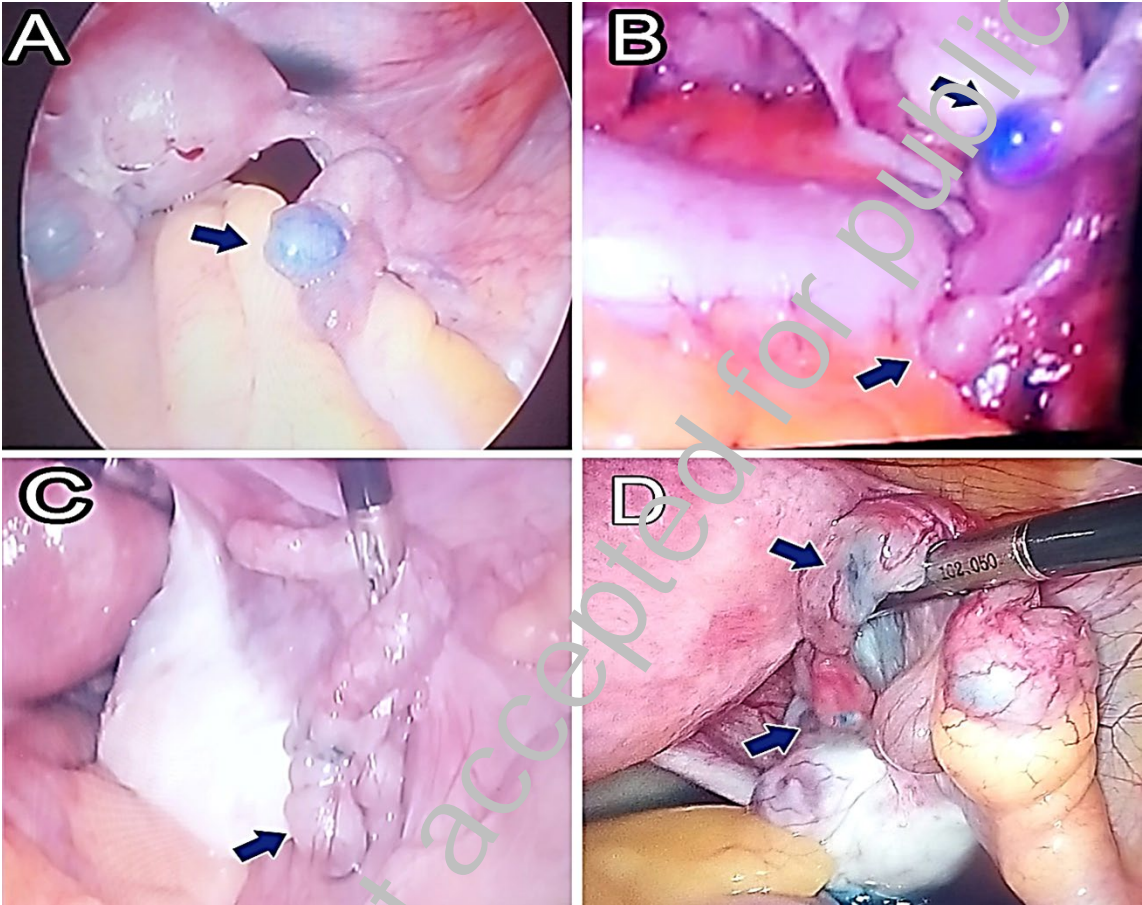






Figure 8. Combined Subtle Fallopian Tube Anomalies on the same tube.

- A. Sacculation & Phimosi
- B. Sacculation & Morgagni cyst.
- C. Phimosi & Morgagni cyst.
- D. Sacculation & accessory fimbrial ostium.



Manuscript accepted for publication