





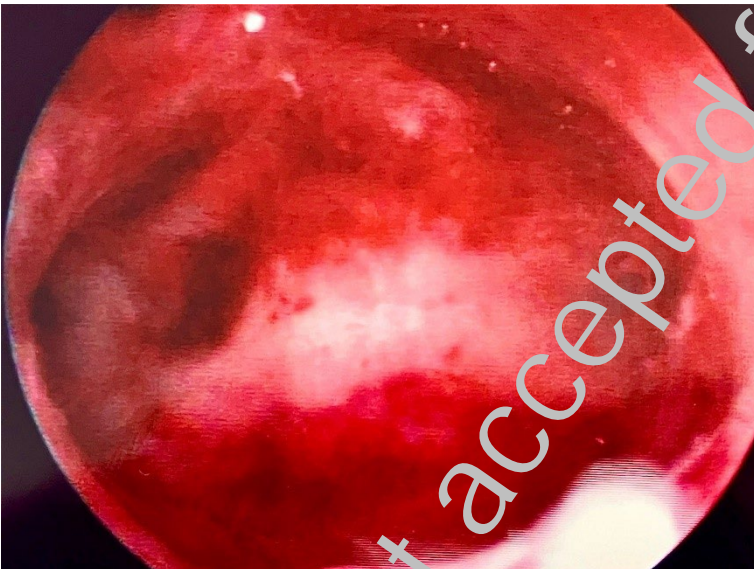




Fig 4. IUD fragments extracted

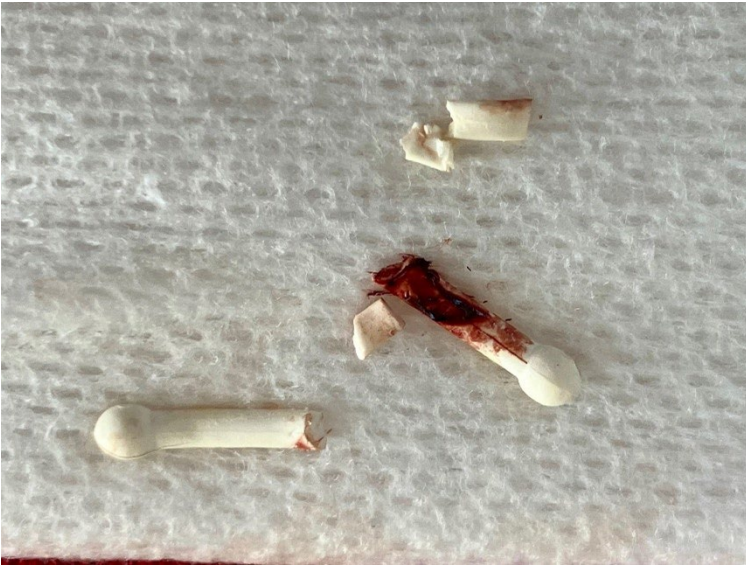

Fig 5. Uterine cavity at the end of the operation



Manuscript accepted for publication