





















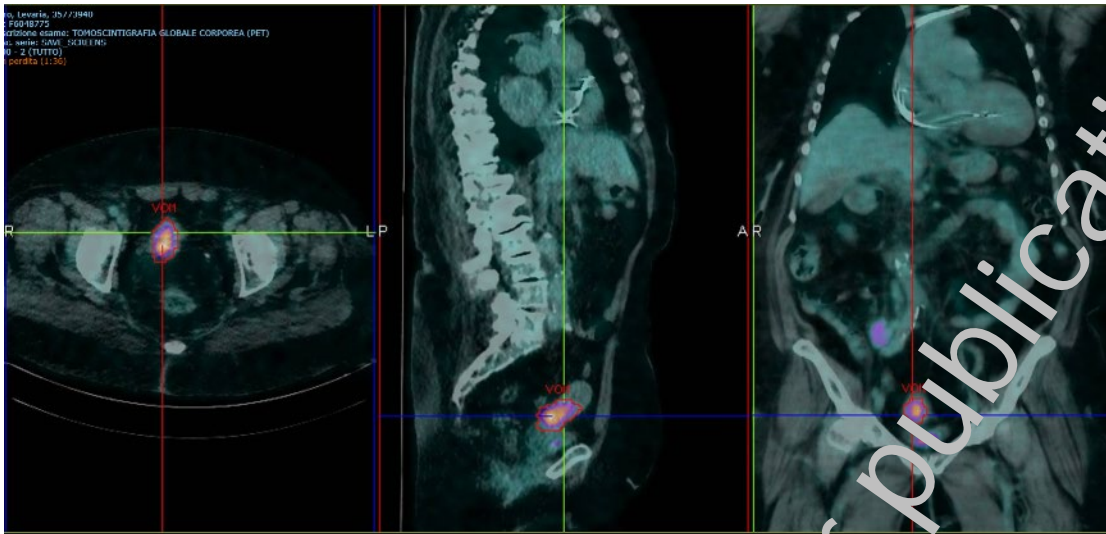




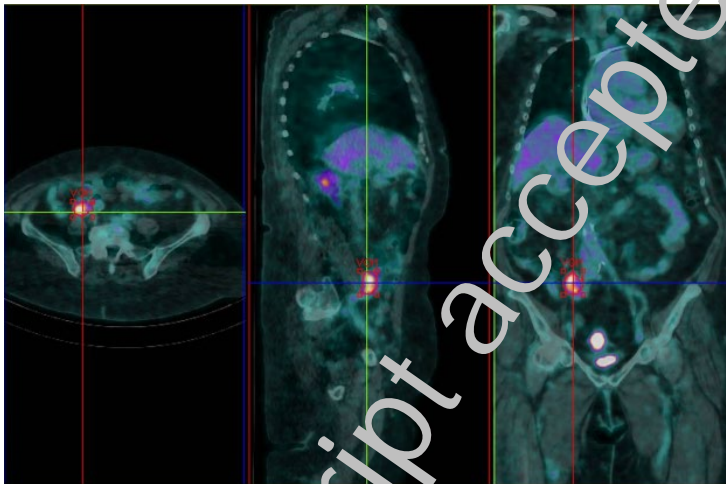




**Figure 4:** PET/TC scan: tracer accumulation in the endometrial cavity



**Figure 5:** PET/TC scan: tracer accumulation along the ilio-obturator axis on the right, with the largest accumulation along the common iliac vessels



**Figure 6:** Debulking of enlarged lymph nodes

