

**CASE REPORT**

**Uterine schwannoma during pregnancy: a rare case report**

Vincenzo **Spina**<sup>1</sup>, Pietro **Cignini**<sup>2</sup>, Francesco **Bisogni**<sup>2</sup>, Cristina **Fabiani**<sup>3</sup>, Michele Carlo **Schiavi**<sup>2</sup>, Debora **Grilli**<sup>2</sup>, Lorenzo **Campanella**<sup>2</sup>, Andrea **Etrusco**<sup>4</sup>, Rocco **Rago**<sup>3</sup>, Pierluigi **Palazzetti**<sup>2</sup>

<sup>1</sup> Department of Obstetrics and Gynaecology, “San Camillo de Lellis” Hospital, Rieti, Italy.

<sup>2</sup> Department of Obstetrics and Gynaecology “Sandro Pertini” Hospital, Rome, Italy.

<sup>3</sup> Department of Pathophysiology of Human Reproduction “Sandro Pertini” Hospital, Rome, Italy.

<sup>4</sup> Unit of Obstetrics and Gynecology, “Paolo Giaccone” Hospital, Department of Health Promotion, Mother and Child Care, Internal Medicine and Medical Specialties (PROMISE), University of Palermo, Palermo, Italy.

**\*Corresponding author:** Pietro **Cignini**, Department of Obstetrics and Gynaecology “Sandro Pertini” Hospital, Via dei Monti Tiburtini, Rome, Italy.

Email: info@pietrocignini.it.

ORCID: 0000-002-6601-3782.

**Doi:** 10.36129/jog.2024.165

**ABSTRACT**

**Background.** Schwannomas are nerve sheath neoplasms that form from Schwann cells. These tumors are normally found as a solitary, painless, slow-growing mass of varied size, and they are usually asymptomatic. The uterine cervix is an exceptionally unusual place of occurrence in the female genital system, and schwannomas are infrequent in this area. The purpose of this case report was to contribute to the growing body of knowledge regarding a rare site of schwannomas incidence and its subsequent implications during a normal and physiologic pregnancy.

**Case presentation.** A 37-year-old lady 0 para came to us in May 2011 at 6 weeks pregnant for obstetric care for her first pregnancy. With the exception of vitamins throughout pregnancy, the lady had no visible ailments and did not take any medicine. The patient underwent C-section at 39 weeks gestation in December 2011 for cephalo-pelvic disproportion. A grayish oval solid lesion 3 × 2 × 1 cm in diameter was removed from the uterine cavity and sent for pathological examination immediately after the placenta was expelled. Histopathology and immunohistochemistry revealed a benign schwannoma. There were no effects noted for the present pregnancy or the following one.

**Conclusions.** According to the current literature, diagnosis of this tumor during pregnancy and its eventual impact on pregnancy requires more research and inquiry. The goal of this case study was

to add to the current scientific knowledge concerning the prevalence of schwannomas and their consequences during a normal and healthy pregnancy.

### **Key word**

Schwannoma; neurilemmoma; pregnancy outcomes; nerve sheath tumor; uterine rare neoplasm.

## **INTRODUCTION**

Schwannomas are neoplasms of the nerve sheath that arise from Schwann cells. These tumors are typically detected as a single, painless, slow-growing mass of varying size and, until their massive growth compresses adjacent organs, they are usually asymptomatic [1]. They typically affect the superficial soft tissues of the extremities, most commonly the head and neck region and the distal parts of the extremities [2–4]. Large tumors are uncommonly found in the posterior mediastinum or retroperitoneum. When schwannomas are found in the pelvic cavity, they are frequently misdiagnosed as gynecologic masses [5]. Typical schwannomas can also primarily affect visceral sites like the gastrointestinal tract, kidneys, and breasts [6–8]; however, diagnosis in the uterine cervix is extremely rare [9]. To our knowledge, fifteen examples of uterine schwannoma originating from the cervix have been recorded, with histopathologic investigation confirming the malignant character of these tumors in ten of these cases [10].

The purpose of this clinical case was to enrich the expanding body of information on a very rare location of schwannomas, such as uterine schwannomas, and how they may possibly affect pregnancy outcome.

## **CASE PRESENTATION**

### **Anamneses**

A 37-year-old nulliparous woman with a BMI of 24, came to our attention on the occasion of her first pregnancy for routine obstetrical care at week 6<sup>+0</sup> of gestation. The patient had a negative near and remote pathological history and a silent family history, was not taking chronic drug therapies except for commonly taken pregnancy supplements. Five months earlier, the patient had undergone diagnostic hysteroscopy for menstrual irregularities. The examination had documented a regular uterine cavity with total absence of neoformations.

Current pregnancy was achieved spontaneously. A threatened miscarriage occurred during the first trimester of pregnancy, necessitating the administration of vaginal progesterone 200 mg twice daily.

### **Intervention**

Thereafter, the course of pregnancy was smooth, with fetal growth in the upper part of the normal range for gestational age and no congenital abnormalities.

Due to anemia, the patient started martial therapy during the third trimester. The patient underwent elective cesarean section at 39<sup>+0</sup> weeks' gestation for cephalo-pelvic disproportion. A 3800 g male baby was born with an Apgar score of 9 at 1 minute and 10 at 5 minutes.

Secondment was spontaneous and complete. Following placental discharge, a solid, oval-shaped, grayish-colored lesion measuring 3 x 2 x 1 cm was recovered during uterine cavity cleaning maneuvers. The above endouterine neof ormation was sent for definitive histological examination.

### **Histopathology**

Histopathology and immunohistochemistry revealed a benign schwannoma (negativity for cytokeratin, HMB45, actin, desmin, and CD34; positivity for S 100 protein) (Fig. 1-2).

### **Follow-up**

The patient was discharged home the day after surgery after a smooth postoperative course without complications. The patient subsequently underwent serial ultrasound checks every three months and one year after delivery also hysteroscopic reevaluation: none of the examinations performed showed recurrences.

Five years later, the patient became pregnant again. The pregnancy continued uneventfully, with regular fetal growth, and ended with an elective cesarean delivery. Also on this occasion, no recurrence of the schwannoma occurred.

## **DISCUSSION**

The cervix is an exceptionally unusual site for schwannomas of the female genital system [10].

Only three cases of uterine schwannoma originating from the body of the uterus have been de-

scribed so far, the total number of which were malignant tumors [11]. These lesions could sometimes enter differential diagnoses with more common tumors of the genital tract. In case of suspicion of endocavitary pathology, the patient must always be offered a diagnostic hysteroscopy, carried out by a gynecologist with adequate training, to exclude any malignant lesions [12]. Patients with malignant schwannoma have a poor prognosis. At the time of diagnosis, 16% of patients had metastatic disease, with the lungs as the predominant site of metastasis [13]. Malignant schwannoma has a high risk of local recurrence and a propensity to arise in areas already subjected to radiation [14].

Our case, to the best of our knowledge, represents the first described case in which the lesion originated from the uterine cavity and was benign on final histopathologic examination. The uniqueness of the case is made even greater by the fact that it developed from scratch during pregnancy. Despite its growth during the gestation period, this did not cause any problems for the pregnancy. Although it was not discovered during routine ultrasound checks of pregnancy, we can speculate that it did not result in any problems basically for two reasons: its small size prevented the establishment of any mass effect on the unborn child; its position did not impede the regular development of pregnancy. Furthermore, if the size of the fetus had not been disproportionate to the maternal pelvis, thus predisposing the unborn child to brachial plexus damage [15], a spontaneous vaginal delivery could have been attempted.

In most cases of benign schwannomas, surgical excision is suggested, as they rarely return if completely excised [16]. In our opinion, surgery is the preferred treatment option. A laparoscopic method has the advantage of a complete examination of the abdomen. A successful surgical excision of a retroperitoneal schwannoma was described in literature [17]. Surgery can be difficult and risky, possibly leading to a conversion to a laparotomic approach, which is still regarded a viable solution.

The surrounding structures, such as the ureter or bladder, may be injured. Because schwannoma develops from nerve supporting cells, it may cause neurological disability. A literature assessment, however, suggests that individuals getting full surgical resection perform well with no indication of

early recurrence [18]. Our belief is that the surgical procedure should focus on thorough removal of the encapsulated tumor and be carried out by an experienced gynecological surgeon.

However in the case of uterine schwannomas arising during pregnancy, where a strict follow-up should be suggested in order to notice any possible effect on the wealth of the pregnancy, our case demonstrates that placental secondment and normal endocavitary toilet are sufficient to avoid recurrence. It would be extremely interesting to understand what relationships may be established with the endometrium of nonpregnant patients and whether the succession of menstrual cycles may be sufficient to eliminate it.

The extreme rarity of the condition, however, does not allow us to arrive at solid evidence and establish unequivocally how much uterine schwannoma arising during pregnancy may pose an actual threat to the unborn child.

## **CONCLUSIONS**

Although schwannomas are uncommon in the cervix and uterine cavity, they should be examined in the differential diagnosis of any unexplained uterine or cervical cancer. Because of their rarity, these tumors continue to be difficult for both physicians and pathologists to diagnose. To our knowledge, the occurrence of uterine schwannomas during pregnancy has never been described before. Our experience, although confined to the single clinical case given the extreme rarity of the pathology, has shown that these types of lesions, if they arise during pregnancy, do not pose a danger to the pregnancy itself. Although complete surgical resection is currently the mainstay of treatment and the goal of radicality should always guide the decision-making process, our case demonstrates that in cases of uterine schwannomas arising during pregnancy placental secondment and normal endocavitary toilet are sufficient to prevent their recurrence.

## **COMPLIANCE WITH ETHICAL STANDARDS**

P.C Conceptualization, Data curation, Formal Analysis, Investigation, Methodology, Project administration, Resources, Software, Supervision, Validation, Visualization, Writing – original draft, Writing – review & editing.

V.S Conceptualization

F.B Conceptualization

C.F Conceptualization

M.C.S Conceptualization

D.G Conceptualization

L.C Conceptualization, Data curation, Formal Analysis, Investigation, Methodology, Project administration, Resources, Software, Supervision, Validation, Visualization, Writing – original draft, Writing – review & editing.

A.E Conceptualization, Data curation, Formal Analysis, Investigation, Methodology, Project administration, Resources, Software, Supervision, Validation, Visualization, Writing – original draft, Writing – review & editing.

R.R Conceptualization

P.P Conceptualization

**Disclosure of interests:**

All Authors have no proprietary, financial, professional or other personal interest of any nature in any product, service or company.

In writing the article, we have carefully followed the Journal's Author Guidelines, and we performed accurate language revision before submission.

**Informed consent:**

Each enrolled patient gave informed consent to allow data collection and analysis for research purposes before to start the study .

**Funding:**

The study was not supported by any fund/grant, and no remuneration was offered to encourage patients to give consent to enter, continue or complete the study.

### **Ethical approval:**

Presentation of the Manuscript conforms with the Uniform Requirements for Manuscripts Submitted to Biomedical Journals (N Engl J Med. 1997;336:309-15) drawn up by the International Committee of Medical Journal Editors (ICMJE), the Committee on Publication Ethics (COPE) guidelines (<http://publicationethics.org/>) and the specific guidelines the Enhancing the QUALity and Transparency Of health Research (EQUATOR) network ([www.equator-network.org](http://www.equator-network.org)). This study is in line with the Strengthening the Reporting of Observational Studies in Epidemiology (STROBE) Statement (<https://www.equator-network.org/reporting-guidelines/strobe/>), the REporting of studies Conducted using Observational Routinely-collected health Data (RECORD) Statement (<https://www.equator-network.org/reporting-guidelines/record/>) and/or the Consensus-Based Checklist for Reporting of Survey Studies (CROSS) Statement (<https://www.equator-network.org/reporting-guidelines/a-consensus-based-checklist-for-reporting-of-survey-studies-cross/>).

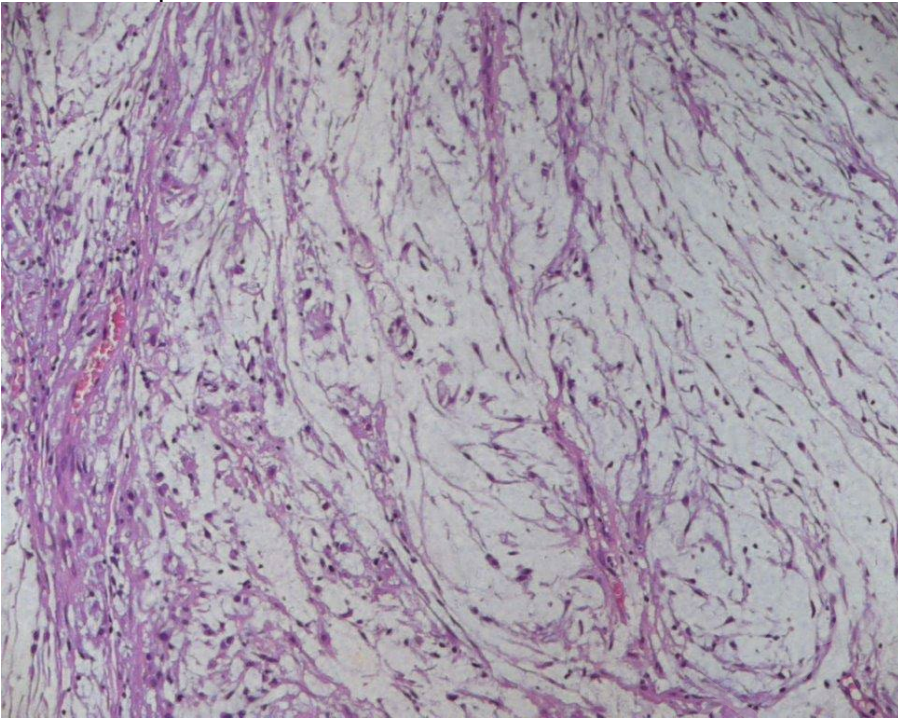
### **REFERENCES**

- [1] Giunta G, DE Baerdemaeker R, Zeltzer AA, Hamdi M. Schwannoma Arising from the Deep Motor Branch of the Ulnar Nerve - A Case Report and Review of Literature. *J Hand Surg Asian Pac* Vol. 2022;27(2):366-369. doi: 10.1142/S2424835522720109.
- [2] Douglas VP, Flores C, Douglas KA, Strominger MB, Kasper E, Torun N. Oculomotor nerve schwannoma: case series and literature review. *Surv Ophthalmol*. 2022;67(4):1160-1174. doi: 10.1016/j.survophthal.2021.11.008.
- [3] Zhang Y, Wei Z, Zhang G, Wang D. Sciatic Nerve Schwannoma in the Lower Limb Mimicking Ganglion Cyst. *Am J Phys Med Rehabil*. 2022;101(9):e143-e144. doi: 10.1097/PHM.0000000000002013.
- [4] Ye P, He C, Chen Y, Wu H, Li Y, Cai C, Lü P. Cervical vagal nerve schwannoma induced arrhythmia: a rare case report and literature review. *BMC Neurol*. 2022;22(1):480. doi: 10.1186/s12883-022-03016-2.
- [5] Insinga S, Cucinella G, Di Donna MC, Etrusco A, Mascellino G, Laganà AS, Chiantera V. Surgical Neuropelveology: Laparoscopic Nerve-sparing Excision of a Pelvic Schwannoma. *J Minim Invasive Gynecol*. 2023;30(9):691. doi: 10.1016/j.jmig.2023.06.003.
- [6] An X, Liu J, Yang B, Zhang W, Dong X. Primary cellular schwannoma of the kidney. *Pathol Int*. 2023;73(10):530-532. doi: 10.1111/pin.13370.
- [7] Dialani V, Hines N, Wang Y, Slanetz P. Breast schwannoma. *Case Rep Med*. 2011;2011:930841. doi: 10.1155/2011/930841.
- [8] Qi Z, Yang N, Pi M, Yu W. Current status of the diagnosis and treatment of gastrointestinal schwannoma. *Oncol Lett*. 2021;21(5):384. doi: 10.3892/ol.2021.12645.
- [9] Dey B, Chanu SM, Mishra J, Marbaniang E, Raphael V. Schwannoma of the uterine cervix: a rare case report. *Obstet Gynecol Sci*. 2019;62(2):134-137. doi: 10.5468/ogs.2019.62.2.134.

- [10] Tahmasbi M, Nguyen J, Ghayouri M, Shan Y, Hakam A. Primary uterine cervix schwannoma: a case report and review of the literature. *Case Rep Pathol.* 2012;2012:353049. doi: 10.1155/2012/353049.
- [11] Sengar Hajari AR, Tilve AG, Kulkarni JN, Bharat R. Malignant peripheral nerve sheath tumor of the uterine corpus presenting as a huge abdominal neoplasm. *J Cancer Res Ther.* 2015;11(4):1023. doi: 10.4103/0973-1482.147694.
- [12] Mazzon I, Etrusco A, Laganà AS, Chiantera V, Di Angelo Antonio S, Tosto V, Gerli S, Favilli A. Training in Diagnostic Hysteroscopy: The "Arbor Vitae" Method. *Medicina (Kaunas).* 2023;59(6):1019. doi: 10.3390/medicina59061019.
- [13] Somatilaka BN, Sadek A, McKay RM, Le LQ. Malignant peripheral nerve sheath tumor: models, biology, and translation. *Oncogene.* 2022;41(17):2405-2421. doi: 10.1038/s41388-022-02290-1.
- [14] Hall JC, Chang SD, Wilson TJ, Ganjoo KN, Toland A, Vogel H, Pollom EL, Rahimy E. Post-operative Stereotactic Radiosurgery of Malignant Melanotic Schwannoma. *Cureus.* 2022;14(3):e22849. doi: 10.7759/cureus.22849.
- [15] Tomasello G. ANATOMICAL DISSECTION AND ANALYSIS OF THE STRUCTURES OF THE UPPER LIMB. *EuroMediterranean Biomedical Journal* 2017:13–6. <https://doi.org/10.3269/1970-5492.2017.12.4>.
- [16] Hong X, Wu W, Wang M, Liao Q, Zhao Y. Benign gastric schwannoma: how long should we follow up to monitor the recurrence? A case report and comprehensive review of literature of 137 cases. *Int Surg.* 2015;100(4):744-7. doi: 10.9738/INTSURG-D-14-00106.1.
- [17] Descazeaud A, Coggia M, Bourriez A et al. Laparoscopic resection of a retroperitoneal schwannoma. *Surg Endosc* 2003;17:520.
- [18] Daneshmand S, Youssefzahed D, Chamie K et al. Benign retroperitoneal schwannoma: a case series and review of the literature. *Urology* 2003; 62:993-7.



**Figure 1.** Histopathology of the uterine schwannoma. Medium power view: Benign mesenchymal neoplasia, characterized by spindle cells without nuclear atypia and mitotic activity; ectasic blood vessels are present.



**Figure 2.** Immunohistochemistry of the uterine schwannoma. Immunohistochemical staining has shown intense immunoreactivity for S-100 protein.

