



Italian Journal of Gynæcology & Obstetrics

September 2024 - Vol. 36 - N. 3 - Quarterly - ISSN 2385 – 0868

Array comparative genomic hybridisation in a foetus with thoracic ectopia cordis: a case report

Valeria Ghisu¹, Marta Gargiulo¹, Stefania Sanna¹, Agnese Maria Chiara Rapisarda^{1,*}, Clara Gerosa², Roberta Murru³, Sabrina Rita Giglio³, Stefano Angioni¹

¹ Division of Gynecology and Obstetrics, Department of Surgical Sciences, University of Cagliari, Cagliari, Italy.

² Department of Pathology, University of Cagliari, Cagliari, Italy.

³ Department of Medical Genetics, University of Cagliari, Cagliari, Italy.

ARTICLE INFO

History

Received: 05 August 2023

Received in revised form: 28 January 2024

Accepted: 22 February 2024

Available online: 20 September 2024

DOI: 10.36129/jog.2024.157

Key words

Array-CGH; prenatal diagnosis; colour-Doppler ultrasonography; ectopia cordis; genetic counselling.

*Corresponding author: Agnese Maria Chiara Rapisarda, M.D. Division of Obstetrics and Gynecology, Department of Surgical Sciences, University of Cagliari, Cittadella Universitaria, Blocco Q, 09042 Monserrato, Italy.
Email: rapisardaagnesemc@gmail.com.
ORCID: 0000-0002-9560-7598.

ABSTRACT

Background. Ectopia cordis (EC) is a rare anomaly characterized by abnormal heart positioning. The exact aetiology remains unknown, is likely to be associated with genetic and environmental factors. The introduction of an array-based comparative genomic hybridization (a-CGH) test has broadened our understanding of the genetic basis of many foetal anomalies, providing a more precise characterization of imbalances and allowing the comparison of the phenotype with other patients displaying imbalances in the same region. We report a rare case of ectopia cordis associated with the coexistence of a rare deletion in chromosome 19.

Case presentation. A 28-year-old primigravida was referred to our hospital for abortion. Ultrasonography was performed to establish a gestational age of 17th weeks. A single foetus with isolated ectopia cordis with herniation of the heart from the right chest has been reported. The patient underwent therapeutic abortion. Anatomopathological examination of the foetus and whole genome a-CGH of the DNA of a flap of foetal skin was performed. Based on the cytogenetic analysis, the foetal karyotype was 46, XX. A-CGH analysis has detected a deletion of the short arm of chromosome 19 in the 19p13.3 band, containing the OMIM genes: TLE6-2-5, GNA11 and GNA15, S1PR4, and NCLN.

Conclusions. The diagnosis of EC with sonography is important to identify the main defect and its associated abnormalities. There is no evidence that EC is a genetically transmitted disease, however, a-CGH analysis may be an excellent tool in providing adequate counselling for families.

INTRODUCTION

Ectopia cordis (EC) is a rare congenital disorder characterized by an abnormal heart position. It has a frequency of 5.5-7.9 per 1 million births, being more common in female foetuses and accounting for 0.1% of congenital heart diseases. Based on the anatomi-

cal position, it is classified into cervical (3% of cases), cervico-thoracic (< 1%), thoracic (60%), abdominal (30%), and thoraco-abdominal (7%) [1]. The thoracic type is the most frequent, with the heart either partially or totally exposed on the surface of the thorax through an opening in the sternum and presenting an open pericardial sac. In the abdominal type

there is a primary defect in the diaphragm through which the heart protrudes into the abdominal cavity. The thoraco-abdominal type is present in Cantrell's Pentalogy, a syndrome characterized by a median supra-umbilical defect of the abdominal wall, diaphragmatic defect, defect of the diaphragmatic pericardium, defect of the lower part of the sternum, and heart malformations [2]. The cervical type is characterized by the dislocation of the heart within the cervical region, and always results in intrauterine death, as it is incompatible with life.

The aetiology of EC probably results from a combination of environmental and genetic factors but has yet to be fully understood. The heart is positioned outside the thorax in the early stages of embryonic development. With the normal folding of the embryo, the heart then assumes its definitive position within the pericardial sac. During the fourth week of organogenesis, the lack of complete fusion of the lateral folds in the chest wall formation can cause the abnormality [3]. Another possible mechanism is the rupture of the yolk and chorionic sac, which can lead to the formation of fibrous bands that disrupt the fusion in the midline of the chest wall. An alternative theory is the mutation of the bone morphogenetic protein (BMP2) gene that plays a vital role in heart formation and ventral body closure of the chest wall [4].

Ectopia cordis can easily be recognized in prenatal life; the ultrasound diagnosis relies on demonstrating a pulsating mass representing the heart outside the thoracic cavity and can be further confirmed with colour-Doppler. With the widespread incorporation of first-trimester ultrasound examination into early antenatal care, an increasing number of foetuses with major congenital anomalies can potentially be detected before 14 weeks of gestation [5, 6]. Specifically, the thoracic type of ectopia cordis can be more easily diagnosed than the thoracic-abdominal type. The recognition of associated cardiac anomalies, instead, is challenging, and it can be more feasible in the second or third trimester, thanks to the better visualization of the foetus [7]. Therefore, an accurate and early echocardiographic study is crucial in any case of structural anomalies as it may coexist with other cardiac anomalies [8]. In the case of ectopia cordis, an association with tetralogy of Fallot, transposition of the great arteries (TGA), ventricular septal defect (VSD), atrial septal defect, double-outlet right ventricle, ventricular hypoplasia, or tricuspid valve atresia has been reported. In addition to cardiac, extracardiac malformations have also been

described. Echocardiography can more accurately define the diagnosis and provide valuable information for clinical and surgical management, as well as neonatal prognosis. Indeed, the possibility and efficacy of surgery in a surviving neonate strictly depend on the degree of ectopia cordis and coexisting congenital heart defects and/or extracardiac malformations [3].

Genetic tests also provide increasingly valuable information to better define the foetus's prognosis. They are crucial to perform proper genetic counselling and discussing future reproductive options. Recently, the introduction of array comparative genomic hybridization (a-CGH) in prenatal diagnosis has offered much greater diagnostic yields in foetuses with congenital anomalies than karyotype analysis [9]. However, genetic anomalies associated with ectopia cordis have not yet been completely defined. This paper presents a thoracic case of ectopia cordis diagnosed by ultrasound at the 17th week of gestation in which the comparative genomic hybridization analysis revealed a deletion of chromosome 19.

CASE PRESENTATION

A 28-year-old woman, with an obstetric history of a previous pregnancy, was referred to our hospital for a request of abortion for an unwanted pregnancy. In her medical history, the patient reported an estrogen-progestin therapy with ethinylestradiol 30 mcg + gestodene 75 mcg for contraceptives. However, contraception was likely not entirely effective due to antibiotic therapy prescribed for odontopathy. The patient did not perform any obstetric-gynaecological checks in the previous months. Our first transabdominal ultrasound scan detected a single foetus, with an estimated age of 17 weeks of gestation and foetal heart rate (FHR) was 147 bpm. Foetal biometry revealed a bi-parietal diameter (BPD) of 36 mm, head circumference (HC) of 141 mm, abdominal circumference (AC) of 124 mm, femur length (FL) of 22 mm, cerebellum of 17 mm, cisterna magna (CM) 2.9 mm, an anterior placenta and normal amniotic fluid. Ectopia cordis with herniation of the heart from the right chest wall was reported (**Figures 1 and 2**).

The patient was hospitalised to start the therapeutic abortion procedure by taking Mifepristone 600 mg, followed by Misoprostol 400 mcg orally every 3 hours three times. Curettage of the uterine cavity was completed after the expulsion of the foetus

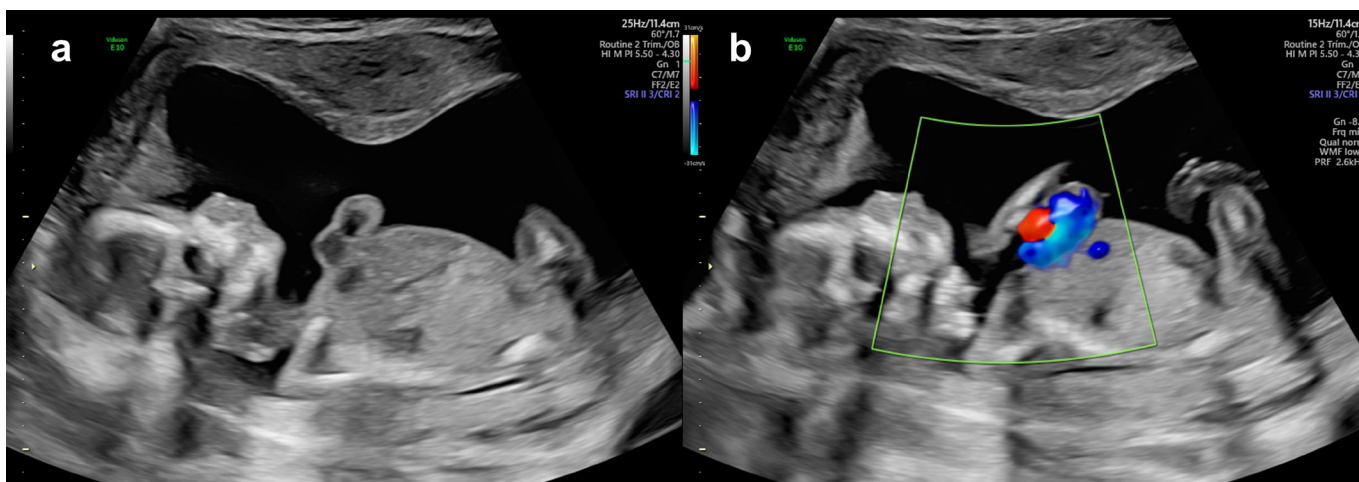


Figure 1. Prenatal ultrasound of the foetus with thoracic ectopia cordis in longitudinal section. (a) Without colour-Doppler; (b) With colour-Doppler.

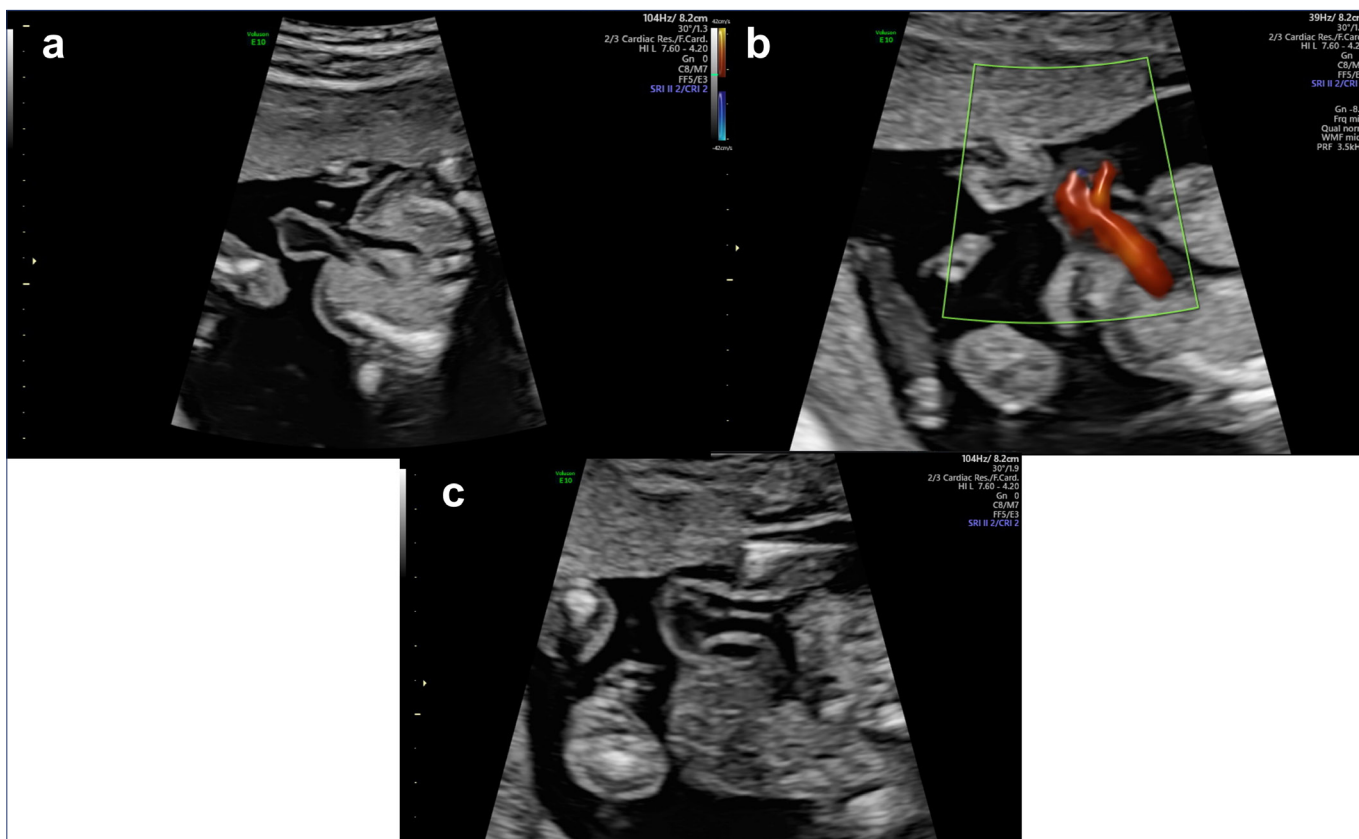


Figure 2. The heart appears to be outside the thorax at the thoracic level in transverse section. (a) Without Color Doppler; (b) With Color Doppler; (c) Left ventricular outflow.

and partial expulsion of placental material. The anatomopathological examination of the foetus and the cytogenetic analysis of the DNA of a flap of foetal skin were then performed. The macroscopic examination resulted in a female foetus weighing 148 grams. The head circumference was 13 cm, chest circumferences 12 cm, abdominal circumference 11 cm, vertex-coccyx length 13.5 cm, foot length 21 mm, forearm length 21 mm.

She showed ear cups with slightly low insertion, micrognathia and bilateral clubfoot (Figure 3). Upon examination of the individual internal organs, incomplete anterior development of the diaphragm was highlighted with consequent weakness and compression of the two lungs by abdominal organs (particularly the liver). The lungs showed alterations in their shape with inverted diameters: the right lung of 23 (base) x13 (height)

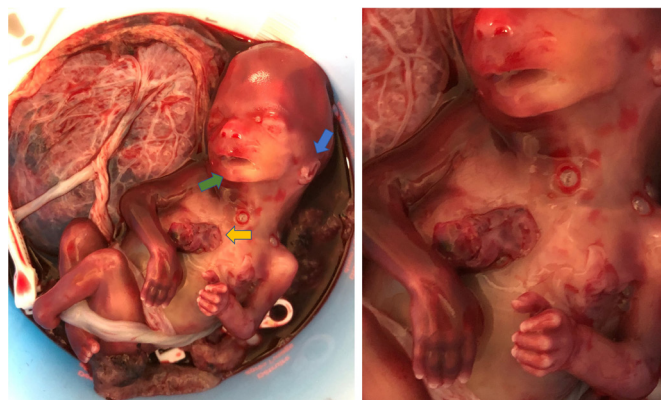

Figure 3. Isolated thoracic ectopia cordis with anterior chest wall defect (yellow arrow), ear cups with slightly low insertion (blue arrow), micrognathia (green arrow) seen after abortion.

mm, and the left lung was 21 mm (base) x11 mm (height). The ectopic heart appeared to be rotated posteriorly with consequent slight torsion of the aorta and pulmonary artery; a macroscopic examination did not reveal other malformations. A 10 mm long funnel adhered to the foetus with false knots, and a placenta with mild deciduous inflammation was observed.

Cytogenetic analysis revealed a 46, XX foetal karyotype. A-CGH of the whole foetal genome was performed. Whole genome a-CGH analysis identifies DNA copy number variations (CNVs). The OGT platform, CytoSure ISCA v2 4x180k slide, with an average resolution of 25 kb and an overall analysis resolution of approximately 100 kb on the whole genome, was employed (analysis software: Cytosure (OGT) v4.10.44; sex match). The CNVs produced by a shift in the normality value of at least four consecutive probes were examined, whose map positions refer to the Genome Reference Consortium human genome Hg19. The analysis was performed using a control pool of human genomic DNA obtained from healthy anonymous donors (Promega Human Genomic DNA, Male/Female). The analysis detected a deletion of 274.9 Kb (\pm 100 Kb) in the 19p13.3 band, containing the following genes classified in the Online Mendelian Inheritance in Man (OMIM) Data Base: TLE6, TLE2, TLE5, GNA11, GNA15, S1PR4 and NCLN.

DISCUSSION

EC can be an isolated anomaly or part of Cantrell's pentalogy. Extracardiac abnormalities usually associated with EC include facial and skeletal deformities, abdominal wall-midline defects (Cantrell pen-

talogy), and central nervous system malformations (meningocele and encephalocele) [10]. Intracardiac anomalies are frequent in the thoracoabdominal type and are usually of the conotruncal type (Fallot's tetralogy, transposition of the great vessels) [11]. Other abnormalities include patent arterial duct, hypoplastic left heart syndrome, and univentricular heart with pulmonary stenosis. The finding of cardiac anomalies, especially in isolated cases of EC, worsens the prognosis [12]. Differential diagnosis of ectopia cordis includes pentalogy of Cantrell, Beckwith-Wiedemann syndrome, amniotic band syndrome, and limb-body-wall complex [13].

EC has a poor prognosis. In fact, patients with thoracic EC have a higher mortality rate (83%). Thoraco-abdominal types appear to have better outcomes, with a survival rate of 45% after a mean follow-up of 5.6 years [14]. EC is generally severe due to frequent foetal growth restriction and high intrauterine and perinatal mortality rates. In most cases, the newborn dies a few days after birth, usually by infection, major heart failure or hypoxemia [15, 16]. Surgical treatment is accepted throughout the literature as the primary treatment option for EC. However, due to the rarity of this condition, no single best surgical approach has been accepted, and surgery has a significant mortality rate. The surgical intervention aims to provide a soft tissue covering for the heart, reduce the heart into the thoracic cavity, repair intracardiac defects, and reconstruct the chest wall [17]. If there are no other severe cardiac malformations, surgery usually allows some patients to survive into adulthood. With early diagnosis, pregnancy termination can be one option for families. If EC is diagnosed late, it needs a multidisciplinary approach and a very experienced paediatric surgeon to improve the prognosis.

EC can be associated with chromosomal anomalies, especially trisomy 18 and Turner syndrome, and genetic syndromes [18]. Previous studies have reported the association with triploidy 69, XXY [19], mosaic trisomy 16 [20] and 46, XX,17q+ [21]. Due to the higher risk of such association, analysis of the karyotype is highly recommended. Furthermore, it is well known that a-CGH should be an adjunct to antenatal care for women with abnormal ultrasound findings and a normal karyotype. Until now, in the literature we have little information on the possible association of this condition with specific genetic abnormalities, such as microdeletions or microduplications [21]. With new technological developments, the genetic analysis could help us better understand

foetal pathology's level of gravity to discover if other genetic abnormalities are associated with the one found. Knowing what could be the actual prognosis of the foetus and how many chances of survival there may be, could lead to target therapy [22, 23]. There is no evidence of a clear genetic risk of recurrence; however, with increasing knowledge of pathological deletions and duplications detectable by a-CGH and of gene-level pathological variants detectable mostly by Next Generation Sequencing (NGS), it may be possible to give an answer to diagnostic questions and offer adequate counselling for families [24]. The utility lies in selected contexts: ultrasound abnormalities with normal karyotype (detection rate 11.5%) [25], chromosomal aberration (22.2%) and supernumerary marker chromosomes (50%) [26, 27]. Various microdeletions are reported in the 19p13.3 band due to the presence of highly repetitive sequences, suggesting events mediated by long interspersed nuclear elements (LINEs) and/or short interspersed nuclear elements (SINEs) as the generators of these microdeletions [28]. Depending on the size of the deletion this will result in a specific clinical presentation. Unfortunately, there are few data on the prenatal effect of these deletions. The 19p13.3 region detected in our case is 6.9 Mb long and contains several genes. Those included in the deletion are:

- TLE2, TLE6, TLE5: Transducin-like enhancer (TLE) genes encode for members of the maternal subcortical complex (SCMC) essential for preimplantation embryonic development. Biallelic mutations of the TLE6 gene have been associated with human embryonic lethality [29]. TLE2 is associated with neurogenesis and epithelial differentiation during embryonic development [30].
- GNA11 and GNA15 genes encode for the subunit alpha 11 and subunit alpha 15 of a member of G protein family, which function as modulators or transducers in various transmembrane signaling systems. G protein subunit alpha 11 (GNA11) is related to normal craniofacial and cardiovascular development [30].
- S1PR4 gene encodes for a member of the G-coupled endothelial differentiation receptor (EDG) family, involved in cell signaling and expressed specifically in lymphoid tissue.
- NCLN (Nicalin) encodes for a protein that can perform an antagonistic function of nodal signaling and the subsequent organization of axial structures during mesodermal remodeling.

Mostly TLE2, TLE6 and GNA11 may be involved in the cardiac phenotype of the foetus. Concerning TLE genes, Tbx20-TLE interactions were validated in the mouse embryonic heart and developmental genes regulated by Tbx20: TLE binding were identified, thus confirming a primary role for a Tbx20-TLE repressor complex in embryonic heart development [31]. Mice carrying inactivating mutations of the Gaq gene (Gnaq) and the Ga11 gene (Gna11) showed some cardiac alterations. Indeed, the roles of Gaq and Ga11 in embryonic cardiomyocyte proliferation and craniofacial development have been reported [32]. In order to establish a possible transmission of the detected deletion, it would have been necessary to extend the examination to the parents, who refused the analysis of the a-CGH. Cases reported in the Decipher database that overlap this region have a pathological phenotype, raising the suspicion that this CNV may be *de novo*.

Nowadays, there are several prenatal tests available to detect chromosomal and genetic abnormalities. It is crucial for healthcare providers to have a thorough discussion with expectant parents, providing them with comprehensive, clear, and empathetic communication exploring the diagnostic opportunities and limitations of each test. This will enable them to make informed decisions. When a prenatal diagnosis is given, it creates a sense of uncertainty for parents. Healthcare providers have an exceptional opportunity to positively impact parents' perception of the information communicated to them. How the information is conveyed affects their ability to cope with the diagnosis [33].

CONCLUSIONS

This case report suggests that array-CGH analysis should be performed in all cases of foetal malformations with a normal karyotype. Indeed, there could be sub-microscopic chromosomal aberrations not visible with classical cytogenetics, nonetheless transmissible to the foetus, that may be important to know in order to advise parents on future pregnancies. In addition, discovering the same or other submicroscopic deletions or duplications by a-CGH could improve our knowledge about the genetic basis of rare congenital anomalies.

COMPLIANCE WITH ETHICAL STANDARDS

Authors' contribution

V.G.: Data curation, conceptualization, writing – original draft, writing – review & editing. M.G.: Formal analysis. S.S.: Methodology, writing – review & editing, project administration, resources. A.M.C.R.: Methodology, writing – review & editing, project administration. C.G.: Data curation. R.M.: Formal analysis, writing – review & editing. S.R.G.: Investigation, validation, writing – review & editing. S.A.: Methodology, project administration, supervision.

Funding

None.

Study registration

N/A.

Disclosure of interests

The authors declare that they have no conflict of interests.

Ethical approval

N/A.

Informed consent

Written informed consent was obtained from the patient for publication of this case report and any accompanying images.

Data sharing

All data generated or analysed during the study are included in this article.

REFERENCES

1. Kahveci B, Melekoglu R, Deger U, Demir SC. Prenatal diagnosis of a rare isolated thoracic-type ectopia cordis with complete form: a case report. *J Ultrasound*. 2022;25(2):305-8. doi: 10.1007/s40477-020-00496-1.
2. Borgers AJ, Hazebroek FW, Hess J. Left and right ventricular diverticula, ventricular septal defect and ectopia cordis in a patient with Cantrell's syndrome. *Eur J Cardiothorac Surg*. 1993;7:334-5. doi: 10.1016/1010-7940(93)90177-d.
3. Repondek-Liberska M, Janiak K, Wloch A. Fetal echocardiography in ectopia cordis. *Pediatr Cardiol*. 2000;21(3):249-52. doi: 10.1007/s002460010051.
4. Gavrilov S, Lacy E. Genetic dissection of ventral folding morphogenesis in mouse: embryonic visceral endoderm supplied BMP2 positions head and heart. *Curr Opin Genet Dev*. 2013;23(4):461-9. doi: 10.1016/j.gde.2013.04.001.
5. Diaz-Serani R, Sepulveda W. Trisomy 18 in a First-Trimester Fetus with Thoraco-Abdominal Ectopia Cordis. *Fetal Pediatr Pathol*. 2020;39(1):78-84. doi: 10.1080/15513815.2019.1629132.
6. Salman H, Shah M, Ali A, Aziz A, Vitale SG. Assessment of Relationship of Serum Neurokinin-B Level in the Pathophysiology of Pre-eclampsia: A Case-Control Study. *Adv Ther*. 2018;35(7):1114-21. doi: 10.1007/s12325-018-0723-z.
7. Vitale SG, Corrado F, Caruso S, Di Benedetto A, Giunta L, Cianci A, D'Anna R. Myo-inositol supplementation to prevent gestational diabetes in overweight non-obese women: bioelectrical impedance analysis, metabolic aspects, obstetric and neonatal outcomes - a randomized and open-label, placebo-controlled clinical trial. *Int J Food Sci Nutr*. 2021;72(5):670-9. doi: 10.1080/09637486.2020.1852191.
8. Quaresima P, Fesslova V, Farina A, Kagan KO, Candiani M, Morelli M, Crispi F, Cavoretto PI. How to do a fetal cardiac scan. *Arch Gynecol Obstet*. 2023;307(4):1269-76. doi: 10.1007/s00404-023-06951-8.
9. Mastromoro G, Guadagnolo D, Khaleghi Hashemian N, Marchionni E, Traversa A, Pizzuti A. Molecular Approaches in Fetal Malformations, Dynamic Anomalies and Soft Markers: Diagnostic Rates and Challenges-Systematic Review of the Literature and Meta-Analysis. *Diagnostics (Basel)*. 2022;12(3):575. doi: 10.3390/diagnostics12030575.
10. Gabriel A, Donnelly J, Kuc A, Good D, Doros G, Matusz P, et al. Ectopia cordis: a rare congenital anomaly. *Clin Anat*. 2014;27(8):1193-9. doi: 10.1002/ca.22402.
11. Türkyilmaz G, Avcı S, Sıvrıköz T, Ertürk E, Altunoglu U, Turkyilmaz SE, et al. Prenatal Diagnosis and Management of Ectopia Cordis: Varied Presentation Spectrum. *Fetal Pediatr Pathol*. 2019;38(2):127-37. doi: 10.1080/15513815.2018.1556367.

12. Gibbin C, Touch S, Broth RE, Berghella V. Abdominal wall defects and congenital heart disease. *Ultrasound Obstet Gynecol.* 2003;21(4):334-7.
13. Mohamed SM, Isa HM, Sandhu AK. Ectopia Cordis as a Lethal Neonatal Condition: A Case Report from Bahrain and a Literature Review. *Case Rep Pediatr.* 2022;2022:6850305. doi: 10.1155/2022/6850305.
14. Pius S, Abubakar Ibrahim H, Bello M, Bashir Tahir M. Complete Ectopia Cordis: A Case Report and Literature Review. *Case Rep Pediatr.* 2017;2017:1858621. doi: 10.1155/2017/1858621.
15. Shad J, Budhwani K, Biswas R. Thoracic ectopia cordis. *BMJ Case Rep.* 2012;2012:bcr1120115241. doi: 10.1136/bcr.11.2011.5241.
16. Vitale SG, Fiore M, La Rosa VL, Rapisarda AMC, Mazza G, Paratore M, et al. Liposomal ferric pyrophosphate and ascorbic acid supplementation in pregnant women with iron deficiency anaemia: haematochemical, obstetric, neonatal and psychological outcomes in a prospective observational study. *Int J Food Sci Nutr.* 2022;73(2):221-9. doi: 10.1080/09637486.2021.1950129.
17. Sadłecki P, Krekora M, Krasomski G, Walentowicz-Sadłecka M, Grabiec M, Moll J, et al. Prenatally evolving ectopia cordis with successful surgical treatment. *Fetal Diagn Ther.* 2011;30(1):70-2. doi: 10.1159/000326300.
18. Shaw SW, Cheng PJ, Chueh HY, Chang SD, Soong YK. Ectopia cordis in a fetus with trisomy 18. *J Clin Ultrasound.* 2006;34:95-8. doi: 10.1002/jcu.20203.
19. Sepulveda W, Weiner E, Bower S, Flack NJ, Bennett PR, Fisk NN. Ectopia cordis in a triploid fetus: first-trimester diagnosis using transvaginal color Doppler ultrasonography and chorionic villus sampling. *J Clin Ultrasound.* 1994;22(9):573-5. doi: 10.1002/jcu.1870220912.
20. Arnaoutoglou C, Meditskou S, Keivanidou A, Manthou M, Anesidis N, Assimakopoulos E, et al. Ectopia cordis in a fetus with mosaic trisomy 16. *J Clin Ultrasound.* 2010;38(7):386-8. doi: 10.1002/jcu.20727.
21. Say B, Wilsey CE. Chromosome aberration in ectopia cordis (46,XX,17q+). *Am Heart J.* 1978;95(2):274-5. doi: 10.1016/0002-8703(78)90484-2.
22. Tabacco S, Pilolli N, Di Fabio S, Polsinelli V, Lattanzi D, Paleri S, et al. Late third trimester diagnosis of a congenital haemangioma: a case report. *Ital J Gynaecol Obstet.* 2023;35(1):9. doi: 10.36129/jog.2022.S08.
23. Nardi E, Castiglione F, Di Tommaso M, Pasquini L, Seravalli V. Prenatal diagnosis of tuberous sclerosis complex: a case report. *Ital J Gynaecol Obstet.* 2023;35(1):4. doi: 10.36129/jog.2022.S03.
24. De Jong A, Dondorp WJ, Macville MV, de Die-Smulders CE, van Lith JM, de Wert GM. Microarrays as a diagnostic tool in prenatal screening strategies: ethical reflection. *Hum Genet.* 2014;133(2):163-72. doi: 10.1007/s00439-013-1365-5.
25. Lee CN, Lin SY, Lin CH, Shih JC, Lin TH, Su YN. Clinical utility of array comparative genomic hybridisation for prenatal diagnosis: a cohort study of 3171 pregnancies. *BJOG.* 2012;119(5):614-25. doi: 10.1111/j.1471-0528.2012.03279.x.
26. Novelli A, Grati FR, Ballarati L, Bernardini L, Bizzoco D, Camurri L, et al. Microarray application in prenatal diagnosis: a position statement from the cytogenetics working group of the Italian Society of Human Genetics (SIGU), November 2011. *Ultrasound Obstet Gynecol.* 2012;39(4):384-8. doi: 10.1002/uog.11092.
27. Vetro A, Bouman K, Hastings R, McMullan DJ, Vermeesch JR, Miller K, et al. The introduction of arrays in prenatal diagnosis: a special challenge. *Hum Mutat.* 2012;33:923-9. doi: 10.1002/humu.22050.
28. Peddibhotla S, Khalifa M, Probst FJ, Stein J, Harris LL, Kearney DL, et al. Expanding the genotype-phenotype correlation in subtelomeric 19p13.3 microdeletions using high resolution clinical chromosomal microarray analysis. *Am J Med Genet A.* 2013;161A(12):2953-63. doi: 10.1002/ajmg.a.35886.
29. Jing L, Hua X, Biaobang C, Wenjing W, Lei W, Xiaoxi S, et al. Expanding the genetic and phenotypic spectrum of female infertility caused by TLE6 mutations. *J Assist Reprod Genet.* 2020;37(2):437-42. doi: 10.1007/s10815-019-01653-0.
30. Al-Kateb H, Hahn A, Gastier-Foster JM, Jeng L, McCandless SE, Curtis CA. Molecular characterization of a novel, de novo, cryptic interstitial deletion on 19p13.3 in a child with a cutis aplasia and multiple congenital anomalies. *Am J Med Genet A.* 2010;152A:3148-53. doi: 10.1002/ajmg.a.33738.
31. Kaltenbrun E, Greco TM, Slagle CE, Kennedy LM, Li T, Cristea IM, et al. A Gro/TLE-NuRD corepressor complex facilitates Tbx20-dependent transcriptional repression. *J Proteome Res.* 2013;12(12):5395-409. doi: 10.1021/pr400818c.

32. Offermanns S, Zhao LP, Gohla A, Sarosi I, Simon MI, Wilkie TM. Embryonic cardiomyocyte hypoplasia and craniofacial defects in G alpha q/G alpha 11-mutant mice. *EMBO J.* 1998;17(15):4304-12. doi: 10.1093/emboj/17.15.4304.
33. Quaresima P, Visconti F, Greco E, Venturella R, Di Carlo C. Prenatal tests for chromosomal abnormalities detection (PTCAD): pregnant women's knowledge in an Italian Population. *Arch Gynecol Obstet.* 2021;303(5):1185-90. doi: 10.1007/s00404-020-05846-2.