



# Italian Journal of Gynæcology & Obstetrics

September 2024 - Vol. 36 - N. 3 - Quarterly - ISSN 2385 – 0868

## Transvaginal *versus* transumbilical laparoscopic single-site surgery for management of benign adnexal masses: a comparative study

Ahmed Elmaasrawy<sup>1</sup>, Mohammed Barakat<sup>1</sup>, Mohamed A. Wasfy<sup>1</sup>, Mohamed Negm<sup>2</sup>, Mohamed Mahmoud Almenyawy<sup>2</sup>, Loay M. Gertallah<sup>2</sup>, Mariem A. Elfeky<sup>3</sup>, Ola A. Harb<sup>3\*</sup>, Mai Mostafa Zaitoun<sup>1</sup>

<sup>1</sup> Department of Gynecology and Obstetrics, Faculty of Medicine, Zagazig University, Zagazig, Egypt.

<sup>2</sup> Department of General Surgery, Faculty of Medicine, Zagazig University, Zagazig, Egypt.

<sup>3</sup> Department of Pathology, Zagazig University Faculty of Medicine, Zagazig University, Zagazig, Egypt.

### ARTICLE INFO

#### History

Received: 22 June 2023

Received in revised form: 11 September 2023

Accepted: 28 September 2023

Available online: 20 September 2024

DOI: 10.36129/jog.2023.145

#### Key words

Adnexal masses; TV-LESS; TU-LESS.

\*Corresponding author: Ola A. Harb, Professor, M.D., PhD. Department of Pathology, Faculty of Medicine, Zagazig University, Tolba Street, Zagazig, Egypt.  
Email: olaharb2015@gmail.com.  
ORCID: 0000-0002-4396-3101.

### ABSTRACT

**Objective.** Transvaginal laparoendoscopic single-site surgery (TV-LESS) was recently suggested as a less invasive approach than conventional laparoscopic approaches.

The aim of our study was to compare between TU-LESS and TV-LESS in specimen extraction in patients with benign adnexal masses who underwent minimally invasive surgery as regard safety and feasibility of the procedures, operative findings and post-operative outcomes.

**Patients and Methods.** Prospective analysis of collected data of 100 patients that underwent TU-LESS and TV-LESS salpingo-oophorectomy, oophorectomy or ovarian cystectomy at Gynecology and obstetrics department, Zagazig University hospitals from January 1, 2020 to January 30, 2023. We randomly divided included patients in to 2 groups according performed surgical approach. The TU group included 50 patients who underwent extraction of the excised specimen through the umbilicus. The TV group included 50 patients who underwent extraction of the excised specimen through the vagina.

**Results.** There is statistically significant relation between approach used and all of ovarian volume, operative time, intraoperative bleeding, return to bowel function, ambulation time (all are significantly higher in TU-LESS), postoperative 12-hour VAS cosmetic score (significantly lower in TU-LESS) and postoperative analgesic ampoules (significantly higher in TU-LESS). There is statistically non-significant relation between approach and any of studied parameters.

Specimen extraction in TV-LESS group caused less postoperative pain than the TU-LESS group.

The overall cosmetic satisfaction was higher in TV-LESS group when compared with the TU-LESS group 3 months after the surgery ( $p = 0.02$ ).

**Conclusions.** We showed that performing TV-LESS has major advantages over TU-LESS: 1) lower incidence of postoperative complications as umbilical hernia; 2) lower incidence of postoperative pain; 3) earlier bowel functions return and shorter time of hospital stay; and 4) higher cosmetic appearance.

## INTRODUCTION

Benign ovarian cysts are common gynaecological conditions that have high prevalence among all age groups. Recently, using minimally invasive surgical procedures are preferred by most patients and surgeons [1, 2].

Endometriotic ovarian cysts can be safely managed by laparoscopy [3].

The laparoscopic approach has significant complications, mainly due to complexity of the surgery, *e.g.*, vascular and gastrointestinal injuries and lesions of the urinary system [4].

Transumbilical laparoscopic single-site surgery (TU-LESS) was found to be a preferred management technique for ovarian cysts excision [1, 2]. Such approach requires enlargement of the abdominal wall incision to allow extraction of the specimen, but it increase incidence of postoperative complications occurrence as incisional hernias, pain, wound infections in addition to decreasing the cosmetic satisfaction of patients [5]. Transvaginal laparoendoscopic single-site surgery (TV-LESS) was recently suggested as a promising less invasive approach that has accepted cosmetic results and less complications than conventional laparoscopic approaches [6], this is mostly due to using the vagina as a human body natural orifice in specimen extraction [7].

Previous studies demonstrated that TV-LESS is considered a safe and feasible surgical approach for specimen extraction in adenectomy and hysterectomy, but there is a need for performing more prospective studies on large number of patients to assess its advantages [8].

Fascia closure and increased surgical time were significantly associated with immediate postoperative pain and the need for strong opioids consumption. Surgical training trying to decrease surgical manipulations should be emphasized to decrease postoperative pain [9].

Aim of our study was to compare between TU-LESS and TV-LESS in specimen extraction in patients with benign adnexal masses who underwent minimally invasive surgery as regard safety and feasibility of the procedures, operative findings and post-operative outcomes.

## PATIENTS AND METHODS

Prospective analysis of collected data of 100 patients that underwent TU-LESS and TV-LESS salp-

ingo-oophrectomy, oophorectomy or ovarian cystectomy at Gynecology and obstetrics department, Zagazig University hospitals from January 1, 2020 to January 30, 2023 after taking approval from the local institutional review board in Faculty of Medicine Zagazig University (IRB approval number is 10486-16-4-202022) and written informed consent from all included patients. We randomly divided included patients in to 2 groups according performed surgical approach: TV-LESS and TU-LESS by computer generated randomization. The TU group included 50 patients who underwent extraction of the excised specimen through the umbilicus. The TV group included 50 patients who underwent extraction of the excised specimen through the vagina.

Inclusion criteria for TV-LESS patients were: 1) pre-operative clinical and radiological diagnosis of benign adnexal masses; 2) history of normal vaginal delivery; 3) clinical evidence of good uterine motility; 4) contraindication of transumbilical surgery as past history of repairing umbilical hernia; 5) no contraindications to surgery or anaesthesia.

Inclusion criteria for TU-LESS patients were: 1) pre-operative clinical and radiological diagnosis of benign adnexal masses; 2) past history of weakness, hypertrophy or any dysfunction in the pelvic floor which might lead to narrowing of vaginal introitus; 3) virginity; 4) no surgical or anaesthesia contraindications.

Exclusion criteria for all patients who underwent either TV-LESS or TU-LESS were: 1) clinical and radiological evidence of obliteration of cul-de-sac; 2) past history of surgical intervention in the bowel; 3) past history of conversion from laparoscopic to open surgery; 4) pre-operative clinical and radiological diagnosis of malignant adnexal masses (ascites or clinical evidence of metastatic disease); 5) indications for a concomitant total abdominal or laparoscopic hysterectomy; 6) intraoperative diagnosis of any intra-abdominal malignancy; 7) presence of deep infiltrative endometriosis. We excluded patients with past history of umbilical hernia repair, as hernia repair associated with mesh insertion which will lead to bias in results.

We recorded patient's age, body mass index (BMI), size and location of the adnexal mass, obstetric history, operative duration, intra-operative blood loss and needs for analgesia.

The primary evaluated outcome findings were post-operative pain, cosmetic results and overall patients' satisfaction rate. The secondary evaluated outcome

findings were blood loss and operative duration. Pre-operative sonographic evaluation of size and morphology of the adnexal masses were detected.

We have not determined an upper size limit for the adnexal masses that we could laparoscopically extract it. We have performed either ovarian cystectomy or unilateral salpingo-oophorectomy according to clinical and radiological findings in the mass and age of the patient.

We defined additional operative duration as time from performing posterior fornix incision and specimen extraction to closure of colpotomy for TV-LESS patients.

We defined additional operative duration as time from performing abdominal ancillary port site enlargement and specimen extraction to closure of the incision for TU-LESS patients.

### *Performed surgical procedures*

Patients in both included groups of patients received similar pre-operative and postoperative measures. The only difference between both groups is site of entrance: the vagina in patients who underwent TV-LESS and umbilicus in patients who underwent TU-LESS.

Pre-operative bowel preparation we give patients a liquid diet twenty-four hours before surgical intervention and 200 ml carbohydrate rich drinks four hours before surgery and 150 ml water was given orally two hours before surgery. We used iodophor solution for vagina and perineal area sterilization and prophylaxis IV Ceftriaxone sodium 1.5 g was given half an hour before surgery.

General anaesthesia was given to all patients then patients were placed in a dorsal lithotomy position. We sterilized perineum, vagina, and cervix and placed a Foley catheter to drain urine.

### *Surgical entrance in TV-LESS patients*

We placed a vaginal retractor inside the vagina for visualization of the cervix. We grasped the posterior cervical lip using an Allis forceps, and pulled superiorly for exposure of the vaginal vault posteriorly. We identified site of incision on the posterior vaginal fornix then using two Allis clamps for space demarcation. We made an incision 2-3 cm using tissue scissors horizontally to allow pelvic cavity entry. We placed a sterile port to perform pneumoperitoneum. We performed complete examination of the upper abdomen and both ovaries.

### *Surgical entrance in TU-LESS patients*

We performed similar procedure for the TU-LESS group, except for performing a vertical incision about 3 cm that was made at umbilicus base.

For all patients included in both groups we performed ovarian cystectomy, oophorectomy or salpingo-oophorectomy according to the detected pathology.

Vaginal and Umbilical Incisions Closure are used for both TV-LESS and TU-LESS respectively.

We directly removed excised tissues through the trocar or through retrieval bag for larger specimens. We used 2-0 absorbable suture for continuous suturing the vaginal or umbilical incisions according to performed procedure.

Sexual activity was allowed after 6 to 8 weeks.

### *Postoperative evaluation*

Intramuscular 75-mg diclofenac sodium ampoules every eight hours were used for management of postoperative pain with a maximum of 3 doses.

Evaluation of incisional pain severity was done by using a VAS, where we graded the responses from zero (no pain) to ten (severe pain), at six and twenty-four hours after the surgery.

We followed patients 3 months after the surgery, to assess the overall satisfaction, surgical procedures and cosmetic scars appearance using a separate VAS at the follow-up visits.

Postoperative follow-up of patients in outpatient clinics was performed at one and four weeks.

We performed general screening, imaging examination, evaluated both included groups of patients for abnormal vaginal discharge, complications of the incision, abdomino-pelvic haematomas, and infections. We contacted all patients after 24 weeks from surgery via telephone for evaluating symptoms of dyspareunia.

### *Statistical analysis*

We performed statistical analysis using IBM SPSS Statistics for Windows software (version 15.0; IBM Corp.). We used mean, median, standard deviation, lowest and highest frequencies and ratios as the complimentary data. We applied parametric tests to the data with a normal distribution, and applied nonparametric tests to the data with a non-normal distribution.

**Table 1.** Comparison between surgical approach and the studied parameters.

	Approach		$\chi^2$	P-value
	TU-LESS	TV-LESS		
Parity				
P0	3 (6%)	2 (4%)	0.683 <sup>§</sup>	0.409
P1	11 (22%)	9 (18%)		
P2	10 (20%)	10 (20%)		
P3	15 (30%)	15 (30%)		
P4-7	11 (22%)	14 (28%)		
Mode of delivery				
NVD	17 (37%)	17 (35.4%)	0.024	0.877
CS	29 (63%)	31 (64.6%)		
Previous abdominal surgery	20 (40%)	20 (40%)	0	> 0.999
Previous pelvis surgery	22 (44%)	18 (36)	0.667	0.414
Mass				
Cystic	16 (32%)	13 (26%)	1.173	0.556
Solid	20 (40%)	18 (36%)		
Mixed	14 (28%)	19 (38%)		
Histopathology				
Endometriosis	8 (16%)	11 (22%)	1.175	0.882
Functional cyst	5 (10%)	3 (6%)		
Mucinous cyst	13 (26%)	13 (26%)		
Serous cyst	14 (28%)	12 (24%)		
Teratoma	10 (20%)	11 (22%)		
Surgery				
Ovarian cystectomy	40 (80%)	34 (68%)	2.736	0.255
Oophorectomy	5 (10%)	5 (10%)		
Salpingectomy	5 (10%)	11 (22%)		
	Mean ± SD	Mean ± SD	t	P-value
Age (year)	33.86 ± 4.53	33.16 ± 5.81	0.672	0.503
BMI (kg/m <sup>2</sup> )	23.18 ± 2.74	24.98 ± 7.08	-1.676	0.098
Ovarian volume (cm <sup>3</sup> )	7.49 ± 1.66	5.93 ± 1.34	5.179	<0.001**
Operative time (min)	14.66 ± 3.06	12.06 ± 1.57	5.344	<0.001**
Intraoperative bleeding (ml)	19.62 ± 2.86	17.68 ± 3.54	3.015	0.003*
Return of bowel function (h)	16.32 ± 1.38	11.86 ± 2.43	11.282	<0.001**
Ambulation time (h)	17.18 ± 1.42	9.84 ± 0.93	30.478	<0.001**
Postoperative 12-hour VAS cosmetic score	7.22 ± 1.2	10.08 ± 0.8	-13.999	<0.001**
	Median (IQR)	Median (IQR)	Z	P-value
Postoperative analgesic use (ampoule)	7(5 – 8)	4(4 – 5)	9.844	<0.001**

<sup>§</sup>Chi square for trend test;  $\chi^2$ : Chi square test; t independent sample t test; \*p < 0.05 is statistically significant; \*\*p ≤ 0.001 is statistically highly significant; IQR interquartile range; Z: Mann Whitney test.

We used the frequencies with percentages and medians with ranges to describe categorical variables, we used chi-squared tests to compare counts of

categorical data. Values ≤ 0.05 were considered statistically significant.

## RESULTS

We included 100 patients with pre-operative clinical and radiological evidences of benign adnexal masses and underwent either TU-LESS or TV-LESS.

Age ranged from 22 to 48 years with mean 34.29 years. BMI ranged from 17 to 25.5 kg/m<sup>2</sup> with mean 21.51 kg/m<sup>2</sup>. 30% of patients were para 3. Solid mass occurred in 38% and histopathology revealed that 26%, 26%, 21% and 19% had mucinous cyst, serous cyst, teratoma and endometriosis, respectively. Seventy-four patients underwent ovarian cystectomy. operative time ranged from 9 to 20 minutes with mean 13.36 minutes and mean ambulation time was 13.51 hours. Postoperative 12-hour VAS cosmetic score ranged from 5 to 11. Postoperative analgesic ampoules ranged from 3 to 9 ampoules (Table 1).

We found no statistically significant differences between the two included groups regarding past history of previous pelvic surgery, BMI, size of the adnexal masses or incidence of operative complications.

All included 100 patients had postoperative pathological diagnosis of benign adnexal masses.

In the TV-LESS patients, 35 cases underwent ovarian cystectomy, 5 cases underwent oophorectomy and 10 cases of salpingo-oophorectomy. In the TU-LESS group, there were 40 cases of ovarian cystectomy, 5 cases of oophorectomy and 5 cases underwent salpingo- oophorectomy.

### Operative findings

There is statistically significant relation between approach used and all of ovarian volume, operative time, intraoperative bleeding, return to bowel function, ambulation time (all are significantly higher in TU-LESS), postoperative 12-hour VAS cosmetic score (significantly lower in TU-LESS) and postoperative analgesic ampoules (significantly higher in TU-LESS) (Figure 1).

There is statistically non-significant relation between approach and any of studied parameters.

### Postoperative findings (Table 2)

We found no peri-operative or post-operative complications or conversion to laparotomy occurred in any patients of both groups.



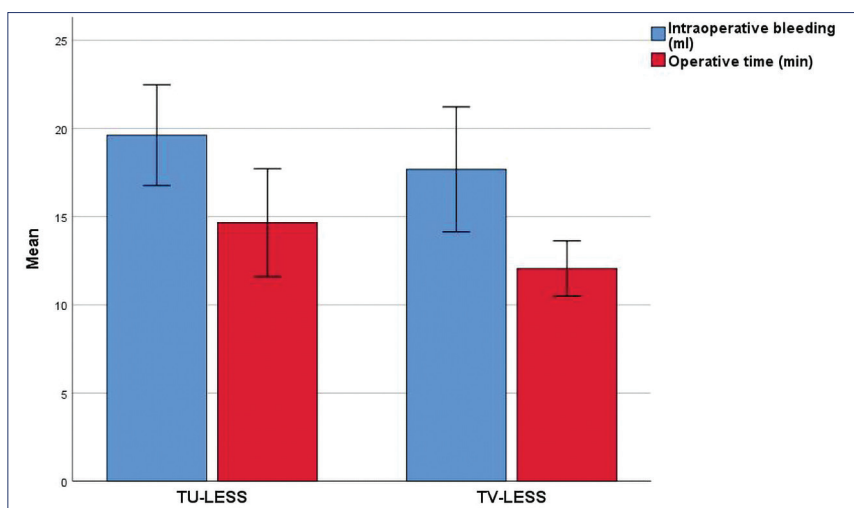


Figure 1. Multiple bar charts showing relation between approach used and both operative time and intraoperative bleeding.

Reduction in the incidence of umbilical hernia among TV-LESS group was demonstrated.

After follow-up period of 6 months, we found no abnormal vaginal discharge or abdominal or pelvic pain in patients who underwent TV-LESS, and all included patients have an accepted healing of the posterior incision in the vaginal fornix.

The patients reported no sexual pain or discomfort during follow-up period.

Specimen extraction in TV-LESS group caused less postoperative pain than the TU-LESS group.

Table 2. Partial correlation between postoperative analgesic use and studied parameters.

	r	P-value
Operative time	0.117	0.249
Ovarian volume	-0.091	0.369
Intraoperative bleeding	-0.008	0.934
Ambulation time	-0.003	0.978
Time to return to bowel habits	0.086	0.397

r: Spearman rank correlation coefficient.

Table 3. Partial correlation between postoperative VAS cosmetic score and studied parameters.

	r	P-value
Operative time	0.117	0.249
Ovarian volume	0.136	0.179
Intraoperative bleeding	0.085	0.401
Ambulation time	-0.16	0.113
Time to return to bowel habits	0.086	0.397

r: Spearman rank correlation coefficient.

The overall cosmetic satisfaction was higher in TV-LESS group, when compared with the TU-LESS group, 3 months after the surgery (p = 0.02). We found no significant differences in costs between the groups.

After controlling approach used, there is statistically non-significant correlation between number of post-operative analgesic ampoules used and all of ovarian time, intraoperative bleeding, ovarian volume, time to return of bowel habits and ambulation time. After controlling approach used, there is statistically non-significant correlation between VAS cosmetic score and all of ovarian time, intraoperative bleeding, ovarian volume, time to return of bowel habits and ambulation time (Table 3).

## DISCUSSION

With improvements in laparoscopically assisted gynaecological surgical procedures and technologies, a single port laparoscopic surgery was found to have many advantages over conventional laparoscopic surgery as performing a single incision, less trauma to the tissue, better cosmetic appearance of the surgical scar and easy removal of the resected specimen [1].

The vagina as a natural orifice vagina was found to be used as a surgical entrance, without the need to perform an incision in the abdominal wall [9].

Using TV-LESS for surgical adnexal masses excision is still evaluated for its safety and efficacy with a need for improved surgical instruments [10].

There are previously performed studies using TV-LESS for ovarian cysts excision and shows their benefits [6-8, 10, 12]. In the present study we eval-

uated the benefits of TV-LESS and showed its advantages, safety and feasibility over TU-LESS and found similar findings to results of Zhang *et al.* [1]. Who compared between both TU-LESS and TV-LESS and showed several advantages of TV-LESS as faster recovery and return of bowel function, shorter hospital staying time, less pain and better cosmesis. Moreover, we showed similar results to Zhang *et al.* [1], who showed that TV-LESS reduced incisional hernia incidence and in the follow-up periods no post-operative complications were detected.

Nearly similar findings were demonstrated by Soyman *et al.* [5]: laparoscopic adnexal masses extraction through vaginal incision has better cosmetic appearance and has less pain than TU-LESS, as transvaginal incision was performed without abdominal incision and the vaginal visceral nerves are less sensitive than abdominal wall nerves.

Moreover, we recorded in dyspareunia in the TV-LESS cases similar to findings by Ghezzi *et al.* and Uccella *et al.* [13, 14].

Additionally, TV-LESS was formerly found to be associated with less postoperative pain in comparison with both TU-LESS and multiport methods [10, 15, 16].

The suspected disadvantage of TV-LESS that high incidence of infections due to incision in the posterior fornix with higher time of exposure of the abdominal cavity with possible contamination by vaginal normal flora in the laparoscopic operations was abolished by performing positive pressure between the vagina and peritoneal cavity due to the pneumoperitoneum [5].

## CONCLUSIONS

We showed that performing TV-LESS and TU-LESS for excision of adnexal masses are both effective and safe with nearly similar operative time and per-operative blood loss. But, TV-LESS has major advantages over TU-LESS: 1) lower incidence of postoperative complications; 2) lower incidence of postoperative pain; 3) earlier bowel functions return, and shorter time of hospital stay; and 4) higher cosmetic appearance.

### *Points of strength*

The point of research is beneficial to the patients due to high incidence of adnexal masses.

The prospective comparative nature of the study allows better data collection and results analysis which lead to generalization of findings.

### *Points of weakness and limitations*

The relatively small patients' number in a single institute makes it possible that findings may not be widely applicable.

Choosing two different inclusion criteria for each group a priori may generate selection bias, it would have been appropriate to identify inclusion criteria valid for both groups, as well as unique exclusion criteria. Dyspareunia was evaluated by a telephone interview; it would be better using a proper questionnaire in order to obtain better data (FSFI p.e.).

### *Recommendations*

We recommend performing a multicentre, prospective, large-sample studies which compared TV-LESS with TU-LESS aiming at providing more favourable evidence for adequate management in the future.

TV LESS looks as a promising technique in specified setting in terms of pain and scarless surgery if compared with traditional transabdominal LESS surgery, more well-designed studies are needed to confirm this idea.

## COMPLIANCE WITH ETHICAL STANDARDS

### *Authors' contribution*

All authors contributed equally to this work.

### *Fundings*

None.

### *Study registration*

Local institutional review board of Faculty of Medicine, Zagazig University (Zag-2024, 3426).

### *Disclosure of interests*

The authors declare that they have no conflict of interests.

### *Ethical approval*

Faculty of Medicine Zagazig university (IRB approval number: 10486-16-4-202022).

### Informed consent

From all included patient is included.

### Data sharing

Data are available under reasonable request to the corresponding author.

### REFERENCES

- Zhang CH, Duan K, Fang F, Wu L, Xu Q, Delgado S, et al. Comparison of Transvaginal and Transumbilical Laparoscopic Single-Site Surgery for Ovarian Cysts. *JLSLS*. 2021;25(2):e2021.00019. doi: 10.4293/JLSLS.2021.00019.
- Wang X. Single hole laparoscopic cystectomy for giant ovarian cyst. *Mod Onc*. 2019;27(24):4416-20. doi: 10.3389/fonc.2021.796330.
- Cetin I, Danese S, De Vita D, Franchi MP, Guido M, Mattei A, et al. Topical haemostatics and sealants in gynaecological and obstetric surgery: state of the art. *Ital J Gynaecol Obstet*. 2022;34(3):138-53. doi: 10.36129/jog.2022.44.
- Abdou AM, Fahmy AM, Harb O, Abdel-Razik AE. Predictive risk factors for occurrence of tubo-ovarian abscess in patients with ovarian endometriosis: a prospective comparative study. *Ital J Gynaecol Obstet*. 2023;35(2):196-203. doi: 10.36129/jog.2022.57.
- Soyman Z, Kelekci S, Aydogmus Z, Demirel E, Ekmekci E. Transabdominal versus transvaginal specimen extraction in mini-laparoscopic surgery. *J Obstet Gynaecol Res*. 2019;45(12):2400-6. doi: 10.1111/jog.14134.
- Zhu Y. Clinical analysis of ten cases of transvaginal endoscopic ovarian cyst removal. *Chin J Endosc Surg*. 2018;1(11):600-8. doi: 10.4293/JLSLS.2021.00019.
- Zou X, Zhang G, Xie T, Yuan Y, Xiao R, Wu G, et al. Natural orifice transluminal endoscopic surgery in urology: the Chinese experience. *Asian J Urol*. 2020;7(1):1-9. doi: 10.1016/j.ajur.2019.07.001.
- Chen X, Liu H, Sun D, Zhang J, Fan Q, Shi H, et al. Transvaginal natural orifice transluminal endoscopic surgery for tubal pregnancy and a device innovation from our institution. *J Minim Invasive Gynecol*. 2019;26(1):169-74. doi: 10.1016/j.jmig.2018.05.013.
- Buzzaccarini G, Török P, Vitagliano A, Petousis S, Noventa M, Hortu I, et al. Predictors of Pain Development after Laparoscopic Adnexectomy: A Still Open Challenge. *J Invest Surg*. 2022;35(6):1392-3. doi: 10.1080/08941939.2022.2056274.
- Akamatsu H, Omori T, Oyama T, Luo F, Guo F. Totally laparoscopic sigmoid colectomy: a simple and safe technique for intracorporeal anastomosis. *Surg Endosc*. 2009;23(11):2605-9. doi: 10.1007/s00464-009-0406-6.
- Yang YS, Kim SY, Hur MH, Oh KY. Natural orifice transluminal endoscopic surgery-assisted versus single-port laparoscopic assisted vaginal hysterectomy: a case-matched study. *J Minim Invasive Gynecol*. 2014;21(4):624-31. doi: 10.1016/j.jmig.2014.01.005.
- Yang E, Nie D, Li Z. Comparison of major clinical outcomes between transvaginal and traditional laparoscopic surgery: asystematic review and meta-analysis. *J Surg Res*. 2019;244:278-90. doi: 10.1016/j.jss.2019.06.012.
- Ghezzi F, Casarin J, De Francesco G, Puggina, S Uccella, M Serati, et al. Transvaginal contained tissue extraction after laparoscopic myomectomy: A cohort study. *BJOG*. 2018;125:367-73. doi: 10.1111/1471-0528.14720.
- Uccella S, Cromi A, Bogani G, Casarin J, Serati M, Ghezzi F. Transvaginal specimen extraction at laparoscopy without concomitant hysterectomy: Our experience and systematic review of the literature. *J Minim Invasive Gynecol*. 2013;20:583-90. doi: 10.1016/j.jmig.2013.02.022.
- Lee CL, Wu KY, Su H, Wu PJ, Han CM, Yen CF. Hysterectomy by transvaginal natural orifice transluminal endoscopic surgery (NOTES): a series of 137 patients. *J Minim Invasive Gynecol*. 2014;21(5):818-24. doi: 10.1016/j.jmig.2014.03.011.
- Kliethermes C, Blazek K, Ali K, Nijjar JB, Kliethermes S, Guan X. Postoperative pain after single-site versus multiport hysterectomy. *JLSLS*. 2017;21(4):e2017.00065. doi: 10.4293/JLSLS.2017.00065.