



Italian Journal of Gynæcology & Obstetrics

June 2024 - Vol. 36 - N. 2 - Quarterly - ISSN 2385 – 0868

The dual danger of pyometra and endometrial carcinoma: a case report

Dayang Corieza Febriany^{1,*}, Mohamed Arif Hameed Sultan², Zubair Ahmad Sharifuddin³, Anand Raj Thangavelu³, Cindy Chin¹

¹Department of Radiology, Faculty of Medicine and Health Sciences, Universiti Malaysia Sabah, Sabah, Malaysia.

²Department of Surgery, Faculty of Medicine and Health Sciences, Universiti Malaysia Sabah, Sabah, Malaysia.

³Department of Radiology, Hospital Queen Elizabeth I, Sabah, Malaysia.

ARTICLE INFO

History

Received: 14 February 2023

Received in revised form: 01 March 2023

Accepted: 05 May 2023

Available online: 03 June 2024

DOI: 10.36129/jog.2023.121

Key words

Pyometra; uterine perforation; endometrial carcinoma; acute abdomen; hysterectomy.

*Corresponding author: Dayang Corieza Febriany, M.D. Department of Radiology, Faculty of Medicine and Health Sciences, Universiti Malaysia Sabah, Jalan UMS, 88400 Kota Kinabalu, Sabah, Malaysia.
Email: corieza@ums.edu.my.
ORCID: 0000-0002-1064-9044.

ABSTRACT

Background. Pyometra, a collection of purulent material within the endometrial cavity, is a relatively uncommon gynaecological condition. Spontaneous perforation of the uterus is an infrequent complication of pyometra, most often the result of malignant conditions in the uterus.

Case presentation. We report the case of an elderly woman who had acute abdominal pain due to a ruptured uterus secondary to pyometra resulting from an infected endometrial mass diagnosed on computed tomography. She underwent an urgent exploratory laparotomy, and a total hysterectomy and bilateral salpingo-oophorectomy were performed. Her CA-125 level was raised (102.3 U/ml) and the histopathological examination (HPE) of the endometrial mass confirmed an endometrial carcinoma. The rest of the HPE shows necrotic and inflamed perforated uterus and pyometra. No organism growth was detected in both endometrial or peritoneal pus cultures. Post-operatively, she received intravenous antibiotics and gradually recovered and discharge well.

Conclusions. When an elderly post-menopausal patient presented with an acute abdomen, the possibility of a ruptured uterine perforation secondary to pyometra needs to be considered and the cause of this condition needs to be further investigated.

INTRODUCTION

Pyometra is a condition in which purulent material accumulates in the endometrial cavity, commonly secondary to bacterial infection due to insufficient drainage of endometrial secretions via the cervix [1]. It is a relatively uncommon gynaecological entity but can lead to serious complications, including spontaneous perforation of the uterus.

Pyometra should always be considered in post-menopausal patients with fever, abdominal pain and vaginal discharge [2]. An additional finding of an enlarged uterus raises suspicion of associated malignancy, most commonly cervical cancer. Other malignancy associated with this condition includes sigmoid or rectal cancer, uterine leiomyosarcoma and endometrial cancer [3, 4].

This case report describes the clinical presentation, diagnostic findings, and outcome of an elderly

woman with endometrial malignancy and pyometra complicated with uterine perforation. This patient had multiple underlying medical conditions, including diabetes mellitus and stroke, which limits her physical activity, both predisposing factors for the development of pyometra [5]. Despite being a rare occurrence, this case highlights the importance of considering pyometra in the differential diagnosis of an acute abdominopelvic emergency, particularly in elderly post-menopausal women [6]. In addition, the coexistence of endometrial carcinoma in this case underscores the need for prompt and thorough evaluation and management of the acute gynaecological condition. This case report aims to increase awareness of this uncommon but potentially life-threatening condition among healthcare providers and emphasize the importance of early diagnosis and intervention.

CASE PRESENTATION

A 67-year-old woman who had been residing in a nursing home was brought to the Emergency Department for abdominal pain. She has underlying Diabetes Mellitus and stroke 10 years ago with residual right hemiplegia. She had been bedridden due to her hemiplegic state and muscle atrophy. On examination, she looked acutely ill. Her temperature was 37.9 °C, pulse rate was 98 beats per minute and blood pressure was 110/70 mmHg.

Her abdomen was distended and guarded, and a pelvis mass was palpable.

The results of the laboratory studies on admission were as follows: white blood cell count: $40.78 \times 10^3/\mu\text{L}$, haemoglobin: 7.9 g/dl, albumin: 23 g/dl and C-reactive protein level of 209 mg/dl. Her urine dipstick test detects positive protein, blood and nitrates.

Contrast-enhanced computed tomography (CECT) of the abdomen and pelvis (**Figure 1**) revealed an enlarged uterus with expansion of endometrial and cervical cavity with complex fluid raising suspicion of pyometra complicated with uterine fundal wall rupture, rim enhancing pelvic collections, complex ascites and peritonitis. An irregular lobulated endometrial soft tissue attenuation was seen at the posterior uterine neck-cervical junction with parametrial and serosal invasion compatible with a neoplasm. No pneumoperitoneum.

An urgent exploratory laparotomy was done, and a total hysterectomy and bilateral salpingo-oophorectomy were carried out. About 2,800 ml of pus was found in the peritoneal cavity. The uterus was distended, fragile, entirely necrotic and with a wall defect at the anterior surface of the fundus measuring 2.4 cm in diameter. Pus was draining from the perforated uterine wall into the peritoneal cavity.

Her CA-125 level was raised (102.3 U/ml) and the histopathological examination (HPE) of the endometrial mass confirmed an endometrial carcinoma.

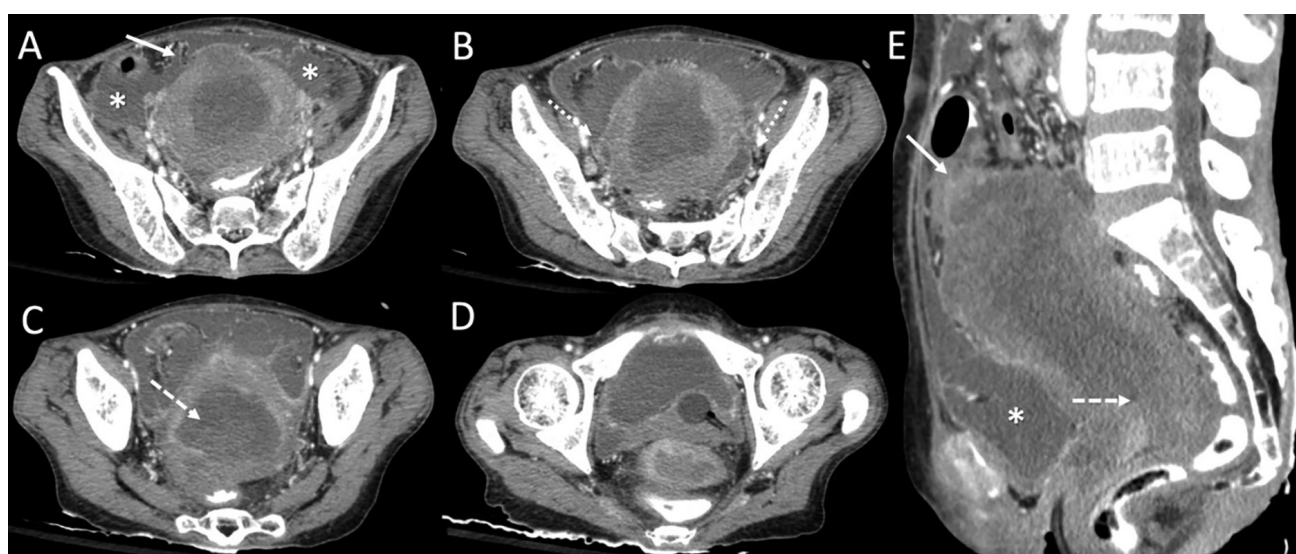


Figure 1. Contrast-enhanced computed tomography (CECT) pelvis in axial projections craniocaudally (A-D) and sagittal reformatted projection (E) showing gross ascites (*) and an enlarged uterus with heterogenous fluid-filled expansion of the endometrial cavity and cervical canal indicative of pyometra.

(A, E) Perforation at the uterine fundus (solid arrow); (B) Pelvic lymphadenopathy with rim-enhancing pelvic collections (dotted arrow) and enhancing peritoneal lining suggestive of peritonitis; (C, E) Endometrial soft tissue mass (dashed arrow) with myometrial and serosal extension to the right posterior wall of uterine neck-cervical junction; (D) Fluid-filled and expanded cervical canal.

The rest of the HPE shows necrotic and inflamed perforated uterus and pyometra. No organism growth was detected in both endometrial or peritoneal pus cultures. Postoperatively, the patient received intravenous antibiotics and supportive treatment. She gradually recovered and was discharged on postoperative day 62.

DISCUSSION

Between 0.01% and 0.5% of all gynaecological admissions and 13.6% of geriatric gynaecologic outpatients were diagnosed with pyometra [5, 6]. Patients with spontaneous uterine perforation resulting from pyometra have a mortality rate as high as 40% [1, 5, 6].

A variety of pathologies, such as malignant or benign gynaecological tumours, radiation cervicitis, atrophic cervicitis, congenital anomalies, puerperal infections, cervical occlusion after surgery, and postmenopausal cervical stenosis, can obstruct the cervical canal causing impaired endometrial drainage and with concurrent bacterial infection resulting in pyometra [5, 6].

The majority of the literature and case series reported cervical carcinoma as the most common malignancy complicated with pyometra and uterine rupture [1, 3, 5, 6]. Ikeda *et al.* conducted a literature review on spontaneous rupture of pyometra and found that out of 54 patients, 18 (34%) had malignant tumours. Among them, 12 patients (67%) had cervical cancer, 5 patients (28%) had sigmoid colon cancer, and 1 patient (5%) had endometrial cancer [3]. In contrast, Kerimoglu *et al.* reported a different outcome in their study. Among 12 patients, 5 (41.6%) were diagnosed with endometrial cancer, 3 (25%) with cervical cancer, and 1 (8.3%) with uterine leiomyosarcoma [4]. In our case, the pyometra developed due to cervical canal obstruction by an endometrial mass at the uterine neck-cervical junction.

The incidence of pyometra increases significantly with advancing age, declining physical activity, incontinence, and diabetes [7]. Suspect pathological factors include age-related uterine involution, senile cervicitis, and poor hygiene. The majority of elderly patients in nursing homes are immobile or bedridden and have an increased risk of infection due to poor medical conditions and/or poor hygiene, making them more susceptible to this condition [8].

The classic symptoms of these patients are the triad of fever, abdominal pain and purulent vaginal discharge [7, 8]. Non-specific symptoms include vomiting, constipation, uterine enlargement or genital bleeding. Furthermore, more than 50% of women with non-perforated pyometra are asymptomatic [3]. In our case, the patient's main complaint was abdominal pain. Fever was only detected during vital signs examination. Due to her advanced age and apparent cognitive decline, the patient was unable to describe any symptoms associated with the enlargement of her uterus, which mirrored a pelvic mass or vaginal discharge. In addition, she was unable to offer a comprehensive history of her symptoms, and her caretakers lacked relevant information.

Preoperative diagnosis of a perforated pyometra can be challenging in view of non-specific symptoms, lack of patients' awareness of underlying gynaecological condition and clinical examination mimicking other acute abdomen pathologies. The literature review by Ikeda *et al.* reported gastrointestinal (GI) perforation, generalized peritonitis, pneumoperitoneum, ileus and acute appendicitis as pre-operative diagnoses [3]. Gastrointestinal perforation is the most prevalent preoperative diagnosis, and this is likely attributed due to the presence of pneumoperitoneum in half the cases [1, 3, 9]. Only 19% of cases were preoperatively diagnosed accurately and most are identified by laparotomy [1].

YingYing *et al.* highlighted 5 CT characteristics to improve the diagnostic accuracy of spontaneous uterine perforation which include fluid within the endometrial cavity, fluid collection in the cul-de-sac, intra or peri-uterine free air and uterine wall defects [8]. There are only 3 features which are seen in our case, excluding the presence of intra or peri-uterine free air. Intra-uterine free air is commonly generated secondary to gas-forming bacterial infection within the uterus and when there is perforation, the air locules escape through the uterine wall defect and are mostly situated in the peri-uterine region.

According to Ikeda *et al.*, the most common bacterial cultures of peritoneal fluid or pus were *Escherichia coli* (51%) and anaerobes such as *Bacteroides* and *Peptococcus* species (41%) [3]. *Streptococcus*, *Staphylococcus*, *Klebsiella*, *Enterococcus*, *Proteus*, and *Porphyromonas* species comprised the remaining bacteria. No bacteria were isolated from the cultures in 8% of cases, similar to our culture.

Hysterectomy is the gold standard treatment, particularly in the case of uterine perforation, which requires immediate surgical intervention followed by intensive antibiotic therapy [3, 10, 11]. Conservative treatment for a uterine rupture with an intraperitoneal collection is not recommended and is associated with high comorbidity. However, it may be considered for patients at high surgical risk. In these instances, the alternate treatment is typically pus drainage and peritoneal lavage [3].

Bogani *et al.* started a study on radiomics and molecular classification in endometrial cancer (the ROME study) which discusses the potential of radiomic profiling, a method for extracting data from radiological images, to supplement molecular/genomic profiling in predicting the prognosis of endometrial cancer patients [12]. The study aims to evaluate newly diagnosed endometrial cancer patients through ultrasonographic evaluation and radiomic analysis to correlate with molecular/genomic profiling in order to identify various classes of risk for endometrial cancer, classify prognosis and tailor treatment accordingly. Radiomic profiling in this study has two pitfalls which include radiomic features variability which is affected by constitutional variables, and operator factor as ultrasound imaging is operator dependent, which might provide inconsistent readings. It is important to note, however, that the results of this study are currently unknown as it is still ongoing. It is worth noting that due to the expense associated with radiomic, genomic, and molecular profiling, these techniques are not currently employed at our centre.

The Modified Frailty Index is the most common instrument for assessing the frailty of gynecologic oncology patients [13]. Eleven variables were evaluated: diabetes, functional status index of 2 or higher, chronic obstructive pulmonary disease or pneumonia, congestive heart failure, myocardial infarction, percutaneous coronary intervention and/or stenting or angina, hypertension requiring medication, peripheral vascular disease or ischemic rest pain, impaired sensorium, transient ischemic attack or cerebrovascular accident, and cerebrovascular accident with deficit. The modified fragility index (mFI) > 3 is a significant predictor of overall and severe complications in endometrial cancer patients. This index should be included in the standard examination of patients, and it can be utilised to facilitate joint decision-making for individualised therapeutic options and perioperative treatment.

CONCLUSIONS

In light of the high morbidity and mortality that can occur as a result of a ruptured uterus linked to pyometra, it is crucial that emergency medical practitioners, radiologists, and gynaecologists work closely together to enable prompt and correct diagnosis. The possibility of this diagnosis should be taken into account when evaluating postmenopausal women who presented with acute abdomen and generalised peritonitis.

COMPLIANCE WITH ETHICAL STANDARDS

Authors contribution

D.C.F.: Conceptualization, writing – original draft. M.A.H.S.: Writing – review & editing. Z.A.S.: Resources. A.R.T.: Data curation. C.C.: Visualization.

Funding

None.

Study registration

N/A.

Disclosure of interests

The authors declare that they have no conflict of interests.

Ethical approval

N/A.

Informed consent

The authors certify that they have obtained the patient's consent form. In the form, the patient has given his consent for his images and other clinical information to be reported in the journal. The patient understands that their names and initials will not be published and due efforts will be made to conceal their identity.

Data sharing

Data are available under reasonable request to the corresponding author.

REFERENCES

1. Shapey IM, Nasser T, Dickens P, Haldar M, Solkar MH. Spontaneously perforated pyometra: an unusual cause of acute abdomen and pneumoperitoneum. *Ann R Coll Surg Engl.* 2012;94(8):e246-8. doi: 10.1308/003588412X13373405387410.
2. Kutuk MS, Ozgun MT, Tas M, Uludag S. Spontaneous uterine perforation due to pyometra. *J Obstet Gynaecol.* 2013;33(3):322-23. doi: 10.3109/01443615.2012.754415.
3. Ikeda M, Takahashi T, Kurachi H. Spontaneous perforation of pyometra: a report of seven cases and review of the literature. *Gynecol Obstet Invest.* 2013;75(4):243-9. doi: 10.1159/000349981.
4. Kerimoglu OS, Pekin A, Yilmaz SA, Bakbak BB, Celik C. Pyometra in elderly post-menopausal women: a sign of malignancy. *Eur J Gynaecol Oncol.* 2015;36(1):59-61.
5. Iwase F, Shimizu H, Koike H, Yasutomi T. Spontaneously perforated pyometra presenting as diffuse peritonitis in older females at nursing homes. *J Am Geriatr Soc.* 2001;49(1):95-6. doi: 10.1046/j.1532-5415.2001.49017.
6. Izumi J, Hirano H, Yoshioka H, Takisawa J. Computed tomography findings of spontaneous perforation of pyometra. *Jpn J Radiol.* 2010;28(3):247-9. doi: 10.1007/s11604-009-0413-5.
7. Ou YC, Lan KC, Lin H, Tsai CC, ChangChien CC. Clinical characteristics of perforated pyometra and impending perforation: specific issues in gynecological emergency. *J Obstet Gynaecol Res.* 2010;36(3):661-6. doi: 10.1111/j.1447-0756.2010.01184.
8. Yingying H, Chaoran L, Fang L, Zhigang S, Yangzong C, Jing L, et al. Five abdominal computer tomography characteristics facilitate diagnosis of spontaneous perforation of pyometra in women with acute abdomen: a case control study. *Clin Exp Obstet Gynecol.* 2021;48(6):1324-9. doi: 10.31083/j.ceog4806210.
9. Chan KS, Tan CK, Mak CW, Chia CC, Kuo CY, Yu WL. Computed tomography features of spontaneously perforated pyometra: a case report. *Acta Radiol.* 2006;47(2):226-7. doi: 10.1080/02841850500480634.
10. Uno K, Tano S, Yoshihara M, Mayama M, Ukai M, Kishigami Y, et al. A Case Report and Literature Review of Spontaneous Perforation of Pyometra. *J Emerg Med.* 2016;50(5):e231-6. doi: 10.1016/j.jemermed.2016.01.024.
11. Sawabe M, Takubo K, Esaki Y, Hatano N, Noro T, Nokubi M. Spontaneous uterine perforation as a serious complication of pyometra in elderly females. *Aust N Z J Obstet Gynaecol.* 1995;35(1):87-91. doi: 10.1111/j.1479-828x.1995.tb01840.x.
12. Bogani G, Chiappa V, Lopez S, Salvatore C, Interlenghi M, D'Oria O, et al. Radiomics and Molecular Classification in Endometrial Cancer (The ROME Study): A Step Forward to a Simplified Precision Medicine. *Healthcare (Basel).* 2022;10(12):2464. doi: 10.3390/healthcare10122464.
13. Giannini A, Di Donato V, Schiavi MC, May J, Panici PB, Congiu MA. Predictors of postoperative overall and severe complications after surgical treatment for endometrial cancer: The role of the fragility index. *Int J Gynaecol Obstet.* 2020;148(2):174-80. doi: 10.1002/ijgo.13020.