



Italian Journal of Gynæcology & Obstetrics

September 2023 - Vol. 35 - N. 3 - Quarterly - ISSN 2385 - 0868

Hysteroscopic morcellation – a novel method of scar ectopic pregnancy management: case report and review of literature

Rahul Manchanda, Sonika Sharma *

Department of Gynaecology Endoscopy, PSRI Hospital, Delhi, India.

ARTICLE INFO

History

Received: 30 January 2023

Received in revised form: 16 February 2023

Accepted: 14 March 2023

Available online: 20 September 2023

DOI: 10.36129/jog.2023.114

Key words

Caesarean; ectopic pregnancy; hysteroscopy.

*Corresponding author: Sonika Sharma, Dr., M.D., Senior resident. Department of Gynaecology Endoscopy, PSRI Hospital, Press Enclave Marg, Sheikh Sarai II, Near Saket Court, New Delhi - 110017, India.
Email: ssonika0310@gmail.com.
ORCID: 0000-0001-5082-6351.

ABSTRACT

Background. Caesarean scar ectopic pregnancy is a rare event in which an early pregnancy implants in the scar from a previous caesarean delivery. It is considered to be a life-threatening complication of caesarean section, therefore early diagnosis and timely treatment is mandatory. Treatment objective is to terminate pregnancy, reduce bleeding and fertility preservation. Medical, surgical and minimally invasive treatments are available but optimal treatment is unknown.

Case presentation. We describe the case of caesarean scar ectopic diagnosed by USG and MRI, managed by both medical and surgical method, using methotrexate and hysteroscopic morcellator. Review of literature was undertaken of available literatures by google search of data bases from Jan 1992 to Jan 2023.

Conclusions. Hysteroscopic management offers advantages over local or systemic methotrexate injection with a more rapid return to normal β hCG level, reduction in follow-up time, and is well-accepted by the patients.

INTRODUCTION

CSP occurs when an embryo implants in the fibrous scar tissue of a previous caesarean scar [1]. The true incidence of CSP is unknown, reported single-centre estimates of incidence range from 1 in 1,800 to 1 in 2,656 of overall pregnancies [2, 3]. CSP incidence is believed to be increasing over time due to several factors, including increased rates of caesarean section, improved imaging with ultrasound and magnetic resonance imaging (MRI), increased use of transvaginal ultrasonography, and possibly increased physician awareness [4-7].

Because of the fibrous nature of scar tissue, these deficient implantation sites are at risk for dehiscence, placenta accreta, and haemorrhage as the CSP enlarges. The implantation patterns of CSP can be categorized as either endogenic (also referred to as “on the scar”) or exogenic (“in the niche”). Endogenic CSP is defined as pregnancy growing within the uterine cavity and exogenic CSP as arising from a deeply implanted gestational sac into the scar that may grow toward the bladder or abdominal cavity [8, 9].

Gray scale combined with colour Doppler ultrasound imaging is recommended for diagnosis. However, in cases where ultrasound imaging is inconclusive, MRI could be considered as an adjunctive.

Gray scale combined with colour Doppler ultrasound imaging is recommended for diagnosis. However, in cases where ultrasound imaging is inconclusive, MRI could be considered as an adjunctive.

There is currently no consensus on the optimal management of CSP. The treatment options are medical, or surgical.

Hysteroscopic removal of CSP has been reported to be safe and effective as an alternative minimally invasive surgery [10]. The advantage is also that resection can be carried out under direct vision. This can avoid extensive damage to the endometrium caused by curettage, to maximize the preservation of fertility. Hysteroscopic morcellation is a recently emerged tissue removal system. Hysteroscopic morcellators avoid the use of electrosurgery. The resected tissue is aspirated at the same time through the device into a collecting pouch, which maintains a clear vision during surgery and makes the procedure efficient. Haemostasis depends on myometrial contractions. Laparoscopy or laparotomy is appropriate if the pregnancy is seen to be protruding into the abdominal cavity or bladder, where the patient is hemodynamically stable and there are appropriate facilities with experienced surgeons to undertake this procedure [11, 12]. Laparotomy and wedge resection should be considered for women who do not respond to conservative, medical, or surgical therapies or when the patient is hemodynamically unstable and uterine rupture is suspected or diagnosed [6, 8].

CASE PRESENTATION

A 35-year-old at 7 weeks gestation as a case of scar ectopic pregnancy came to the hospital. Serum β hCG showed a value of 59,880 mIU/ml (done on 12/06/22). She was counselled regarding her condition, associated complications and the available treatment

options after which she agreed for surgical management with hysteroscopic morcellator. We used Intrauterine BIGATTI Shaver (Karl Storz) (**Figure 1**). At hysteroscopy, 4 × 3 cm products of conception were noted in the cervico uterine junction along with adjacent scar tissue. Resection of products of conception along with scar tissue was done using morcellator, was sent for histopathology (**Figure 2**). Bleeding was controlled by bimanual massage, 1 g injection tranexamic acid and 250 mg methergine. After controlling bleeding, laparoscopy was done. Patient was monitored in the hospital overnight, was given another dose of MTX 50 mg i/m on 12/07/22 and 2nd post-operative day (POD) alternating with injection 10 mg leucovorin. β hCG was done on 2nd POD which came out to be 4,439.00 mIU/mL. Patient was discharged. She was followed up and advised contraception. β hCG was 72.60 mIU/mL (**Table 1**).

RESULTS

Hysteroscopic morcellation is a novel technique for management of CSP as it is safe and effective

Table 1. Decreasing trend of β hCG after surgery.

Date	β hCG (mIU/ml)
12/05/22	37,921.00
12/06/22 (PRE-OP)	59,880.00
12/08/22 (1 st POD)	10,457.00
12/09/22	4,439.00
12/12/22	739.00
12/14/22 (7 th POD)	72.60
12/26/22	11.00

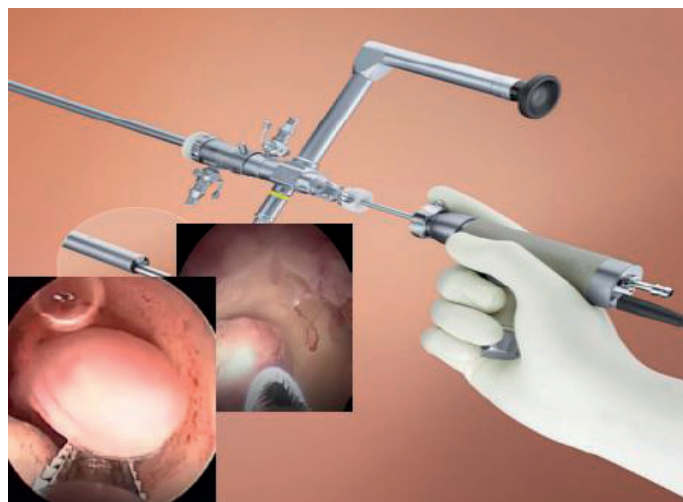


Figure 1. Intrauterine BIGATTI Shaver (Karl Storz).

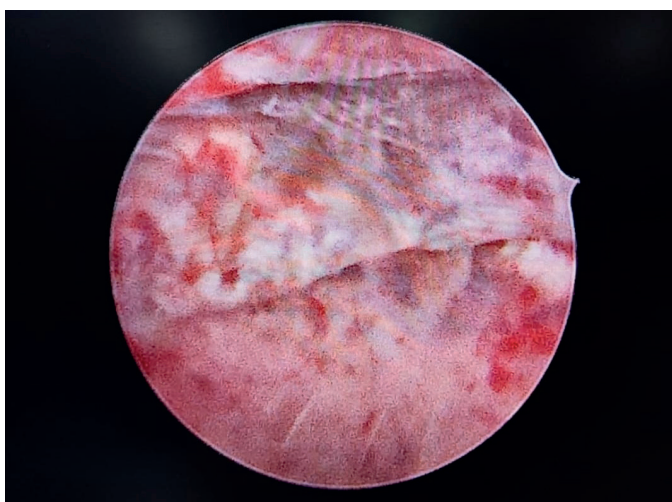


Figure 2. Resection of scar pregnancy.

with short operating time, less hospitalization time, significantly shorter time for β hCG to drop to normal levels. It also confirms the diagnosis and is performed under vision.

DISCUSSION

Worldwide, caesarean section rates are on the rise, resulting in increasing obstetrical sequelae, such as placenta accreta, scar dehiscence and ectopic scar pregnancy due to incomplete healing of the caesarean section incision. A number of hypotheses may explain caesarean scar defect development: a very low incision through the cervical tissue, inadequate suturing or incomplete closure of the uterine wall due to a single-layer endometrial-saving closure technique or use of locking sutures, and surgical interventions that encourage adhesion formation [13].

CSP is defined as a pregnancy embedded in a previous caesarean scar and completely surrounded by myometrium and fibrous tissue. It has been proposed that the implantation invades the myometrium through a microtubular tract between the caesarean scar and endometrial cavity [14-16]. It differs from placenta accreta by its early invasion into the myometrium and is completely surrounded by fibrous scar tissue. The pregnancy may grow back toward the uterine cavity, potentially forming increta or percreta, or out of the uterus toward the bladder and abdominal cavity, implanting elsewhere in the abdomen, which is the type most prone to rupture [11]. Pathological specimens of the uterus from CSP show that chorionic villi are not merely penetrating the myometrium but are bound and implanted in it [17]. It has been estimated that transvaginal ultrasound (TVS) with colour Doppler has a diagnostic sensitivity of 86.4% [18]. Magnetic resonance imaging is usually reserved for cases in which the TVS is equivocal [6].

Uterine conserving treatment is preferred, and expectant management is not recommended due to a high risk of uterine rupture [8]. Termination of pregnancy by medical or surgical methods during the first trimester is the treatment of choice due to the reduced risk of invasion into the bladder and surrounding organs. Medical management with injection methotrexate (MTX) has been used effectively for caesarean scar pregnancies as in other types of ectopic pregnancies. Symptom-free, hemodynamically stable, unruptured pregnancy of

gestational age < 8 weeks are candidates for methotrexate [19]. The standard single-dose regimen for methotrexate is 50 mg/m², whereas the multidose protocol includes four doses of methotrexate 1 mg/kg given on Days 1, 3, 5, and 7 with alternating days of folinic acid 0.1 mg/kg [20].

Intragastric injection is typically performed with a 20-gauge needle under ultrasound guidance using a transvaginal approach. When pursuing medical treatment of CSP, local or intragastric injection of methotrexate is a preferred approach, with or without accompanying systemic methotrexate. Administration of a single injection of MTX, potassium chloride (KCL), hyperosmolar glucose, or crystalline trichosanthin under ultrasound guidance has been used [21].

Multi dose methotrexate regimen has often shown to have a more rapid response than single dose therapy [22]. Close follow-up is required and may need to be combined with surgical approaches either electively or emergently if heavy bleeding starts.

Maymon *et al.* described systemic MTX as an appropriate management option when the woman is pain free and hemodynamically stable, with an unruptured CSP of < 8 weeks. More than half the women treated in this manner required a secondary procedure including local injection of MTX with or without sac aspiration and in some instances laparotomy and hysterotomy [5]. Other investigators have described intrasac aspiration and injection of embryocides, resulting in higher success rates as a primary procedure, which is further improved by a combination of systemic and local injection of embryocides [4, 23-26].

Medical management is less invasive for the patient, but the extended surveillance time, the prolonged return time of β hCG to normal, and resolution of local scar mass are problematic. Since medically managed CSP has been reported to take 2 months-1 year to resolve, the patient's age and desire for fertility must be considered and openly discussed before making a management plan with the patient [3]. Although a small randomized trial of systemic *vs* local methotrexate demonstrated no difference in overall cure rates, 44 reviews suggest a high risk of complications with intramuscular methotrexate alone, and local methotrexate seems to be a more effective approach [27, 28].

In a literature review, 45 of 96 cases of intragastric methotrexate for CSP, success was achieved in 73.9% after a single local methotrexate injection,

and increased to 88.5% after an additional local or intramuscular methotrexate injection [28].

The surgical modalities that have been described for CSP treatment include dilatation and curettage, laparoscopic guided suction aspiration, laparoscopic or open wedge resection, hysteroscopic evacuation, uterine artery embolization (UAE) or rarely hysterectomy [6]. A cohort study in the U.K. that was performed shows surgery to be associated with a high success rate (96%), low complication rate (36%), and short post-treatment follow up [29]. Surgical management involves laparotomy with removal of scar and resuturing so as to reduce recurrence and limit follow-up period. Laparoscopy has been described successfully in a small case series [12, 30]. Uterine curettage as first-line management is discouraged as it may ensue bleeding and uterine rupture or may fail to reach the product of conception and associated with high failure rates [19]. In this era of minimal access surgery, hysteroscopy and/or laparoscopy play a major role in management of these patients. They enable direct visualization of the pathology thus preventing complications associated with blind procedures.

Hysteroscopy has been indispensable in evaluating intrauterine pathology. The stop approach which include diagnosis and treatment at same sitting is minimally invasive, low risk, well tolerated, cost and time effective procedure and is being highly preferred by the patients [31]. Current management of several intrauterine pathologies relies on the possibility to use different devices who could be an option for difficult cases [32].

Hysteroscopy has a distinct advantage that it can completely resect the gestational mass, significantly shortening the time for β hCG drop to a normal level and the hospital stay. However, laparoscopy can be employed in combination with hysteroscopy under direct visualization and particularly after successful medical management. In a case series, hysteroscopy was used in conjunction with laparoscopy [6]. If anterior myometrial thickness was < 3 mm on ultrasound, laparoscopy was performed prior to hysteroscopy to dissect bladder peritoneum from the lower uterine segment to attempt to remove the bladder from the site of surgical management and decrease risk of bladder injury [33]. Furthermore, even if the uterus is perforated, the caesarean scar can be effectively resected along with its gestational tissue and repaired laparoscopically.

Hysteroscopic removal was first described by Wang *et al.* in 2005, where the CSP was removed without

complication, and four weeks after the procedure there was normal sonographic echotexture of the uterus and normal serum β hCG [34]. A further series of six patients treated by hysteroscopic removal of CSP reports no complications with rapid return to normal serum β hCG levels (mean 22 days) [35]. In a review that included 751 reported cases of CSP and 31 different treatment approaches, a 44.1% complication rate was reported. Complications included unplanned emergency operations that included hysterectomy (4.8%), laparotomy (5.3%), and UAE (2.9%). Among procedures described by the authors as first-line, the highest complication rates were observed with intramuscular methotrexate alone (54/87 cases, 62.1%), curettage alone or in combination with other modalities (189/305 cases, 61.9%), and UAE alone or in combination with other modalities (30/64 cases, 46.9%). The lowest complication rates among first-line therapies were reported with hysteroscopy alone or in combination (22/119 cases, 18.4%) and local intragestational injection of methotrexate or KCl (8/81 cases, 9.6%). On the basis of observed complication rates, this review supported the use of local methotrexate and hysteroscopy-based approaches to CSP treatment and discouraged the stand-alone use of systemic methotrexate, curettage, and UAE [27].

A retrospective study was conducted and found that transabdominal ultrasound-guided hysteroscopic curettage is an effective and relatively safe treatment option for patients. Intraoperative haemorrhage was found to be associated with type of CSP and diameter of gestational sac [35].

Different conclusions were reached in a systematic review by Birch Petersen *et al.* that compiled 2,037 CSP cases, some of which overlapped with the Timor-Tritsch report and included data from four randomized trials and 48 case series. Among CSP cases with available gestational age data, most were detected in the first trimester. Treatment modalities were condensed into 14 main approaches. Success was defined as the efficacy of a first-line treatment modality in resolving a CSP. Major complications were defined as hysterectomy, estimated blood loss of $> 1,000$ mL, or a need for blood transfusion. The lowest success rates were observed with expectant management (41.5% success, 53.7% complications), curettage (48.1% success, 21% complications), UAE and methotrexate (68.6% success, 2.8% complications), systemic methotrexate (75.2% success, 13% complications), and combined local and systemic methotrexate (76.5% success, 2.3% complications).

Among reported therapies, the highest success rates were observed with transvaginal CSP resection (99.2% success, 0.9% complications), laparoscopy (97.1% success, 0% complications) [36].

Other surgical options include uterine artery embolization, where embolus can be injected into uterine arteries prior to hysteroscopy to reduce the risk of bleeding. UAE with curettage, hysteroscopy, or both (95.4% success, 1.2% complications), and UAE alone (93.6% success, 3.4% complications). Previous studies have shown an adverse effect on endometrial and ovarian function of UAE [37, 38]. As this procedure may cause inadvertent ovarian embolization, patients' plans for future fertility should be considered. Daram *et al.* reported a case in which Myosure device was used as a successful treatment for removing products of conception of caesarean scar ectopic pregnancy [39]. Keriakos *et al.* also used Myosure for the management of cornual ectopic pregnancy [40]. Hysteroscopic morcellation is a minimally invasive operative technique that offers direct visualization, low morbidity, and high success rates. It has the distinct advantage over systemic and local injection techniques in that it affords the patient shorter follow-up time and more rapid return to fertility.

These devices work with physiological saline solution as distension media. They don't use high frequency current, need less skill than resectoscopic surgery and takes shorter operative time. Also with the use of resectoscope there is formation of tissue chips which obscure the visual field of surgeon increasing the risk of perforation but in morcellator tissue chips are removed at the same time. It is an alternative and emerging approach to operative hysteroscopy.

Technical advances have focused mainly on miniaturizing the instruments to perform operative procedures and to reduce patient discomfort resulting from cervical dilatation and anaesthesia [41]. Evidences have supported the use of pharmacological and non-pharmacological strategies for reducing pain during office hysteroscopy [42].

Uterine artery embolization (UAE) has been reported as a stand-alone procedure and in combination with curettage, methotrexate, and hysteroscopy. Despite its extensive use in CSP, UAE is not favourably recommended as the first-line strategy for women who are planning on future pregnancies.

Intraoperative or postoperative complications can occur, such as profuse haemorrhage, uterine perforation, shock, and even life-threatening events. The most common is haemorrhage. In case of severe bleeding, we cannot coagulate and sacrifice bleeders. Haemo-

static measures including double balloon catheter for tamponade, uterine artery ligation, uterine artery embolization, cervical stitch or hysterectomy.

CONCLUSIONS

There is limited literature on management of scar pregnancy using hysteroscopic morcellator as per now, but this is an emerging treatment option for management of CSP. Further larger studies should be carried out to evaluate the efficacy of using hysteroscopic morcellator for the treatment of this condition.

Strength

This is a novel technique that avoids traditional laparoscopy or laparotomy repair and trauma.

Limitation

Limited data available on management of CSP with hysteroscopic morcellator. So, it is difficult to compare it with other methods of management.

COMPLIANCE WITH ETHICAL STANDARDS

Authors contribution

M.A.: Data curation, conceptualization, writing – review & editing, validation. S.S.: Writing – original draft, literature review, editing.

Funding

None.

Study registration

N/A.

Disclosure of interests

The authors declare that they have no conflict of interests.

Ethical approval

Case reports are exempted from the requirement of Ethical approval by the Institutional Research and Ethics Committee.

Informed consent

Written informed consent was obtained from the patient for anonymized publication of this case report and accompanying images.

Data sharing

Data are available upon reasonable request to the corresponding author.

ACKNOWLEDGEMENTS

The authors would like to thank the patient and her family for their cooperation.

REFERENCES

- Riaz RM, Williams TR, Craig BM, Myers DT. Cesarean scar ectopic pregnancy: imaging features, current treatment options, and clinical outcomes. *Abdom Imaging*. 2015;40(7):2589-99. doi: 10.1007/s00261-0515-0472-2.
- Jurkovic D, Hillaby K, Woelfer B, Lawrence A, Salim R, Elson CJ, et al. First trimester diagnosis and management of pregnancies implanted into the lower uterine segment caesarean section scar. *Ultrasound ObstetGynaecol*. 2003;21(3):220-7. doi: 10.1002/uog.56.
- Seow KM, Huang LW, Lin YH, Lin MY, Tsai YL, Hwang JL, et al. Cesarean scar pregnancy: issues in management. *Ultrasound Obstet Gynaecol*. 2004;23(3):247-53. doi: 10.1002/uog.974.
- Godin PA, Bassil S, Donnez J. An ectopic pregnancy developing in a previous caesarian section scar. *Fertil Steril*. 1997;67(2):398-400. doi: 10.1016/S0015-0282(97)81930-9.
- Maymon R, Halperin R, Mendlovic S, Schneider D, Herman A. Ectopic pregnancies in a caesarean scar: review of the medical approach to an iatrogenic complication. *Hum Reprod Update*. 2004;10(6):515-23. doi: 10.1093/humupd/dmh042.
- Ash A, Smith A, Maxwell D. Cesarean scar pregnancy. *BJOG* 2007;114(3):253-63. doi: 10.1111/j.1471-0528.
- Tantbirojn P, Crum CP, Parast MM. Pathophysiology of placenta accreta: the role of decidua and extravillous trophoblast. *Placenta*. 2008;29(7):639-45. doi: 10.1016/j.placenta.2008.04.008.
- Rotas MA, Haberman S, Levigur M. Cesarean scar ectopic pregnancies: etiology, diagnosis, and management. *ObstetGynaecol*. 2006;107(6):1373-81. doi: 10.1097/01.AOG.0000218690.24494.ce.
- Gonzalez N, Tulandi T. Cesarean scar pregnancy: a systematic review. *J Minim Invasive Gynaecol*. 2017;24(5):731-8. doi: 10.1016/j.jmig.2017.02.020.
- Jurkovic D, Hillaby K, Woelfer B, Lawrence A, Salim R, Elson CJ, et al. First-trimester diagnosis and management of pregnancies implanted into the lower uterine segment caesarean section scar. *Ultrasound ObstetGynaecol*. 2003;21(3):220-7. doi: 10.1002/uog.56.
- Vial Y, Petignat P, Hohlfeld P. Pregnancy in cesarean scar. *Ultrasound Obstet Gynaecol*. 2000;16(6):592-3. doi: 10.1046/j.1469-0705.2000.00300-2.x.
- Wang YL, Su TH, Chen HS. Laparoscopic management of an ectopic pregnancy in a lower segment caesarean section scar: a review and a case report. *J Minim Invas Gynaecol*. 2005;12(1):73-9. doi: 10.1016/j.jmig.2004.12.001.
- Zhang H, Huang J, Wu X, Fan H, Li H, Gao T. Clinical classification and treatment of cesarean scar pregnancy. *J Obstet Gynaecol Res*. 2017;43(4):653-61. doi: 10.1111/jog.13267.
- Vervoort AJ, Uittenbogaard LB, Hehenkamp WJ, Brölmann HA, Mol BW, Huirne JA, et al. Why do niches develop in Caesarean uterine scars? Hypotheses on the aetiology of niche development. *Hum Reprod*. 2015;30(12):2695-702. doi: 10.1093/humreo/dev240.
- Fylstra DL. Ectopic pregnancy within a cesarean scar: a review. *Obstet Gynaecol Surv*. 2002;57(8):537-43. doi: 10.1097/00006254-200208000-00024.
- Coniglio C, Dickinson JE. Pregnancy following prior caesarean scar rupture: lessons for the modern obstetric practice. *Aust N Z J Obstet Gynaecol*. 2004;44(2):162-5. doi: 10.1111/j.1479-828X.2004.00176.x.
- Chazotte C, Coher WR. Catastrophic complications of a previous cesarean section. *Am J Obstet Gynaecol*. 1990;163(3):738-42. doi: 10.1016/0002-9378(90)91059-1.
- Einenkel J, Stumpp P, Kosling S, Horn LC, Hockel M. A misdiagnosed case of caesarean scar pregnancy. *Arch Gynaecol Obstet*. 2005;271(2):178-81. doi: 10.1007/s00404-004-0683-1.
- Jayaram P, Okunoye G, Al Ibrahim AA, Ghani R, Kalache K. Expectant management of caesar-

- ean scar ectopic pregnancy: a systematic review. *J Perinat Med.* 2018;46(4):365-72. doi: 10.1515/jpm-2017-0189.
20. Hamilton CJ, Legarth J, Jaroudi KA. Intramural pregnancy after in vitro fertilization and embryo transfer. *Fertil Steril.* 1992;57(1):215-7. doi: 10.1016/s0015-0282(16)54804-3.
 21. Cunningham F, Leveno KJ, Bloom SL. Implantation and placental development. *Williams Obstetrics, 25e.* McGraw Hill Education, New York, NY, 2018;80-123.
 22. Lam PM, Lo KWK. Multiple-dose methotrexate for pregnancy in a cesarean section scar. A case report. *J Reprod Med.* 2002;47(4):332-4.
 23. Ravhon A, Ben-Chetrit A, Rabinowitz R, Nauman M, Beller U. Successful methotrexate treatment of a viable pregnancy within a thin uterine scar. *Br J Obstet Gynaecol.* 1997;104(5):628-9. doi: 10.1111/j.1471-0528.1997.tb11547.x.
 24. Hartung J, Meckies J. Management of a case of uterine scar pregnancy by transabdominal potassium chloride injection. *Ultrasound Obstet Gynaecol.* 2003;21(1):94-9. doi: 10.1002/uog.014.
 25. Lai Y-M, Lee J-D, Chen T-C, Soong Y-K. An ectopic pregnancy embedded in the myometrium of a previous cesarean section scar. *Acta Obstet Gynaecol Scand.* 1995;74(7):573-6. doi: 10.3109/00016349509024394.
 26. Hsieh BC, Hwang JL, Pan HS, Chen CY, Chen PH. Heterotopic cesarean scar pregnancy combined with intrauterine pregnancy successfully treated with embryo aspiration for selective embryo reduction: case report. *Hum Reprod.* 2004;19(2):285-7. doi: 10.1093/humrep/deh080.
 27. Timor-Tritsch IE, Monteagudo A. Unforeseen consequences of the increasing rate of cesarean deliveries: early placenta accreta and cesarean scar pregnancy. A review. *Am J Obstet Gynaecol.* 2012;207(1):14-29. doi: 10.1016/j.ajog.2012.03.007.
 28. Cheung VY. Local methotrexate injection as the first-line treatment for cesarean scar pregnancy: review of the literature. *J Minim Invasive Gynaecol.* 2015;22(5):753-8. doi: 10.1016/j.jmig.2015.04.008.
 29. Harb HM, Knight M, Bottomley C, Overton C, Tobias A, Gallos ID, et al. Cesarean scar pregnancy in the UK: a national cohort study. *BJOG.* 2018;125(13):1663-70. doi: 10.1111/1471-0528.15255.
 30. Wang YL, Su T-H, Chen H-S. Operative laparoscopy for unruptured ectopic pregnancy in a cesarean scar. *Br J Obstet Gynaecol.* 2006;113(9):1035-8. doi: 10.1111/j.1471-0528.2006.01031.x.
 31. Jha S, Surabhi K. Hysteroscopy "As one stop approach" in the management of intrauterine pathology. Focus on patient's satisfaction. *Ital J Gynaecol Obstet.* 2021;33(2):102-9. doi: 10.36129/jog.33.02.04.
 32. Vitale SG, Lagana AS, Caruso S, Garzon S, Vecchio GM, La Rosa VL, et al. Comparison of three biopsy forceps for hysteroscopic endometrial biopsy in postmenopausal patients (HYGREB-1): A multicenter, single-blind randomized clinical trial. *Int J Gynaecol Obstet.* 2021;155(3):425-32. doi: 10.1002/ijgo.13669.
 33. Pan Y, Liu MB. The value of hysteroscopic management of cesarean scar pregnancy. *Taiwan J Obstet Gynecol* 2017;56(2):139-42. doi: 10.1016/j.tjog.2016.06.020.
 34. Wang C-J, Yuen L-T, Chao A-S, Lee C-L, Yen C-F, Soong Y-K, et al. Cesarean scar pregnancy successfully treated by operative hysteroscopy and suction curettage. *Br J Obstet Gynaecol.* 2005;112(6):839-40. doi: 10.1111/j.1471-0528.2005.00532.x.
 35. Wang C-J, Chao AS, Yuen L-T, Wang C-W, Soong Y-K, Lee C-L, et al. Endoscopic management of Cesarean scar pregnancy. *Fertil Steril.* 2006;85(2):494.e1-4. doi: 10.1016/j.fertnstert.2005.07.1322.
 36. Birch Petersen K, Hoffmann E, Ribbjerg Larsen C, Svarre Nielsen H. Cesarean scar pregnancy: a systematic review of treatment studies. *Fertil Steril.* 2016;105(4):958-67. doi: 10.1016/j.fertnstert.2015.12.130.
 37. Hehenkamp WJ, Volkers NA, Broekmans FJ, de Jong FH, Themmen AP, Birnie E, et al. Loss of ovarian reserve after uterine artery embolization: a randomized comparison with hysterectomy. *Hum Reprod.* 2007;22(7):1996-2005. doi: 10.1093/humrep/dem105.
 38. Arthur R, Kachura J, Liu G, Chan C, Shapiro H. Laparoscopic myomectomy versus uterine artery embolization: long-term impact on markers of ovarian reserve. *J Obstet Gynaecol Can.* 2014;36(3):240-7. doi: 10.1016/S1701-2163(15)30632-0.
 39. Daram NR, Berry L, Fakh M. Successful Use of Myosure in the management of cesarean scar ectopic pregnancy. *Cureus.* 2021;13(8):e17500. doi: 10.7759/cureus.17500.
 40. Keriakos R, Khalid S. Myosure in management of cornual ectopic pregnancy. *J Obstet Gynaecol.* 2015;36(4):426-7. doi: 10.3109/01443615.2015.1086988.

41. Ricciardi R, Lanzone A, Tagliaferri V, Di Florio C, Ricciardi L, Selvaggi L, et al. Using a 16-French resectoscope as an alternative device in treatment of uterine lesions: a randomized controlled trial. *Obstet Gynecol* 2012;120(1):160-5. doi: 10.1097/AOG.0b013e31825b9086.
42. Buzzaraccarini G, Alonso Pacheco L, Vitagliano A, Haimovich S, Chiantera V, Torok P, et al. Pain management during office hysteroscopy: an evidence based approach. *Medicina* 2022;58(8):1132. doi: 10.3390/medicina58081132.