











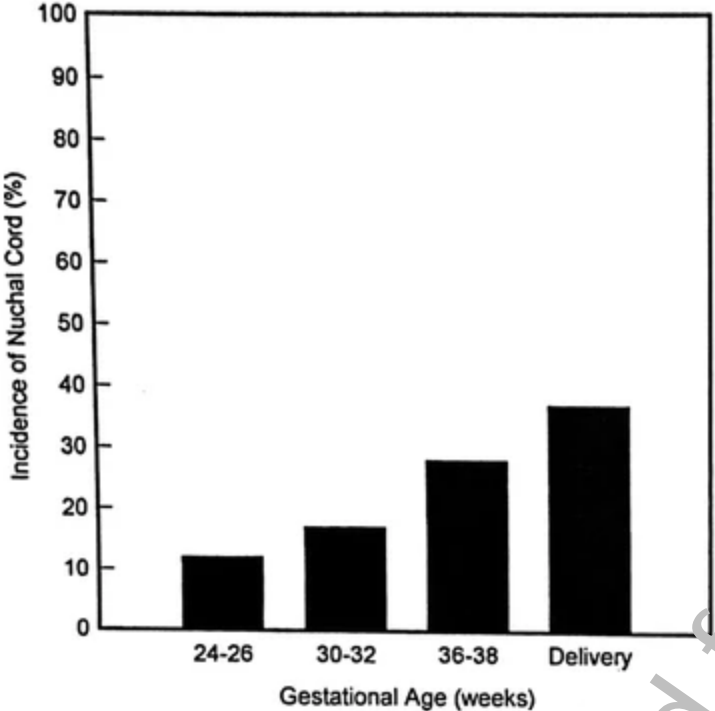








Figure 3. A diagram shows the incidence of nuchal cords is increases with advancing gestation age (with permission)



Manuscript accepted for publication