



Italian Journal of Gynæcology & Obstetrics

March 2024 - Vol. 36 - N. 1 - Quarterly - ISSN 2385 – 0868

Catamenial pneumothorax in peri-menopausal women: a report of two cases

So Ra Oh, Jung-Woo Park *

Department of Obstetrics and Gynecology, Dong-A University Hospital, Dong-A University College of Medicine, Busan, Republic of Korea.

ARTICLE INFO

History

Received: 05 September 2022

Received in revised form: 06 October 2022

Accepted: 03 January 2023

Available online: 19 March 2024

DOI: 10.36129/jog.2023.92

Key words

Catamenial pneumothorax; thoracic endometriosis; peri-menopausal women.

*Corresponding author: Jung-Woo Park, M.D., PhD. Department of Obstetrics and Gynecology, Dong-A University College of Medicine, 26 Daesingongwon-ro, Seo-gu, Busan, 49201, Republic of Korea.
Email: mdpjw1216@gmail.com.
ORCID: 0000-0001-6154-0834.

INTRODUCTION

Catamenial pneumothorax (CP) is defined as a spontaneous recurrent pneumothorax that occurs in women of reproductive age. The word “catamenial” is derived from the Greek word “katamenios”, which is a combination of “kata” and “menos”, meaning a monthly occurrence [1]. CP is associated with thoracic and pelvic endometriosis, with a reported incidence of 2.8-5.6% among women suffering from spontaneous pneumothorax, although endometriosis is not universally documented in such patients [2, 3].

ABSTRACT

Background. Thoracic endometriosis is diagnosed as the presence of endometrial tissue in the thoracic cavity. Catamenial pneumothorax (CP) is most common clinical manifestation of thoracic endometriosis and is defined as a spontaneous recurrent pneumothorax that occurs in ovulatory women. CP generally occurs in women around 30 years old. The prevalence of CP in perimenopausal women may be considerably underestimated if these cases are treated as spontaneous pneumothorax. Catamenial or thoracic endometriosis-related pneumothorax occurring in perimenopausal women has not yet been reported to show laterality.

Case presentation. We report two cases of CP in peri-menopausal women. In the first case, a 47-year-old G0P0 woman visited the hospital with recurrent pneumothorax that occurred three years after hysterectomy. In the second case, a 46-year-old G0P0 woman visited the hospital with four episodes of chronic recurring spontaneous pneumothorax in the past nine months.

Conclusions. Disease awareness of pneumothorax in perimenopausal women may lead to improved treatment results, mainly reducing the recurrence rates of CP.

Endometriosis is diagnosed as the presence of functional ectopic endometrial glands and stroma outside of the uterine cavity [4]. The ectopic endometrial growths respond to estrogen stimulation with cyclic bleeding, inducing chronic inflammatory reaction that may progress to fibrosis related to pelvic pain [5]. The etiopathogenesis is not clear, and the most approved theory explains the retrograde transplantation of endometrial tissue through the fallopian tubes [2]. Meanwhile, Buggio *et al.* [6] suggest that a prenatal exposure to environmental estrogen will result in a comparatively shorter anogenital distance, which may serve as

a secondary marker of higher risk of developing endometriosis later in life.

Thoracic endometriosis is the most common extra-pelvic site of endometriosis [7]. CP is also the most common clinical manifestation of thoracic endometriosis, occurring in 72-73% of such patients, followed by catamenial hemoptysis, catamenial hemothorax and endometriotic thoracic nodules [8-10]. CP typically develops within 24h before and 72h after the first day of the menstrual bleeding and appears almost exclusively in the right hemithorax, in contrast to pneumothorax caused by congenital defects on the left side [2]. The diagnosis of CP is not always verified by histopathological analysis, and its temporal relationship with menstruation is important. Combined surgical and hormonal treatment is considered the optimal management strategy for CP, as postoperative recurrences are usual and hormonal therapy is an effective prevention mechanism [3, 8].

CP accounts for > 30% of all cases with spontaneous pneumothorax in young women, with a peak incidence in those aged 30 to 35 years [8, 9]. The prevalence of CP in perimenopausal women may be considerably underestimated if these cases are treated as spontaneous pneumothorax. Nevertheless, not a few cases reported the occurrence of CP among women over the age of 45 [11-13]. However, catamenial or thoracic endometriosis-related pneumothorax focusing on occurrence in women during the transitional period of menopause has not yet been reported to show laterality. Disease awareness of pneumothorax in perimenopausal women may lead to improved treatment results, mainly reducing the recurrence rates of CP. Herein, we report two cases of CP in peri-menopausal women.

CASE PRESENTATION

Case 1

In January 2017, a 47-year-old G0P0 woman was referred for two episodes of right-sided recurrent spontaneous pneumothorax in the prior four months. She had a significant medical history of severe endometriosis, resulting in a total laparoscopic hysterectomy with right ovarian cystectomy at the age of 44 years. The patient received 2 mg of dienogest daily for 9 months, and was hormone-free for 18 months prior to her visit. The 1st episode was resolved using a tube thoracostomy.

In the 2nd episode, the patient initially presented to our emergency room with right-sided pleuritic chest pain and associated dyspnea (**Figure 1**). Despite application of a thoracic tube, she had to undergo video-assisted thoracoscopic surgery (VATS) because of continued air leakage. The attending clinicians noted several blueberry spot-like lesions with fenestration in the central tendinous part of the diaphragm and white nodules on the visceral pleura. Scar-like tissue with hemorrhagic discoloration was noted in the apex of the right lung parenchyma. Partial resection of the diaphragm and wedge resection were also performed. Intra-operative gynecologic ultrasound did not reveal any suspicion of pelvic endometriosis. Histological examination of the resected tissues confirmed the presence of fibromuscular tissue. Based on the clinical diagnosis, daily administration of dienogest 2 mg was initiated to prevent recurrence after surgery. The patient has been symptom-free for 53 months.

Case 2

In January 2017, a 46-year-old otherwise healthy G0P0 woman was referred for four episodes of chronic recurring spontaneous right pneumothorax in the past nine months. The patient was initially hospitalized for dyspnea and chest pain that

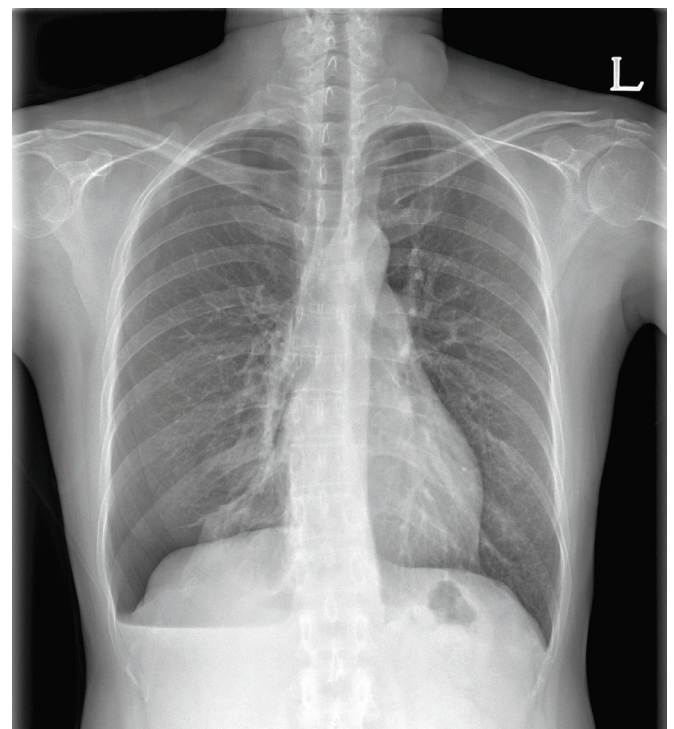


Figure 1. Chest X-ray revealed right pneumothorax.

developed after the last day of menstruation. She resumed menstruation on the day of hospitalization. Chest radiography revealed a right pneumothorax, which was managed with an emergency tube thoracostomy.

Seven months later, the patient was hospitalized again because of aggravation of dyspnea that occurred three days before menstruation (**Figure 2**). VATS was performed because of continued air leakage after the thoracic tube. Examination of the pleural cavity revealed three typical black-pigmented nodular lesions on the visceral pleura, strongly suggestive of endometriosis. Multiple perforations in the central tendinous part of the diaphragm and several nearly perforated thinner spots on the diaphragm were also observed. Histological examination of the resected tissues confirmed the presence of multifocal nodules composed of proliferating capillaries, spindle cells, and macrophages.

Six days later, a 3rd episode happened on the first day of menses, and the 4th episode occurred a month later during menstruation. Although the patient did not have any history of pelvic or lower abdominal pain, her serum CA 125 level was nearly normal (36.8 g/mL), and further evaluation by pelvic ultrasonography excluded the presence of pelvic endometriosis; catamenial pneumotho-

rax was therefore considered. Daily treatment was started with an oral contraceptive containing ethinyl estradiol and drospirenone, and the patient has remained asymptomatic for 49 months.

DISCUSSION

CP is a spontaneous recurrent pneumothorax occurring in a temporal relation with menses. It is a syndrome usually considered to occur in women of reproductive age. Nevertheless, a few rare cases of CP in women with ovulatory suppression including pregnant women have been reported [14, 15]. However, in our literature review, we could not find a detailed description of the clinical presentations and possible pathogenesis of CP occurring during menopausal transition. To our knowledge, this is the first case report of catamenial or thoracic endometriosis-related pneumothorax in a peri-menopausal woman. These cases therefore present several learning points.

The representative clinical manifestation of CP is spontaneous pneumothorax in synchrony or preceding with menses, generally presenting with chest pain, dyspnea, and cough. A diagnosis of CP requires a high level of clinical suspicion relating respiratory symptoms temporally to the stage of menstrual cycle. However, as in our first case, it is difficult to recognize the temporal relationship between pneumothorax and menstruation in perimenopausal women who have undergone hysterectomy. Nevertheless, we were able to diagnose CP in a timely manner, based on at least two episodes during menopause transition and a previous diagnosis of severe pelvic endometriosis. CP has been associated with clinically or histopathologically proven pelvic endometriosis in 20-70% of CP cases [16].

The general period defined for CP was 24h before to 72h after the first day of the menstrual cycle. However, in our second case, the occurrence of episodes did not strictly follow this timeframe; this discrepancy was probably related to the change in the normal pattern of her periods during perimenopause. Despite these temporal definitions, in the literature, pneumothorax may be diagnosed as "catamenial" without showing strict relationships with menses [1].

Endometriosis seems to play a significant role in the occurrence of CP. Characteristic lesions associated with catamenial or thoracic endometriosis-related pneumothorax include diaphragmatic defects and/or thoracic (diaphragmatic, visceral, or parietal) spots

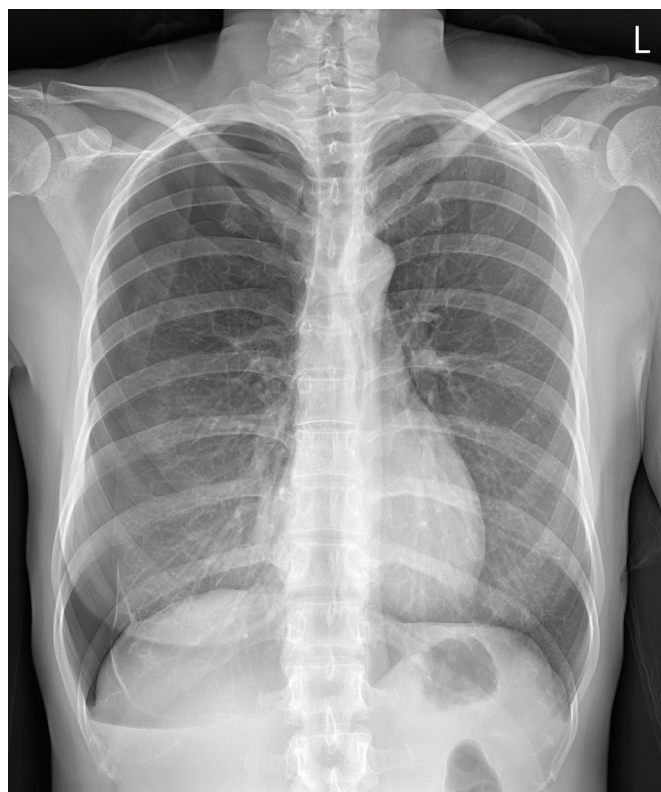


Figure 2. Chest X-ray revealed right pneumothorax and calcified pleura in right lower lung.

or nodules [1]. These findings may coexist, or present alone [16]. Macroscopic evidence of characteristic lesions on thoracoscopy or thoracotomy depends on disease awareness and precise inspection of the thorax, including the diaphragm. However, bullae and/or blebs may be the only thoracic pathology, and in some cases, there is no identifiable pathological findings [17].

CP is a rare condition, and its exact etiology and pathology are not well known. The three hypotheses that may account for the etiopathogenesis of thoracic endometriosis include retrograde menstruation through a defect in the diaphragm, coelomic metaplasia, and lymphatic or hematogenous embolization [18]. Physiologically, a high level of prostaglandin F₂ during menstruation may cause bronchioles and blood vessels to contract, which leads to alveolar rupture and development of pneumothorax [19]. None of these can explain all the clinical features of thoracic endometriosis. In fact, the terms “catamenial pneumothorax” or “thoracic pneumothorax” are not a single disease entity, but a broader category of entities. Management of this condition is quite variable because of a lack of recommendations. Although combined surgical and hormonal treatments have been recommended, no consensus has yet emerged [20].

CONCLUSIONS

We highlight two cases of catamenial pneumothorax as the cause of recurrent pneumothorax in peri-menopausal patients. Although quite rare, clinicians should consider this diagnosis in peri-menopausal women who present with a spontaneous pneumothorax, especially recurrent pneumothorax, as unique treatment strategies are required to prevent further recurrence.

COMPLIANCE WITH ETHICAL STANDARDS

Authors contribution

J.W.P.: Conceptualization, supervision. S.R.O.: Data curation, investigation, resources, writing – original draft, writing – review & editing.

Funding

None.

Study registration

N/A.

Disclosure of interests

The authors declare that they have no conflict of interests.

Ethical approval

N/A.

Informed consent

Obtained.

Data sharing

Data are available under reasonable request to the corresponding author.

REFERENCES

1. Visouli AN, Zarogoulidis K, Kougioumtzi I, Huang H, Li Q, Dryllis G, et al. Catamenial pneumothorax. *J Thorac Dis*. 2014;6(Suppl 4):S448-60. doi: 10.3978/j.issn.2072-1439.2014.08.49.
2. Nezhat C, Main J, Paka C, Nezhat A, Beygui RE. Multidisciplinary treatment for thoracic and abdominopelvic endometriosis. *JSLs*. 2014;18(3):e2014.00312. doi: 10.4293/JSLs.2014.00312.
3. Papafragaki D, Concannon L. Catamenial pneumothorax: a case report and review of the literature. *J Womens Health (Larchmt)*. 2008;17(3):367-72. doi: 10.1089/jwh.2007.0553.
4. Lameira P, Abecasis M, Palma S, Leitão J. Catamenial pneumothorax: a rare manifestation of endometriosis. *Radiol Case Rep*. 2022;17(9):3119-25. doi: 10.1016/j.radcr.
5. Gordts S, Koninckx P, Brosens I. Pathogenesis of deep endometriosis. *Fertil Steril*. 2017;108(6):872-85.e1. doi: 10.1016/j.fertnstert.
6. Buggio L, Barbara G, Dridi D, Ottolini F, Sergenti G, Facchin F, et al. Anogenital distance and Gynaecological diseases: a narrative review. *Ital J Gynaecol Obstet*. 2020;32(3):200-7. doi: 10.36129/jog.32.03.06.
7. Attaran M, Falcone T, Goldberg J. Endometriosis: still tough to diagnose and treat. *Cleve*

- Clin J Med. 2002;69(8):647-53. doi: 10.3949/ccjm.69.8.647.
8. Attaran S, Bille A, Karenovics W, Lang-Lazdunski L. Videothoroscopic repair of diaphragm and pleurectomy/abrasion in patients with catamenial pneumothorax: a 9-year experience. *Chest*. 2013;143(4):1066-9. doi: 10.1378/chest.12-1558.
 9. Azizad-Pinto P, Clarke D. Thoracic endometriosis syndrome: case report and review of the literature. *Perm J*. 2014;18(3):61-5. doi: 10.7812/TPP/13-154.
 10. Channabasavaiah AD, Joseph JV. Thoracic endometriosis: revisiting the association between clinical presentation and thoracic pathology based on thoracoscopic findings in 110 patients. *Medicine (Baltimore)*. 2010;89(3):183-8. doi: 10.1097/MD.0b013e3181df67d5.
 11. Guenther TM, Gustafson JD, Pribyl SM, Wozniak CJ. Recurrent Spontaneous Pneumothorax in a 47-Year-Old Woman. *Mil Med*. 2020;185(9-10):e1833-5. doi: 10.1093/milmed/usz468.
 12. Aissa S, Benzarti W, Alimi F, Gargouri I, Salem HB, Aissa A, et al. Catamenial pneumothorax revealing diaphragmatic endometriosis: a case report and revue of literature. *Pan Afr Med J*. 2017;27:112. doi: 10.11604/pamj.
 13. Segawa M, Touge M, Kusajima Y, Saito K. Catamenial pneumothorax due to diaphragmatic endometriosis confirmed by histological examination; report of a case. *Kyobu Geka*. 2011;64(5):430-3.
 14. Schoenfeld A, Ziv E, Zeelel Y, Ovadia J. Catamenial pneumothorax-a literature review and report of an unusual case. *Obstet Gynecol Surv*. 1986;41(1):20-4. doi: 10.1097/00006254-198601000-00003.
 15. Yoshioka H, Fukui T, Mori S, Usami N, Nagasaka T, Yokoi K. Catamenial pneumothorax in a pregnant patient. *Jpn J Thorac Cardiovasc Surg*. 2005;53(5):280-2. doi: 10.1007/s11748-005-0042-6.
 16. Rousset-Jablonski C, Alifano M, Plu-Bureau G, Camilleri-Broet S, Rousset P, Regnard JF, et al. Catamenial pneumothorax and endometriosis-related pneumothorax: clinical features and risk factors. *Hum Reprod*. 2011;26(9):2322-9. doi: 10.1093/humrep/der189.
 17. Visouli AN, Darwiche K, Mpakas A, Zarogoulidis P, Papagiannis A, Tsakiridis K, et al. Catamenial pneumothorax: a rare entity? Report of 5 cases and review of the literature. *J Thorac Dis*. 2012;4 Suppl 1(Suppl 1):17-31. doi: 10.3978/j.issn.2072-1439.2012.s006.
 18. Alifano M, Trisolini R, Cancellieri A, Regnard JF. Thoracic endometriosis: current knowledge. *Ann Thorac Surg*. 2006;81(2):761-9. doi: 10.1016/j.athoracsur.2005.07.044.
 19. Marjański T, Sowa K, Czapla A, Rzyman W. Catamenial pneumothorax - a review of the literature. *Kardiochir Torakochirurgia Pol*. 2016;13(2):117-21. doi: 10.5114/kitp.2016.61044.
 20. Alifano M, Legras A, Rousset-Jablonski C, Bobbio A, Magdeleinat P, Damotte D, et al. Pneumothorax recurrence after surgery in women: clinicopathologic characteristics and management. *Ann Thorac Surg*. 2011;92(1):322-6. doi: 10.1016/j.athoracsur.2011.03.083.