



Italian Journal of Gynaecology & Obstetrics

June 2023 - Vol. 35 - N. 2 - Quarterly - ISSN 2385 - 0868

Cervicovaginal fibroids: a systematic review for a comprehensive management plan

Graziella Moufawad¹, Giovanni Buzzaccarini², Krystle Abboud¹, Elena Nasr¹, Maurina Geru³, Zaki Sleiman^{1,*}

¹ Department of Obstetrics and Gynecology, The Lebanese American University LAU and LAU Medical Center-Rizk Hospital, Beirut, Lebanon.

² Obstetrics and Gynaecology Unit, IRCCS San Raffaele Scientific Institute, Milan, Italy.

³ Department of Women's and Children's Health, Gynaecologic and Obstetrics Clinic, University of Padua, Padua, Italy.

ARTICLE INFO

History

Received: 08 February 2022

Received in revised form: 02 May 2022

Accepted: 27 May 2022

Available online: 07 June 2023

DOI: 10.36129/jog.2022.41

Key words

Cervicovaginal myoma; laparoscopy; myomectomy.

***Corresponding author:** Zaki Sleiman, Assistant Professor, M.D. Department of Obstetrics and Gynecology, The Lebanese American University LAU and LAU Medical Center-Rizk Hospital, Zahar Street, 11-3288 Beirut, Lebanon.
Email: zakinexus@hotmail.com.
ORCID: 0000-0002-9663-9217.

ABSTRACT

Objective. Leiomyomas are the most common benign tumours of the female genital tract. However, cervical leiomyomas are rare, with a prevalence of only 0.6%. The aim of this article is to provide a general treatment plan in the management of cervical leiomyomas and the special considerations to be accounted for, such as hymen integrity and size limits.

Materials and Methods. We performed a systematic review about the argument cervical leiomyomas. A total of 19 articles were included.

Results. The location of cervicovaginal leiomyomas near important organs and vessels makes the approach to their management more critical. Traditionally, a vaginal approach was considered the gold standard for cervicovaginal myomectomy. However, hymen integrity in some societal cultures makes a vaginal approach more difficult. It is for this reason that surgeons usually switch to traditional laparotomy or, more recently, to laparoscopy.

Conclusions. With the advancement in endoscopy and its application in gynaecologic surgery, laparoscopy has become a feasible option. In addition, the size of the cervicovaginal leiomyoma is a determining factor for the management approach and choice of appropriate surgical technique.

INTRODUCTION

Leiomyomas are the most common benign tumours of the uterus and the female genital tract. 95% of the leiomyomas occur in the uterine corpus, while cervical leiomyomas are infrequent with a prevalence of 0.6% [1]. Cervical fibroids can arise from the supracervical or vaginal portion of the cervix [2]. Classic symptoms of myomas include chronic pelvic pain, abnormal uterine bleeding, dysmenorrhea, and they can sometimes lead to infertility [3]. However, the vast majority of women with uterine myomas are asymptomatic. In 2018, the Global Congress on Hysteroscopy Scientific Committee drew up the recommendations on management of asymptomatic submucous myomas (SMs) in patients of reproductive age; surgical interventions were more frequently recommended mainly when immediate fertility was a priority [4].

According to the European Society of Hysteroscopy, there are three types of submucous myomas depending on the degree of myometrial invasion [5]. The pedunculated/prolapsed submucous myoma without intramural extension is classified as type 0 fibroid [6] and the first successful vaginal myomectomy for prolapsed pedunculated submucous leiomyomas was done by Atlee in the 1845 [7]. This approach is short, safe, simple and it is the preferred method of removing small prolapsed myomas. Many techniques, both medical and surgical [8], have been suggested including hysteroscopic resection of the fibroid peduncle or non-hysteroscopic cutting or twisting of the peduncle and morcellation or vaporization of the myoma nodule [9]. Other methods include a laparoscopic approach for excision of pedunculated submucous cervicovaginal myomas, especially when preserving hymen integrity is a main concern. In this regard, new possible insights deriving from minimally invasive gynaecology are feasible for future possibilities [10, 11]. However, when large myomas need to be removed, the size becomes a determining factor affecting the route and method of fibroid excision. On this scenario, the aim of this article is to summarize the evidence of treatment plan in the management of cervical leiomyomas and the special considerations to be accounted for.

METHODS

We performed a systematic review using the electronic databases ScienceDirect, MEDLINE, Scopus,

Embase, the Cochrane Library, ClinicalTrials.gov, EU Clinical Trials Register and World Health Organization International Clinical Trials Registry regarding the management approach of cervicovaginal myomectomy. We searched for articles until the 12/23/2021. Keywords used for the search were cervicovaginal, fibroid, hymen, large fibroid. A total of 19 articles were included such as systematic reviews, clinical studies, retrospective and prospective studies, cross sectional studies, 9 case reports, case series, and a narrative review.

RESULTS

Vaginal access feasibility

Traditionally, laparotomy and mini-laparotomy were the main myomectomy procedures performed. Less invasive substitutes that allow fertility and uterus sparing were introduced with endoscopic techniques such as laparoscopy, hysteroscopy and robotic surgery. The latter has ample room for development in the future due to its rapid progress [12]. Initially, vaginal myomectomy was frequently disregarded even if it offered some advantages over laparoscopy. Actually, this procedure did not prove to be feasible nor safe [13]. Some complications can occur with this approach: blood loss, injury to organs [14] or in some cases even a uterine inversion [15]. However, the vaginal pathway, as a natural orifice surgery, allows the treatment of both gynaecologic and some digestive diseases. Thus, cervicovaginal fibroid removal by means of vaginal access has been considered the gold standard of treatment. Rolli *et al.* compared the vaginal myomectomy with the laparoscopic approach [13] and they found that vaginal myomectomy is a safe and feasible procedure when performed by an expert, with shorter operative time, rapid recovery, no abdominal skin incision, no carbon dioxide required which allows locoregional anaesthesia and with tactile discrimination. They also reported that prior culdoscopic evaluation using a flexible fibre-optic is less invasive than laparoscopy.

Hysteroscopy, especially for small myomas, is the most common approach. A hysteroscopy can even be attempted in the doctors office in order to avoid general anaesthesia and the use of an operating room, generating cost savings and greater compliance among patients [16]. Submucous (SM) or intracavitary myomas are easily visualized, but they

can be removed utilizing several methods: resection with the resectoscope is the most common extraction method, but the learning curve can be challenging. In this regard, morcellation may reduce the learning curve and complication rate of hysteroscopic myomectomy for SM [17]. In addition, a multicentre prospective study demonstrated that an in office hysteroscopic myomectomy with SM enucleation without mass extraction appears safe, well-tolerated, and effective in at least 89% of patients [18].

Although all of the cases of uterine fibroid in adolescents were traditionally treated by laparotomy, Taskin *et al.* reported the case of hysteroscopic resection of a cervical fibroid protruding through the hymen in an adolescent patient. However, for the cardinal importance of future childbearing preservation, a minimally invasive vaginal approach was followed. After the removal of the protruding part, entry by hysteroscopy allowed the localization of the base of the myoma and its resection without any complications [19].

In another study, Rajshe *et al.* concluded that the best surgical approach for cervical fibroid removal with fertility preservation was intracapsular enucleation and dissection. This procedure would also prevent the injury to bladder and ureters, stressing the importance of surgical expertise, knowledge of anatomy, and the relation of fibroids to ureters and uterine arteries [20].

When virginity precludes vaginal access

Many cultural and religious beliefs consider virginity a highly significant sign of integrity and honour [21]. In some societies in the Middle East, women who lose their virginity before marriage are prone to extreme violence and humiliation as they are considered sexually impure [22]. Virginity, defined as an intact hymen, is therefore a major social concern, making vaginal access for surgical procedures in patients with intact hymenal ring unacceptable, and generates great concern for both the patient and the physician [9].

Although vaginal myomectomy is the recommended approach for isolated prolapsed pedunculated submucous myomas, hymenal integrity represents a major barrier for some virgin patients [6]. Few reports discussed the protection of hymenal integrity during operative vagino-hysteroscopy for resection of small pedunculated submucous myomas. However, this technique is limited while operating on large masses [23].

In the management of prolapsed pedunculated submucous leiomyoma in virgin patients, several reports have been published. In the first, a 30-year-old, nulliparous virgin Turkish woman was found to have on pelvic ultrasound a 5 × 6 cm solid mass in the cervicovaginal location filling the vaginal margins. Vaginal removal of the myoma was offered to the patient as a first line surgical approach, and the patient was informed about the risk of losing the integrity of the hymen during this intervention and about the possibility of hymenal repair during the procedure. Due to the consistent desire for preserving the hymenal integrity, a mini-laparotomy was performed. Upon inspection, a bulky appearance was found and palpated under the anterior wall of the vagina. A small incision was made anteriorly on the vaginal wall after releasing the bladder. A pedunculated 5 × 6 cm mass was found and removed with rotational movements after clamping the peduncle. The patient had a smooth post op course [9]. In the second report, a 20-year-old, nulliparous virgin Lebanese girl was found to have on pelvic ultrasound a 5 × 5 cm prolapsed pedunculated submucous leiomyoma. Vaginal removal of the myoma was offered to the patient as a first line surgical approach, and she was informed about the risk of losing the integrity of the hymen during this intervention as well as the possibility of hymenal repair directly after the termination of the intervention. Due to the strong desire of maintaining the integrity of the hymen, a laparoscopic abdominal approach was adopted. Upon inspection of the pelvic structures, a bulky appearance was found under the posterior vaginal wall whereby a small vertical incision was done. A firm pedunculated mass was found and sectioned at its peduncle. The 5 × 5 cm mass was then delivered through the incision and extracted by an electrical morcellator without any complications and with a smooth post op course [23].

In the third report, a young patient with an intact hymen was found to have a symptomatic vaginal fibroid of 4 × 4 cm with bilateral endometriomas. The patient consented to undergo a laparoscopic abdominal approach for hymen integrity issues. Frozen pelvis was noted intra op. Adhesions in the cul de sac was a major barrier to posterior entry, so the decision for an anterior colpotomy was taken: the bladder was dissected anteriorly until reaching the vaginal bulge due to the mass effect. An anterior vertical vaginal incision was done, and the fibroid was extracted through the peritoneal cavity with a smooth post operative course [21].

As a conclusion, classical surgical approaches are not always the answer. Although vaginal myomectomy/hysteroscopy with the vaginoscopic approach is considered the first line treatment for cervicovaginal fibroids, respecting some social considerations might hinder the feasibility of this approach. This technique is usually successful in resecting small myomas. Operating on large masses with hymen conservation can be done through laparotomy or laparoscopic approaches. In the presence of a skilled laparoscopic surgeon, a minimally invasive approach is an alternative to laparotomy with better outcomes. Laparoscopic posterior colpotomy avoids the unnecessary dissection of the bladder. However, if the posterior approach is impossible due to adhesions in the cul de sac, dissection of the bladder must be done with an anterior colpotomy.

When size is the main issue

As already discussed above, vaginal myomectomy/hysteroscopy is the gold standard for the treatment of cervicovaginal fibroids except when hymen integrity, due to social concerns, prevents such an approach. However, another limiting factor for fibroid excision is its size. The traditional management for patients with symptomatic large fibroids is surgery. However, an initial medical treatment is the preferred approach. Starting with Selective estrogen receptors modulators (SERMs) or Gonadotropin Hormone Releasing Factor (GnRH) agonists to reduce the size of the fibroid is usually recommended. Uterine artery embolization is also another non-invasive option. When these large fibroids are causing symptoms such as infertility, abnormal uterine bleeding or severe pelvic pain the preferred approach is surgery whether by laparoscopy or laparotomy [25].

Concern has been attributed to laparoscopic myomectomy especially when large fibroids exist. A longer operative time, increased blood loss, and ease of repair of myometrial defects are the major concerns with laparoscopy. Nuri *et al.* published a video article describing the case of a 40-year-old lady with a 10 × 14 cm cervicovaginal fibroid causing infertility and chronic pelvic pain. The fibroid weighed 670 g and was successfully removed using laparoscopy via a posterior cul de sac colpotomy. Delivery of the fibroid was done through the cervix after morcellation and then suturing. This report revealed the feasibility and safety of large

fibroid removal located in difficult locations such as the cervix via laparoscopy especially when performed by “experienced hands” [26].

Similarly, Yabumoto *et al.* described the laparoscopic treatment of a large pedunculated submucous fibroid in a 47-year-old woman with a uterine fundus palpable 3 cm above the umbilicus. Laparoscopic uterine artery ligation was performed, followed by transvaginal removal of the fibroid via twisting and then total hysterectomy. There were no intra operative complications and the patient had a smooth post op course. Thus, this approach may be a feasible option for large cervicovaginal fibroids [22].

Vaginal myomectomy of a large fibroid is also feasible via morcellation and bisection. Magos *et al.* described two cases of large vaginal fibroids in nulliparous young women who had symptoms such as pelvic pain and pressure, and abnormal uterine bleeding. Those patients were first treated with a trial of Luteinizing Hormone Releasing Factor (LHRH), but no success was attained at decreasing the size of the myoma. So, the team switched to a vaginal approach whereby a posterior colpotomy was performed, the fibroid grabbed and removed via morcellation and bisection. The successful removal of the fibroid was followed by the suturing of the colpotomy site. The authors concluded that the vaginal approach for myomectomy in cases of large fibroids is feasible even in nulliparous women by using morcellation and bisection. This technique makes use of the vagina as a “natural gateway to the pelvis” and allows easy and safe access to cervicovaginal fibroids, irrespective of their size [27].

In pregnancy, cervicovaginal fibroids are rare, yet they can occur. Uterine fibroids seem to be subject to a non-linear trend of modifications during pregnancy and puerperium, which may vary from myoma to myoma. Adequate evidence supports uterine fibroid systematic enlargement during the first trimester of pregnancy, while inconsistent evidence is available about the changes of uterine fibroids during second and third trimesters. In addition, the overall modifications of myomas during pregnancy and puerperium remain unclear [28].

Remon Kerikos *et al.* reported the case of a 29-year-old pregnant woman who had an enlarging cervicovaginal fibroid reaching a size “larger than the head of the baby”. The fibroid degenerated and decreased in size post-partum, after which vaginal myomectomy was successfully performed without any repercussions. The patient was fine and was able to get pregnant once again after this procedure [29].

In conclusion, the size of the fibroid is a determining factor which alters the surgical approach for a cervicovaginal fibroid removal. However, several surgical approaches have been proven safe and feasible in the excision of the latter depending on the location, size, patient factors and surgeon's expertise. For this reason, a summary of our management plan is presented in **Figure 1**.

DISCUSSION

The analysis of the selected articles in this systematic review, allowed us to achieve a clearer comprehension of the best surgical technique to choose according to the characteristics of cervicovaginal myomas or woman's requirements, thus facilitating the decision-making process. Cervicovaginal myoma's size and location, preservation of the hymen integrity and pregnancy are the variables considered.

Traditionally, myomectomy has been performed via laparotomy. Recently, with the development of new techniques, submucous fibroids have started being removed via hysteroscopy, especially if the size is small [27]. Hysteroscopy, as one stop approach for diagnosis and treatment, is achievable in almost 50% of cases. It is a minimally invasive, low risk, well tolerated and cost and time effective procedure [30]. The surgical treatment of cervico-

vaginal myomas is considered more challenging and requires a great expertise on the part of the surgeon due to its critical location. Its position in the pelvis close to the bladder, rectum or ureters makes it a delicate surgery with an increased operative time solely due to its location [31]. Another risk during the surgical procedure is increased intraoperative bleeding due to two major factors: neovascularization of the fibroid itself, and the cervicovaginal location adjacent to the uterine arteries and vessels [32].

According to Peker *et al.*, cervicovaginal myomectomy should be performed via a vaginal approach unless other indications necessitate an abdominal approach [25]. This is a safe procedure for symptomatic relief of a prolapsed submucous pedunculated fibroid. If the size is small, a speculum can be used to visualize and thus remove the prolapsed fibroid after twisting it with a forceps or via hysteroscopy. Endoscopic surgery is very successful in these cases, but hysteroscopy is limited to 5 cm fibroids; otherwise, a switch to laparotomy or recently laparoscopy is an alternative [27].

Concern ensues when the fibroid is large or when the patient is a virgin who is not willing to jeopardize the integrity of her hymen due to social concerns. In the case of an intact hymen, a vaginoscopy or hysteroscopy with a mini-resectoscope can be easily performed without any concern. However, if the fibroid is large and cannot be delivered

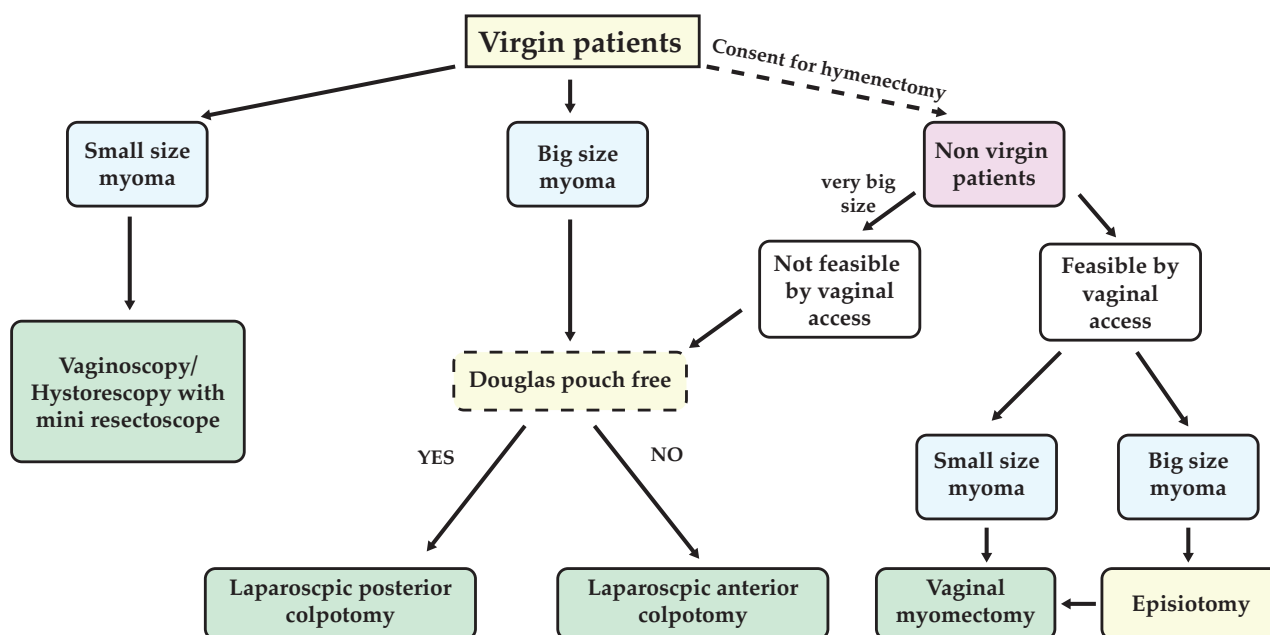


Figure 1. Cervicovaginal fibroids management plan according to the authors.

through the vagina, laparoscopy is the next step to be performed. After entry and inspection with the laparoscope, two options are available in order to reach the fibroid: either through a posterior colpotomy or through an anterior incision. Usually, a posterior colpotomy is the preferred initial approach technique if the posterior cul de sac is free. Otherwise, the surgeon would resort to an anterior colpotomy to grasp and remove the fibroid. Using laparoscopy, hymen integrity would be preserved in virgin patients, and the patient's autonomy would be respected.

The problem with large fibroids is not only their size. Large cervicovaginal fibroids can distort the anatomy of the pelvis, diverting the ureters, and engorging the uterine artery and vein rendering the surgical approach much more difficult [30]. Large fibroids can be initially managed medically either with GnRH agonists or SERMs to reduce the size of the fibroid and thus make it a better candidate for surgery. Uterine artery embolization is also an option. This decreases operative time, blood loss, and intra and post operative complications. A large fibroid is not only an issue in virgin patients. A moderately large fibroid can be delivered vaginally via vaginal myomectomy techniques with the aid of an episiotomy. Morcellation and bisection are also helpful tools which make vaginal myomectomy of a large fibroid feasible [21].

If the cervicovaginal fibroid is very large, vaginal access is not possible. In this case, laparoscopy would be the most appropriate procedure, and consequently entry initially with a posterior colpotomy if the Douglas pouch is free, or anterior colpotomy otherwise. Intriguingly, a recent paper speculated about the feasibility of laparoscopic hysterectomy for enlarged uteri, which can be related also to cervicovaginal fibroids. Indeed, this retrospective study presented a scenario where the uterine weight is not a predictive value for laparotomic conversion [33].

Cervical fibroids during pregnancy are rare, and only three cases about sessile cervicovaginal fibroids have been reported in pregnancy [26]. Cervicovaginal fibroids have been associated with pregnancy complications. Oruc *et al.* reported the case of a pregnant lady who presented at 18 weeks of gestation with Preterm Premature Rupture of Membranes (PPROM). She was found to have a 5 cm cervicovaginal fibroid. 12 hours later, no foetal heart rate was detected. This complication has been indirectly linked to the cervicovaginal fibroid [29].

Pedunculated cervicovaginal fibroids can increase in size and cause recurrent vaginal bleeding during pregnancy and can thus be removed vaginally during pregnancy [26]. Sessile cervicovaginal fibroids are very rare during pregnancy but need close monitoring since they can lead to complications such as Spontaneous Rupture of Membranes (SRM). Post myomectomy, women should be screened for cervical length in their future pregnancy and might need a prophylactic cerclage [26].

Because of the rarity of cervical-vaginal fibroids, there is still no standardized protocol on their management. In this article we highlighted some factors that should be taken into account to choose the most appropriate surgical technique on the basis of to the scientific literature currently available. Overall, the complication rate when treating cervicovaginal fibroids is considered low (5.6%), therefore a surgical approach is considered safe and feasible when performed by an expert surgeon and when choosing the most appropriate approach.

CONCLUSIONS

In conclusion, cervicovaginal leiomyomas are challenging scenarios for surgeons and tailored treatments should be considered. Other than location, the size of the cervicovaginal leiomyoma is a determining factor for the management approach and choice of appropriate surgical technique. In virgin patients vaginoscopy and hysteroscopy are feasible for small size myoma; laparoscopy is the first choice for big size myoma. If the consent for hymenectomy is achieved, vaginal approach is preferred with the possibility of practicing an episiotomy if the myoma is too large or of converting to laparoscopy if the myoma is not accessible.

COMPLIANCE WITH ETHICAL STANDARDS

Authors contribution

Z.S.: Conceptualization. K.A., E.N.: data curation, methodology, results analysis. Z.S., M.G., G.B.: Writing – original draft, writing – review & editing.

Funding

None.

Study registration

N/A.

Disclosure of interests

The authors declare that they have no conflict of interests.

Ethical approval

N/A.

Informed consent

N/A.

Data sharing

All data are provided within this article.

REFERENCES

1. Tiltman AJ. Leiomyomas of the uterine cervix: a study of frequency. *Int J Gynecol Pathol.* 1998;17(3):231-4. doi: 10.1097/00004347-199807000-00006.
2. Katke RD, Thakre N, Mourya S, Acharya S. Cervical Fibroids with Its Management and Review of Literature: An Original Article. *SEAJCRR.* 2017;6(1):5-9.
3. Laganà AS, Vergara D, Favilli A, La Rosa VL, Tinelli A, Gerli S, et al. Epigenetic and genetic landscape of uterine leiomyomas: a current view over a common gynecological disease. *Arch Gynecol Obstet.* 2017;296(5):855-67. doi: 10.1007/s00404-017-4515-5.
4. Laganà AS, Alonso Pacheco L, Tinelli A, Haimovich S, Carugno J, Ghezzi F, et al. Management of Asymptomatic Submucous Myomas in Women of Reproductive Age: A Consensus Statement from the Global Congress on Hysteroscopy Scientific Committee. *J Minim Invasive Gynecol.* 2019;26(3):381-3. doi: 10.1016/j.jmig.2018.06.020.
5. Wamsteker K, Emanuel MH, de Kruif JH. Transcervical hysteroscopic resection of submucous fibroids for abnormal uterine bleeding: results regarding the degree of intramural extension. *Obstet Gynecol.* 1993;82(5):736-40. Available at: <https://pubmed.ncbi.nlm.nih.gov/8414318/>.
6. Golan A, Zachalka N, Lurie S, Sagiv R, Glezerman M. Vaginal removal of prolapsed pedunculated submucous myoma: a short, simple, and definitive procedure with minimal morbidity. *Arch Gynecol Obstet.* 2005;271(1):11-3. doi: 10.1007/s00404-003-0590-x.
7. Thompson JD, Rock JA. Leiomyomata uteri and myomectomy. In: Thompson JD, Rock JA (eds), *The Linde's operative gynecology*, 8th edn. 1997. Lippincott-Raven, New York, pp 731-70.
8. Dababou S, Garzon S, Laganà AS, Ferrero S, Evangelisti G, Noventa M, et al. Linzagolix: a new GnRH-antagonist under investigation for the treatment of endometriosis and uterine myomas. *Expert Opin Investig Drugs.* 2021;30(9):903-11. doi: 10.1080/13543784.2021.1957830.
9. Yalçın I, Pabuçcu E, Kahraman K, Sönmezer M. Mini-laparotomic Colpotomy for a Cervicovaginal Leiomyoma: Preservation of hymenal integrity. *Int J Reprod Biomed.* 2016;14(3):217-20. Available at: <https://www.ncbi.nlm.nih.gov/pmc/articles/PMC4899768/>.
10. Buzzaccarini G, Stabile G, Török P, Petousis S, Mikuš M, Della Corte L, et al. Surgical Approach for Enlarged Uteri: Further Tailoring of vNOTES Hysterectomy. *J Invest Surg.* 2022;35(4):924-5. doi: 10.1080/08941939.2021.1967528.
11. Buzzaccarini G, Noventa M, D'Alterio MN, Terzic M, Scioscia M, Schäfer SD, et al. vNOTES Hysterectomy: Can It Be Considered the Optimal Approach for Obese Patients? *J Invest Surg.* 2022;35(4):868-9. doi: 10.1080/08941939.2021.1939467.
12. Gitas G, Hanker L, Rody A, Ackermann J, Alkatout I. Robotic surgery in gynecology: is the future already here? *Minim Invasive Ther Allied Technol.* 2022;31(6):815-24. doi: 10.1080/13645706.2021.2010763.
13. Rolli R, Favilli A, Acanfora MM, Scuderi G, Di Renzo GC, Gerli S. Vaginal myomectomy is a safe and feasible procedure: a retrospective study of 46 cases. *J Obstet Gynaecol Res.* 2012;38(9):1201-5. doi: 10.1111/j.1447-0756.2012.01852.x.
14. Faivre E, Surroca MM, Deffieux X, Pages F, Gervaise A, Fernandez H. Vaginal myomectomy: literature review. *J Minim Invasive Gynecol.* 2010;17(2):154-60. doi: 10.1016/j.jmig.2009.12.007.
15. Della Corte L, Giampaolino P, Fabozzi A, Di Spiezio Sardo A, Bifulco G. An exceptional uterine inversion in a virgo patient affected by submucosal leiomyoma: Case report and review of the literature. *J Obstet Gynaecol Res.* 2019;45(2):466-72. doi: 10.1111/jog.13806.
16. Giampaolino P, Della Corte L, Di Filippo C, Mercurio A, Vitale SG, Bifulco G. Office hysteroscopy

- in the management of women with postmenopausal bleeding. *Climacteric*. 2020;23(4):369-75. doi: 10.1080/13697137.2020.1754389.
17. Vitale SG, Sapia F, Rapisarda AMC, Valenti G, Santangelo F, Rossetti D, et al. Hysteroscopic Morcellation of Submucous Myomas: A Systematic Review. *Biomed Res Int*. 2017;2017:6848250. doi: 10.1155/2017/6848250.
 18. Tanvir T, Garzon S, Alonso Pacheco L, Lopez Yarto M, Rios M, et al. Office hysteroscopic myomectomy without myoma extraction: A multicenter prospective study. *Eur J Obstet Gynecol Reprod Biol*. 2021;256:358-63. doi: 10.1016/j.ejogrb.2020.11.048.
 19. Taşkın S, Sönmezer M, Kahraman K, Atabekoğlu C. Hysteroscopic resection of uterine submucous leiomyoma protruding through hymen in a 16-year-old adolescent. *J Pediatr Adolesc Gynecol*. 2011;24(3):e77-8. doi: 10.1016/j.jpag.2010.08.001.
 20. Sleiman Z, Ayed A, Christoforou C, Petousis S, Alkatout I, Gitas G, et al. Posterior cervico-vaginal myomectomy: a laparoscopic technique. *Ital J Gynaecol Obstet*. 2023;35(1):21-5. doi: 10.36129/jog.2022.36.
 21. Sleiman Z, Moufawad G, Hubayter Z. The hymen conservation: "what seems obvious to some, can become complicated to others. The Society of Reproductive Surgeons. Available at: https://higherlogicdownload.s3.amazonaws.com/AS-RM/6a53b565-398a-4d9b-b7fc-208401ee3305/UploadedFiles/85t0YNTuSISXrXJPKUZQ_SRS%20Newsletter%20Spring%202021.pdf
 22. Yabumoto K, Ito F, Matsushima H, Mori T, Kusuki I, Kitawaki J. Massive prolapsed submucous fibroid treated with laparoscopic surgery: A case report. *J Obstet Gynaecol Res*. 2019;45(4):942-6. doi: 10.1111/jog.13901.
 23. Wehbe GS, Doughane M, Bitar R, Sleiman Z. Laparoscopic posterior Colpotomy for a Cervico-vaginal Leiomyoma: hymen conservative technique. *Facts Views Vis Obgyn*. 2016;8(3):169-171. Available at: <https://www.ncbi.nlm.nih.gov/pmc/articles/PMC5172573/>.
 24. Awwad J, Nassar A, Usta I, Shaya M, Younes Z, Ghazeeri G. Attitudes of Lebanese university students towards surgical hymen reconstruction. *Arch Sex Behav*. 2013;42(8):1627-35. doi: 10.1007/s10508-013-0161-6.
 25. Peker N, Gündoğan S, Şendağ F. Laparoscopic Management of Huge Cervical Myoma. *J Minim Invasive Gynecol*. 2017;24(3):345-6. doi: 10.1016/j.jmig.2016.09.002.
 26. Keriakos R, Maher M. Management of Cervical Fibroid during the Reproductive Period. *Case Rep Obstet Gynecol*. 2013;2013:984030. doi: 10.1155/2013/984030.
 27. Magos AL, Bournas N, Sinha R, Richardson RE, O'Connor H. Vaginal myomectomy. *Br J Obstet Gynaecol*. 1994;101(12):1092-4. doi: 10.1111/j.1471-0528.1994.tb13593.x.
 28. Vitagliano A, Noventa M, Di Spiezio Sardo A, Saccone G, Gizzo S, Borgato S, et al. Uterine fibroid size modifications during Pregnancy and puerperium: evidence from the first systematic review of literature. *Arch Gynecol Obstet*. 2018;297(4):823-35. doi: 10.1007/s00404-017-4621-4.
 29. Oruç S, Karaer O, Kurtul O. Coexistence of a prolapsed, pedunculated cervical myoma and pregnancy complications: a case report. *J Reprod Med*. 2004;49(7):575-7. Available at: <https://pubmed.ncbi.nlm.nih.gov/15305833/>.
 30. Jha S, Surabhi K. Hysteroscopy "As one stop approach" in the management of intrauterine pathology. Focus on patient's satisfaction. *Ital J Gynaecol Obstet*. 2021;33(2):102-9. doi: 10.36129/jog.33.02.04.
 31. Ferrari F, Forte S, Valenti G, Ardighieri L, Barra F, Esposito V, et al. Current Treatment Options for Cervical Leiomyomas: A Systematic Review of Literature. *Medicina (Kaunas)*. 2021;57(2):92. doi: 10.3390/medicina57020092.
 32. Liu WM, Wang PH, Chou CS, Tang WL, Wang IT, Tzeng CR. Efficacy of combined laparoscopic uterine artery occlusion and myomectomy via minilaparotomy in the treatment of recurrent uterine myomas. *Fertil Steril*. 2007;87(2):356-61. doi: 10.1016/j.fertnstert.2006.07.1497.
 33. Cianci S, Gueli Alletti S, Rumolo V, Rosati A, Rossitto C, Cosentino F, et al. Total laparoscopic hysterectomy for enlarged uteri: factors associated with the rate of conversion to open surgery. *J Obstet Gynaecol*. 2019;39(6):805-10. doi: 10.1080/01443615.2019.1575342.