



# Italian Journal of Gynæcology & Obstetrics

September 2022 - Vol. 34 - N. 3 - Quarterly - ISSN 2385 - 0868

## Convalescent plasma use in pregnant patients with COVID-19 related ARDS: a case report and literature review

Giuseppe Gullo<sup>1</sup>, Gaspare Cucinella<sup>1</sup>, Mario Tumminello<sup>2</sup>, Baldassare Renda<sup>3</sup>, Massimo Donzelli<sup>3</sup>, Vincenzo Lo Bue<sup>1</sup>, Donatella Termini<sup>2</sup>, Marianna Maranto<sup>1</sup>, Orazio De Tommasi<sup>4,\*</sup>, Francesco Tarantino<sup>3</sup>

<sup>1</sup> Department of Obstetrics and Gynecology, Villa Sofia Cervello Hospital, University of Palermo, Palermo, Italy.

<sup>2</sup> Department of Pediatrics, Villa Sofia Cervello Hospital, Palermo, Italy.

<sup>3</sup> Department of Anesthesia and Intensive Care II, Villa Sofia Cervello Hospital, Palermo, Italy.

<sup>4</sup> Department of Women's and Children's Health, Gynaecologic and Obstetrics Clinic, University of Padua, Padua, Italy.

### ARTICLE INFO

#### History

Received: 08 March 2022

Received in revised form: 26 March 2022

Accepted: 13 April 2022

Available online: 12 September 2022

DOI: 10.36129/jog.2022.32

#### Key words

Convalescent plasma; COVID19; interstitial pneumonia; pregnancy; preterm cesarean section.

\*Corresponding author: Orazio De Tommasi, M.D. Department of Women's and Children's Health, Gynaecologic and Obstetrics Clinic, University of Padua, via Giustiniani, 3, 35128 Padua, Italy.  
Email: odetommas@gmail.com.  
ORCID: 0000-0001-5890-9792.

### ABSTRACT

**Background.** Pregnancy does not appear to increase susceptibility to acquiring Severe Acute Respiratory Syndrome Coronavirus 2 (SARS-CoV-2) infection, but pregnant people with the infection appear to be at increased risk for developing severe disease. Furthermore, infected pregnant people, especially those who develop pneumonia, appear to have an increased frequency of preterm birth and cesarean delivery, alternatively to other causes of peripheral infection.

**Case presentation.** The aim of this report is to describe a case of a third trimester pregnant woman with severe acute respiratory syndrome COVID-19, undergoing endotracheal intubation with invasive mechanical ventilation due to respiratory distress with a 12-hour daily cycle of pronation. The patient was the first case in Sicily treated with convalescent plasma and underwent urgent preterm cesarean section.

**Conclusions.** Several agents are being evaluated for treatment of COVID-19, with minimal or no information on safety in pregnancy. Our data confirmed that pregnant women can be safely pronated with clinical improvement and blood gasses findings. Instead, after the use of convalescent plasma, we had only a partial and transitory improvement of patient's condition. Certainly, the timing of delivery should be discussed by a multidisciplinary team of obstetricians, anesthetists and neonatologists. In the future other studies on larger numbers of pregnant women with COVID-19 need to be conducted to better understand the correct maternal and fetus care and the effectiveness of the treatments available also for a specialized specific approach on the long-covid effects.

### INTRODUCTION

The Covid-19 pandemic from December 2019 until February 2022, has caused about 5.7 million deaths, with more than 400 million documented infections worldwide [1].

The infection is determined by the transmission of severe acute respiratory syndrome coronavirus 2 (SARS-CoV-2) through a human-to-human contact via respiratory droplets [2]; the course of the disease in some patients is characterized by a progression to acute respiratory distress syndrome

(ARDS) leading to a poor prognosis in several of them [3, 4].

In pregnant women a higher incidence of abortion, growth restriction, preterm births and fetal death are documented as well as a higher risk of admission to the intensive care unit (ICU) and mechanical ventilation [5, 6] with a significant psychological impact on patients [7, 8].

Convalescent plasma (CP) has been mentioned as one of the most promising therapeutic strategies for SARS-CoV-2 infection, while recent evidences have shown a poor association of CP with better clinical outcomes [9]. Pregnant women have been mostly excluded from clinical trials (except for few exceptions [10]); nevertheless, most of reports developed about the issue seem to support the beneficial maternal and fetal effects of CP as well as the safety of this treatment [11].

All the cases about pregnant women suffering from severe ARDS due to SARS-CoV-2 infection and treated with CP show maternal survival. In most of cases preterm cesarean sections has been needed [12-14] but in many cases normal ongoing of the pregnancy has been registered [15-17]. Just few cases showed intrauterine neonatal death as a consequence of the complicated maternal clinical picture [18,19].

Italy was the first western country hit by the Virus in March 2020 [20].

In this study, we present a case of a pregnant woman treated with CP, the first case registered in Sicily. The clinical case at issue has already been treated in another paper [21]. With the present work we go into detail of the obstetric management of the patient and neonatal management.

COVID-19 is caused by SARS-CoV-2 and includes a several characterization, from asymptomatic patients to respiratory failure, cardiovascular, thromboembolic and inflammatory complications. Pregnancy does not appear to increase susceptibility to this infection, but physiological changes during pregnancy, such as reduced functional residual volumes, diaphragm elevation and altered cell immunity may be an increased risk for severe disease, maternal intensive care unit admission and mechanical ventilation [22, 23]. Deaths have been reported equally in pregnant as in non-pregnant women of reproductive age [24], but, compared to healthy pregnant women, those with COVID-19 have an increased risk of preterm and cesarean delivery due to fever and hypoxemia [25].

We report a case of a third trimester pregnant woman with severe acute respiratory syndrome from COVID-19, undergoing urgent preterm cesarean section.

## CASE PRESENTATION

### *Clinical presentation*

A 34-year-old multipara woman at 27 weeks and 4 days of gestation, came to the hospital with fever, dyspnea and abdominal pain, rapidly worsening without clinical improvements after paracetamol intake. No comorbidities were mentioned in her medical history. At admission, a fetal ultrasound showed a live fetus with regular biometry, no evaluation of the fetal anatomy was carried out. Physical examination showed decreased breath sounds to both lungs basis. Furthermore, arterial blood gases (ABG) showed: pH 7.439; PaCO<sub>2</sub> 33.6 mmHg; PO<sub>2</sub> 38.9 mmHg; peripheral oxygen saturation (SpO<sub>2</sub>) 70% in room air. Body temperature was 39.5 °C, blood pressure 125/70 mmHg, pulse rate 124 bpm. The patient had severe hypoxia and a P/F (PaO<sub>2</sub>- FiO<sub>2</sub> ratio) of 64.4. The laboratory findings included a leukocyte count of 14 × 10<sup>3</sup> μl, neutrophils of 12.15 × 10<sup>3</sup> μl, lymphocytes of 1.22 × 10<sup>3</sup> μl, C-reactive protein of 14.47 mg/dl, lactate dehydrogenase (LDH) of 445 UI/ml, hypokalemia with 2.9 mEq/L, D-dimer of 474 ng/ml (normal value in pregnancy). The other examinations were within normal limits. Molecular nasopharyngeal swab for SARS-Cov-2 was performed with a positive result.

### *Maternal management and completion of delivery*

The patient was moved to a negative-pressure isolation room and O<sub>2</sub> flow was increased from initial 5 to 15 L/min and non-invasive ventilation (NIV) was attempted without improvement. So, she was moved to insensitive care unit (ICU) and a lung ultrasound showed thickening of the pleura and multiple irregular confluent pleural lines (B-lines) as from interstitial pneumonia. A high-flow nasal cannula oxygen therapy was attempted (FiO<sub>2</sub> between 80% and 90%; flow 60 lt/min; temperature at 31°C), but tachypnea persisted and the ABG worsened. Therefore, the patient was sedated and endotracheal intubation with invasive mechani-

cal ventilation was started. Venous thromboembolism prophylaxis with enoxaparin sodium and empiric antibiotic therapy with Clarithromycin and Ceftriaxone to prevent bacterial superinfection were began. It was subsequently substituted by Vancomycin because *Staphylococcus aureus* was isolated by bronchoalveolar lavage (BAL) and by hemoculture. Prophylaxis for neonatal Respiratory Distress Syndrome (RDS) was performed. Serial ultrasound assessments of fetal growth, amniotic fluid volume and Doppler in the umbilical artery were performed because development of fetal growth restriction has been described with other SARS infections [26]. The second day the patient was placed in prone position [27, 28] due to the persistence of respiratory failure. Supports and pads beneath shoulders and hips were used to prevent aortocaval compression. The patient started a 12-hour daily cycle of pronation and a progressive improvement of oxygenation was registered, allowing a FiO<sub>2</sub> decrease. The patient underwent a total of four cycles of pronation, lasting 12 hours each. The last cycle was performed on the fourth day of hospitalization, with no more consistent changes in respiratory parameters. The third day, after ethic committee's consent, a sack of CP was administered with improvement of clinical and laboratory findings. The next day a second sack of CP was administered without complications and with the increase of IgG and IgM in the following days. A chest radiography showed bilateral multiple ground-glass opacities confirming interstitial pneumonia. Lung ultrasounds were used for daily monitoring, to reduce the pregnant patient's exposure to ionizing radiations [29]. The fifteenth day the antibiotic therapy was modified with the addi-

tion of Meropenem because BAL was positive for *Pseudomonas aeruginosa*. The next day the BAL resulted negative for SARS-CoV-2, but chest radiography showed an increase of the bilateral opacities and hypoxia and hypercapnia worsened. The eighteenth day of hospitalization, at 31 weeks and 1 day of gestation, venous thromboembolism prophylaxis was discontinued and a cesarean section under general anesthesia (patient was already intubate) was performed without complications. The next day after cesarean section a chest CT scan of the mother confirmed the bilateral ground-glass opacities and broncovascular interstice thickening, ascribable to ARDS. The patient first underwent non-invasive ventilation by BIPAP ventilation and then a percutaneous tracheostomy was done. Then, the clinical conditions and laboratory findings improved gradually. Patient developed cytomegalovirus infection with also ocular localization, successfully treated with Acyclovir. Finally in the twenty-fifth day of hospitalization, the patient breathed spontaneously, and lung ultrasound showed an improvement of findings, confirmed at the next chest CT. After two weeks, a maternal chest X-ray showed a resolution of infiltrates of both lung fields. Patient was discharged after a total length of stay of 43 days (Figure 1), in good general conditions, afebrile, without any respiratory symptom/sign.

**Neonatal management**

A preterm female infant weighing 1400 gr was born with APGAR 3-6-7 at one, five and ten minutes. After two ventilation cycles with FiO<sub>2</sub> increasing from 21 to 30%, due to the lack of effective respiratory ac-

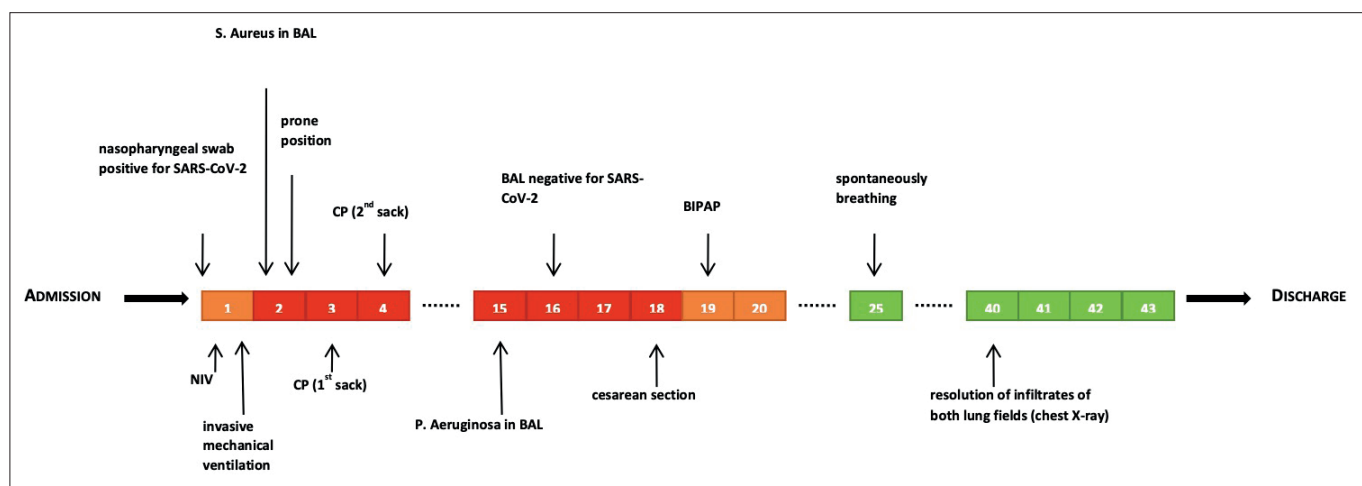


Figure 1. Timeline of total length of stay.

tivity, the infant was intubated and connected to a ventilator in synchronous positive pressure ventilation (SIPPV) with the following parameters: PIP 22 cmH<sub>2</sub>O, PEEP 5.5 cmH<sub>2</sub>O, FiO<sub>2</sub> 0.30, breath frequency 45 acts/min, SpO<sub>2</sub> 96% and pulse rate 146 beats for minutes. Two hours after birth, chest X-ray and pulmonary ultrasound showed the prevalence of confluent B lines, therefore surfactant was administered at 200 mg/kg. The baby was extubated 24 hours after birth and was placed in nasal continuous positive airway pressure (nCPAP) in ambient air. The newborn was undergone to swab and BAL for the detection of SARS-CoV2 with negative results at birth, 24 hours and 48 hours of life. The echocardiography showed the presence of bidirectional Botallo Arterial Duct, wide 3.5 mm, peri-membranous interventricular defect, large atrial foramen (3.5 mm), right ventricular chamber with normal contractility and slightly dilated pulmonary arterial trunk. The pulmonary bandaging was performed at 40 days of life. The child's conditions during hospitalization were satisfactory, with good weight gain. The three serological tests performed showed IgM anti SARS-CoV2 negative and a decreasing of IgG values due to probable transplacental passage.

## DISCUSSION

Majority of pregnant women experience only mild or moderate cold/flu-like symptoms, whereas shortness of breath, myalgia, sore throat and diarrhea are the less common symptoms [30]. Several studies revealed that pneumonia during pregnancy is associated with increased morbidity, mortality and obstetric complications with perinatal adverse outcomes especially due to changes in immune responses [31, 32]. The physiologic changes of pulmonary function during pregnancy are important to assess the severity of the disease and to guide ventilator FiO<sub>2</sub> parameters. Indeed, during pregnancy, maternal SpO<sub>2</sub> should be maintained greater than 95% and maternal PaO<sub>2</sub> greater than 70 mmHg is desirable to maintain a favorable oxygen diffusion gradient from the maternal to the fetal side of the placenta [33, 34].

When ARDS of any etiology occurs, prone positioning has proven beneficial effects on oxygenation and mortality [35]. Our data confirmed that pregnant women can be safely pronated, and this position improve clinical and blood gasses findings to relieve both diaphragmatic compression

from abdominal contents and aortocaval compression from the gravid uterus [36].

The use of CP for the treatment of acute viral illnesses is an established therapy that has previously shown benefit in the treatment of SARS, MERS, and Ebola virus patients [37]. Our patient's clinical conditions partially improved. Therefore, we think that it may be an efficient therapy, but probably complete benefit is reached when given early in the course of severe or life-threatening disease [38] and changes in immune response in pregnant women may influence complete response. Anyway, our case confirms the safety of convalescent plasma treatment in pregnant patients, as already described by a limited number of other papers [5, 39]. We observed that severe maternal respiratory disease is improved by delivery. Indeed, increased oxygen consumption and reduced functional residual capacity, which are normal in pregnancy, may facilitate maternal deterioration in patients with pneumonia [40]. So, delivery should be considered as a component of the management of refractory hypoxemic respiratory failure or worsening critical illness in pregnant women, based on multidisciplinary discussion with anesthesiologist, obstetricians and pediatricians to balance risk and benefit for maternal and fetal status.

We also confirmed that lung ultrasound examination is an accurate imaging method to detect pulmonary and pleural conditions useful especially to monitor pregnant women who require serial exams because it is a radiation free examination [41, 42]. Some studies report newborn infections and placental infections, so precautions during delivery were necessary to prevent the rare but possible vertical transmission [43, 44].

## CONCLUSIONS

In the future, other studies on larger numbers of pregnant women with COVID-19 need to be conducted to better understand the correct maternal and fetus care and the efficacy of several therapies.

## COMPLIANCE WITH ETHICAL STANDARDS

### *Authors contribution*

G.C., M.D., F.T.: Conceptualization. M.M., G.G., V.L.: Writing – original draft. O.D., M.T., B.R., G.B.: Writing – review & editing.

**Funding**

None.

**Study registration**

N/A.

**Disclosure of interests**

The authors declare that they have no conflict of interests.

**Ethical approval**

N/A.

**Informed consent**

Obtained.

**Data sharing**

Data are available under reasonable request to the corresponding author.

**REFERENCES**

1. Worldometers.info. Available at: <https://www.worldometers.info/coronavirus/>. Accessed on February 21, 2022.
2. Matta I, Laganà AS, Ghabi E, Bitar L, Ayed A, Petousis S, et al. COVID-19 transmission in surgical smoke during laparoscopy and open surgery: a systematic review. *Minim Invasive Ther Allied Technol.* 2022;31(5):690-7. doi: 10.1080/13645706.2021.1982728.
3. Ray Y, Paul SR, Bandopadhyay P, D'Rozario R, Sarif J, Raychaudhuri D, et al. A phase 2 single center open label randomised control trial for convalescent plasma therapy in patients with severe COVID-19. *Nat Commun.* 2022;13(1):383. doi: 10.1038/s41467-022-28064-7.
4. Carugno J, Di Spiezio Sardo A, Alonso L, Haimovich S, Campo R, De Angelis C, et al. COVID-19 Pandemic. Impact on Hysteroscopic Procedures: A Consensus Statement from the Global Congress of Hysteroscopy Scientific Committee. *J Minim Invasive Gynecol.* 2020;27(5):988-992. doi: 10.1016/j.jmig.2020.04.023.
5. Grisolia G, Franchini M, Glingani C, Inglese F, Garuti M, Beccaria M, et al. Convalescent plasma for coronavirus disease 2019 in pregnancy: a case report and review. *Am J Obstet Gynecol MFM.* 2020;2(3):100174. doi: 10.1016/j.ajogmf.2020.100174.
6. Franchi M, Bosco M, Barbieri B, Diani E, Lo Cascio G, Laganà AS, et al. Prevalence of SARS-CoV-2 infection in the obstetric population before the hospital admission. *Minerva Ginecol.* 2020;72(6):429-30. doi: 10.23736/S0026-4784.20.04654-7.
7. Franchi M, Del Piccolo L, Bosco M, Tosadori C, Casarin J, Laganà AS, et al. COVID-19 and mental health in the obstetric population: a lesson from a case of puerperal psychosis. *Minerva Ginecol.* 2020;72(5):355-7. doi: 10.23736/S0026-4784.20.04606-7.
8. La Rosa VL, Valenti G, Sapia F, Gullo G, Velasco María A, Rapisarda C. Psychological impact of gynecological diseases: the importance of a multidisciplinary approach. *J Gynaecol Obstet.* 2018;30:2. doi: 10.14660/2385-0868-86.
9. Troxel AB, Petkova E, Goldfeld K, Liu M, Tarpey T, Wu Y, et al. Association of Convalescent Plasma Treatment With Clinical Status in Patients Hospitalized With COVID-19: A Meta-analysis. *JAMA Netw Open.* 2022;5(1):e2147331. doi: 10.1001/jamanetworkopen.2021.
10. Bar KJ, Shaw PA, Choi GH, Aqui N, Fesnak A, Yang JB, et al. A randomized controlled study of convalescent plasma for individuals hospitalized with COVID-19 pneumonia. *J Clin Invest.* 2021;131(24):e155114. doi: 10.1172/JCI155114.
11. Franchini M, Prefumo F, Grisolia G, Bergamini V, Glingani C, Pisello M, et al. Convalescent Plasma for Pregnant Women with COVID-19: A Systematic Literature Review. *Viruses.* 2021;13(7):1194. doi: 10.3390/v13071194.
12. Pelayo J, Pugliese G, Salacup G, Quintero E, Khalifeh A, Jaspán D, et al. Severe COVID-19 in third trimester pregnancy: Multidisciplinary approach. *Case Rep Crit Care.* 2020;2020:8889487. doi: 10.1155/2020/8889487.
13. Jacobson J, Antony K, Beninati M, Alward W, Hoppe KK. Use of dexamethasone, remdesivir, convalescent plasma and prone positioning in the treatment of severe COVID-19 infection in pregnancy: A case report. *Case Rep Women's Health.* 2021;29:e00273. doi: 10.1016/j.crwh.2020.e00273.
14. Yaqoub S, Ahmad S, Mansouri Z, Pallivalapilla A, El Kassem W, Maslamani M, et al. Management of life-threatening acute respiratory

- syndrome and severe pneumonia secondary to COVID-19 in pregnancy: A case report and literature review. *Clin Case Rep* 2021;9(1):137-43. doi: 10.1002/ccr3.3485.
15. Moura LW, Liao AW, Negrini R, Zlotnik E. The use of convalescent plasma therapy in the management of a pregnant woman with COVID-19: a case report. *Einstein (Sao Paulo)*. 2022;20:eRC6550. doi: 10.31744/einstein\_journal/2022RC6550.
  16. Anderson J, Schauer J, Bryant S, Graves CR. The use of convalescent plasma therapy and remdesivir in the successful management of a critically ill obstetric patient with novel coronavirus 2019 infection: A case report. *Case Rep Womens Health*. 2020;27:e00221. doi: 10.1016/j.crwh.2020.e00221.
  17. Magallanes-Garza GI, Valdez-Alatorre C, Dávila-González D, Martínez-Reséndez MF, Sánchez-Salazar SS, Castilleja-Leal F, et al. Rapid improvement of a critically ill obstetric patient with SARS-CoV-2 infection after administration of convalescent plasma. *Int J Gynaecol Obstet*. 2021;152(3):439-41. doi: 10.1002/ijgo.13467.
  18. Pagan ME, Ramseyer AM, Whitcombe DD, Doiron TE, Magann EF, Sandlin AT, et al. Management of Critically Ill Pregnant Patients with COVID-19 Infection in a Rural State. *Am J Perinatol*. 2022;39(2):165-71. doi: 10.1055/s-0041-1739292.
  19. Zhang B, Liu S, Tan T, Huang W, Dong Y, Chen L, et al. Treatment With Convalescent Plasma for Critically Ill Patients With Severe Acute Respiratory Syndrome Coronavirus 2 Infection. *Chest*. 2020;158(1):e9-e13. doi: 10.1016/j.chest.2020.03.039.
  20. Lukanović D, Laganà AS. The impact of Covid-19 on simulation-based learning of gynecology and obstetrics skills. *Minim Invasive Ther Allied Technol*. 2022;31(5):684-9. doi: 10.1080/13645706.2021.1987923.
  21. Donzelli M, Ippolito M, Catalisano G, Renda B, Tarantino F, Diquattro O, et al. Prone positioning and convalescent plasma therapy in a critically ill pregnant woman with COVID-19. *Clin Case Rep*. 2020;8(12):3352-8. doi: 10.1002/ccr3.3426.
  22. Dashraath P, Wong JLJ, Lim MXK, Lim LM, Li S, Biswas A, et al. Coronavirus disease 2019 (COVID-19) pandemic and pregnancy. *Am J Obstet Gynecol*. 2020;222(6):521-31. doi: 10.1016/j.ajog.2020.03.021.
  23. Kasraeian M, Zare M, Vafaei H, Asadi N, Faraji A, Bazrafshan K, et al. COVID-19 pneumonia and pregnancy; a systematic review and meta-analysis. *J Matern Fetal Neonatal Med*. 2022;35(9):1652-9. doi: 10.1080/14767058.2020.1763952.
  24. Ellington S, Strid P, Tong VT, Woodworth K, Galang RR, Zambrano LD, et al. Characteristics of Women of Reproductive Age with Laboratory-Confirmed SARS-CoV-2 Infection by Pregnancy Status - United States, January 22-June 7, 2020. *MMWR Morb Mortal Wkly Rep*. 2020;69(25):769-75. doi: 10.15585/mmwr.mm6925a1.
  25. Khoury R, Bernstein PS, Debolt C, Stone J, Sutton DM, Simpson LL, et al. Characteristics and Outcomes of 241 Births to Women With Severe Acute Respiratory Syndrome Coronavirus 2 (SARS-CoV-2) Infection at Five New York City Medical Centers. *Obstet Gynecol*. 2020;136(2):273-82. doi: 10.1097/AOG.0000000000004025.
  26. Wong SF, Chow KM, Leung TN, Ng WF, Ng TK, Shek CC, et al. Pregnancy and perinatal outcomes of women with severe acute respiratory syndrome. *Am J Obstet Gynecol*. 2004;191(1):292-7. doi: 10.1016/j.ajog.2003.11.019.
  27. Oxford-Horrey C, Savage M, Prabhu M, Abramovitz S, Griffin K, LaFond E, et al. Putting It All Together: Clinical Considerations in the Care of Critically Ill Obstetric Patients with COVID-19. *Am J Perinatol*. 2020;37(10):1044-51. doi: 10.1055/s-0040-1713121.
  28. Tolcher MC, McKinney JR, Eppes CS, Mui-gai D, Shamshirsaz A, Guntupalli KK, et al. Prone Positioning for Pregnant Women With Hypoxemia Due to Coronavirus Disease 2019 (COVID-19). *Obstet Gynecol*. 2020;136(2):259-61. doi: 10.1097/AOG.0000000000004012.
  29. Moro F, Mascilini F, Buonsenso D, Inchingolo R, Smargiassi A, Soldati G, et al. Validation of the performance of "Fast Lung Ultrasound Teaching Program" for gynecologists/obstetricians dealing with pregnant women with suspicion of COVID-19 infection: an Italian prospective multicenter study. *Ital J Gynaecol Obstet*. 2021;33(1):52-6. doi: 10.36129/jog.33.01.06.
  30. Breslin N, Baptiste C, Gyamfi-Bannerman C, Miller R, Martinez R, Bernstein K, et al. Coronavirus disease 2019 infection among asymptomatic and symptomatic pregnant women: two weeks of confirmed presentations to an affiliated pair of New York City hospitals. *Am J Obstet Gynecol MFM*. 2020;2(2):100118. doi: 10.1016/j.ajogmf.2020.100118.

31. Goodnight WH, Soper DE. Pneumonia in pregnancy. *Crit Care Med.* 2005;33(10Suppl):S390-7. doi: 10.1097/01.ccm.0000182483.24836.66.
32. Warning JC, McCracken SA, Morris JM. A balancing act: mechanisms by which the fetus avoids rejection by the maternal immune system. *Reproduction.* 2011;141(6):715-24. doi: 10.1530/REP-10-0360.
33. Franchi M, Bosco M, Garzon S, Laganà AS, Cromi A, Barbieri B, et al. Management of obstetrics and gynaecological patients with COVID-19. *Ital J Gynaecol Obstet.* 2020;32(1):6-19. doi: 10.36129/jog.32.01.
34. Organization WH. Clinical management of severe acute respiratory infection (SARI) when COVID-19 disease is suspected" interim guidance 27 May 2020.
35. Guérin C. Prone positioning acute respiratory distress syndrome patients. *Ann Transl Med.* 2017;5(14):289. doi: 10.21037/atm.2017.06.63.
36. Schnettler WT, Al Ahwel Y, Suhag A. Severe acute respiratory distress syndrome in coronavirus disease 2019-infected pregnancy: obstetric and intensive care considerations. *Am J Obstet Gynecol MFM.* 2020;2(3):100120. doi: 10.1016/j.ajogmf.2020.100120.
37. Chen L, Xiong J, Bao L, Shi Y. Convalescent plasma as a potential therapy for COVID-19. *Lancet Infect Dis.* 2020;20(4):398-400. doi: 10.1016/S1473-3099(20)30141-9.
38. Li L, Zhang W, Hu Y, Tong X, Zheng S, Yang J, et al. Effect of Convalescent Plasma Therapy on Time to Clinical Improvement in Patients With Severe and Life-threatening COVID-19: A Randomized Clinical Trial. *JAMA.* 2020;324(5):460-70. doi: 10.1001/jama.2020.10044. Erratum in: *JAMA.* 2020;324(5):519.
39. Soleimani Z, Soleimani A. ADRS due to COVID-19 in midterm pregnancy: successful management with plasma transfusion and corticosteroids. *J Matern Fetal Neonatal Med.* 2022;35(16):3040-3. doi: 10.1080/14767058.2020.1797669.
40. Stephens AJ, Barton JR, Bentum NA, Blackwell SC, Sibai BM. General Guidelines in the Management of an Obstetrical Patient on the Labor and Delivery Unit during the COVID-19 Pandemic. *Am J Perinatol.* 2020;37(8):829-36. doi: 10.1055/s-0040-1710308.
41. Inchingolo R, Smargiassi A, Moro F, Buonsenso D, Salvi S, Del Giacomo P, et al. The diagnosis of pneumonia in a pregnant woman with coronavirus disease 2019 using maternal lung ultrasound. *Am J Obstet Gynecol.* 2020;223(1):9-11. doi: 10.1016/j.ajog.2020.04.020.
42. Buonsenso D, Raffaelli F, Tamburrini E, Biasucci DG, Salvi S, Smargiassi A, et al. Clinical role of lung ultrasound for diagnosis and monitoring of COVID-19 pneumonia in pregnant women. *Ultrasound Obstet Gynecol.* 2020;56(1):106-9. doi: 10.1002/uog.22055.
43. Deniz M, Tezer H. Vertical transmission of SARS CoV-2: a systematic review. *J Matern Fetal Neonatal Med.* 2022;35(14):2655-62. doi: 10.1080/14767058.2020.1793322.
44. Kirtsman M, Diambomba Y, Poutanen SM, Malinowski AK, Vlachodimitropoulou E, Parks WT, et al. Probable congenital SARS-CoV-2 infection in a neonate born to a woman with active SARS-CoV-2 infection. *CMAJ.* 2020;192(24):E647-E650. doi: 10.1503/cmaj.200821.