



Italian Journal of Gynaecology & Obstetrics

March 2023 - Vol. 35 - N. 1 - Quarterly - ISSN 2385 - 0868

Asymptomatic postmenopausal endometrial thickening: a comparison between transvaginal ultrasound and hysteroscopy in the diagnosis of intracavitary uterine pathologies

Patrizia Palermo^{1,*}, Alessandro Serva¹, Giulia Capannolo¹, Angela D'Alfonso¹, Stefano Necozone², Maurizio Guido¹

¹Department of Gynecology and Obstetrics, Department of Surgical Sciences, San Salvatore Hospital, L'Aquila, Italy.

²Department of Internal Medicine and Public Health, Clinical Epidemiology Unit, University of L'Aquila, L'Aquila, Italy.

ARTICLE INFO

History

Received: 09 January 2022

Received in revised form: 20 February 2022

Accepted: 29 March 2022

Available online: 21 March 2023

DOI: 10.36129/jog.2022.30

Key words

Bleeding; endometrium; thickening; hysteroscopy; ultrasound; menopause.

*Corresponding author: Patrizia Palermo, M.D., PhD. Department of Gynecology and Obstetrics, Department of Surgical Sciences, University of L'Aquila, piazza Salvatore Tommasi 1, Coppito, 67100 L'Aquila, Italy.
Email: patrizia.palermo@univaq.it.
ORCID: 0000-0002-6095-635X.

ABSTRACT

Objective. The aim of the study was to identify the cut-off of endometrial thickening for the early suspicion of malignancy and to demonstrate the superiority of hysteroscopy over ultrasound in the diagnosis of asymptomatic intracavitary uterine pathologies.

Patients and Methods. 105 women in menopausal state with endometrial thickening > 4 mm and without any symptoms were recruited. The patients then underwent hysteroscopy and received biopsy. The cut-off value for ultrasonography-measured endometrial thickening above which it would be possible to raise a more likely suspect of malignancy is 8 mm. Moreover, the single benign polyp is the most prevalent intracavitary uterine pathology.

Results. There isn't a statistically significant correlation between finding a homogeneous endometrial thickening upon ultrasonography and the presence of a benign polyp.

Conclusions. Hysteroscopy has to be considered the gold standard diagnostic exam.

INTRODUCTION

Postmenopausal Bleeding (PMB) is the main symptom in patients with endometrial thickening detected using transvaginal ultrasound, prompting the gynaecologist to perform a hysteroscopy [1, 2]. Absence of abnormal bleeding or total absence of other symptoms may be common with endometrial polyp [3, 4].

The risk of malignancy of the postmenopausal endometrial asymptomatic polyp has been thoroughly demonstrated not to exceed 1.2-1.5% [5, 6]. In most cases of postmenopausal endometrial carcinoma, the diagnosis is made in the presence of PMB (in this case the risk of malignancy is 2.2%). It is useful to provide an answer as to what is the prevalence of endometrial carcinoma in totally asymptomatic patients [7].

Based on the study by Smith-Bindmann *et al.*, the proportion of cases with diagnosis of endometrial carcinoma is not greater than 6.7% if the endometrium has a thickness > 11 mm, and it is 0.002% if the endometrium thickness measures < 11 mm [8].

An asymptomatic lesion, in fact, is not necessarily benign so it must always be studied. Among the more aggressive tumours of the uterus, for instance, there are the leiomyosarcomas (rare hysteroscopic diagnosis). They are rapidly metastatic but frequently asymptomatic [9]. Leiomyosarcomas, albeit rarely, can macroscopically affect the uterine cavity with a similar polypoid appearance or, if well differentiated, with characteristics much alike to a leiomyoma.

The Literature currently agrees on an ultrasound cut-off of 4 mm for endometrial thickness, above which hysteroscopy should be performed. Conversely, data are still uncertain about the cut-off above which the risk of malignancy should be considered increased. The group of patients more exposed to endometrial hyperplasia and carcinoma are postmenopausal women, under treatment for ER+breast cancer and especially taking Tamoxifen, for which many studies propose a 5 to 10 mm endometrial thickness cut-off for a suspect of malignancy [10, 11]. According to Perez-Medina, in fact, the endometrial atrophic pattern is the most common one during the first year of Tamoxifen therapy, occurring in 58.3% of patients [12]. The risk of endometrial cancer associated with the use of Tamoxifen was however reassessed in a study of 1,119 patients, with 681 women being treated with this drug. It demonstrated that Tamoxifen does not seem to be associated with a higher rate of endometrial cancer in women with breast cancer, in comparison with women treated with aromatase inhibitors or without treatment [13]. Endometrial biopsy plays a central role in diagnosis; thanks to it, hysteroscopy gains the title of gold standard diagnostic test. Ultrasound, on the other hand, has a screening function that can suggest possible histological diagnoses through main and soft markers. The main goal of this study is to demonstrate the crucial role of hysteroscopy in comparison with ultrasonography in the diagnosis of the intracavitary uterine pathologies in postmenopausal patients with asymptomatic thickening [14]. For this purpose, the ultrasound observations were initially compared to the hysteroscopic and histopathological ones. What is described above aims at an early diagnosis of endometrial cancer. In this sense, there are many open fields of research, especially in the context of biomarkers. The applicability of relative telomere length

(RTL) in cell-free DNA (cfDNA) as a tool for the early diagnosis of endometrioid endometrial cancer is being evaluated. It turns out to be shorter in women with malignant pathology in its early stages. Its diagnostic performance seems, however, unsatisfactory for cancer progression, staging and grading [15].

At the same time, the research is looking for reliable pre-surgical staging methods, like associating hysteroscopy with imaging techniques. The integration of magnetic resonance imaging and hysteroscopic biopsies showed an elevated accuracy and high rates of sensitivity (85.0%) and specificity (88.5%) in identifying low-risk patients who do not need comprehensive surgical staging without receiving lymphadenectomy [16]. The involvement of the lymph nodes is an important prognostic index, although it has no therapeutic utility in the early stages [17]. Furthermore, the presence of glandular cells (GC), detected at the preoperative cervical-smear, might predict the occurrence of local recurrence in endometrial cancer [18]. The diagnosis and treatment of endometrial cancer is still a research path to be followed and optimised.

PATIENTS AND METHODS

The cross-sectional observational study was performed at the Ultrasonography and Hysteroscopy Unit of the Gynaecology and Obstetrics Department of the San Salvatore Hospital in L'Aquila from February 2019 to February 2020. The patients were recruited following the incidental findings emerged during gynaecological or other medical checks. Inclusion criteria were:

- menopausal state (*i.e.*, amenorrhoea for at least 12 months);
- endometrial thickening (> 4 mm) found in transvaginal ultrasound that required diagnostic hysteroscopy with biopsy;
- absence of symptoms, particularly PMB.

For patients taking Tamoxifen and under treatment for breast cancer included in the study, an endometrial line exceeding 5 mm of thickness in transvaginal ultrasound was considered as endometrial thickening. Pre- or peri-menopausal patients, patients of childbearing age and patients with IUO (Internal Uterine Orifice) or EUO (External Uterine Orifice) stenosis were excluded from the study. Patients with cervical canal stenosis were excluded, since the diagnostic procedure required the execution of anaesthesia in the operat-

ing room with mechanical dilation of the cervical canal. This practice did not match our idea of an outpatient hysteroscopic diagnosis. We believe this distinction is fundamental, because the outpatient procedure suggested a clinical examination experienced by the patient in full comfort. The patient must experience as little pain as possible in order to have excellent compliance during intrauterine exploration. This can be obtained by reducing the waiting time before hysteroscopy (usually less than 30 minutes) to stop the feelings of anxiety and fear that lead patients to a prejudiced attitude [19]. All the patients underwent check-up transvaginal ultrasound, without PMB, which showed the presence of asymptomatic endometrial thickening upon examination. For this purpose, a cut-off of 5 mm was established for the patients taking Tamoxifen and under treatment for breast cancer; a cut-off of 4 mm was established for all the other patients. A GE Voluson E6 ultrasonograph (GE Medical System, Zipf, Austria) was used for the ultrasonography, carrying out the exam with the patient in lithotomy position and with empty bladder with a 5-9 MHz 2D transvaginal probe. To measure the endometrial thickness, a medial longitudinal scan of the uterus was obtained to visualize its full extension from the fundus to the internal uterine orifice. In this scanning, we defined the endometrium thickness as the maximum thickness along the line that connects the proximal to the distal myometrial-endometrial junction, perpendicular to the endometrial axis. In presence of intracavitary fluid, the thickness of the two individual endometrium layers was calculated and then summed up. The homogeneity or the inhomogeneity of the endometrium was also taken into account, in an attempt to further demonstrate that finding a homogeneous endometrial thickening upon ultrasound examination cannot be associated with a higher suspicion of endometrial benign polyp. In fact, the comparison with the statistically analysed hysteroscopic and histopathological observations does not confirm this association. All the ultrasound exams were performed by the same operator.

The patients underwent hysteroscopy upon signing informed consent. The exam was conducted in the clinic, without pharmacological premedication nor local anaesthesia. The hysteroscopy was performed using a compact hysteroscope, the CAMPO TROPHYSOPE (Karl Storz, Germany), with 2.9 mm lens, Hopkins 30° optic system, in continuous flow operating mode via an external jacket with an operating channel 5 Fr, a 175 W Xenon light source (Karl Storz),

a digital endocamera connected to a screen monitor, and a 0.9% saline solution as a means for expanding the endocervix and the uterine cavity. Targeted biopsies were also performed using operational tools 5 Fr (grasping forceps, tenaculum forceps, crocodile forceps). For the patients with > 15 mm uterine neoformations (mainly polyps and myomas), the election treatment of resectoscope in analgesia was programmed, in addition to performing the biopsy. For the purposes of the study, the hysteroscopic findings were divided in the following 8 categories: normal endometrium (endometrium which is not yet totally atrophic), atrophic endometrium, single benign polyp, multiple polyps, myoma, focal hyperplasia, diffuse hyperplasia, and endometrial carcinoma. The so classified hysteroscopic samples were sent to the Pathological Anatomy Operating Unit of the San Salvatore Hospital in L'Aquila and analysed according to the WHO (World Health Organization) criteria.

A preliminary statistical analysis was performed with the main goal of identifying the intracavitary pathology prevalent in this group of patients and ultimately underlining the prevalence rates of the benign pathology compared to those of the malignant pathology. The non-parametric test of MacNemar and the simple and weighed Cohen's Kappa Statistic were used to assess the agreement between the two diagnostic tests, hysteroscopy and ultrasonography, in the diagnosis of the intracavitary uterine pathologies. After identifying the lack of normality of the variable distributions by the Shapiro-Wilk test, the analysis of the non-parametric variance of Kruskal-Wallis with post-analysis according to Conover was used to assess the differences in the lesion thickness. The Roc analysis was used to seek a statistically valid cut-off for ultrasound thickness to correctly define a suspicion for both polyp and endometrial carcinoma. Finally, the VPP, the VPN, the sensitivity, and the specificity of the hysteroscopy in predicting the risk of malignancy were identified.

RESULTS

An increase in endometrial thickness was ultrasonographically observed in 158 patients, but 53 were symptomatic and thus were excluded. Only 105 women were enrolled in the study, in compliance with the inclusion criteria. The patients were on average 63.3 years old (SD = 8.9), ranging from 46 to 83 years old. As for the ultrasound observations, out of the 105 patients in this

study, 49 exhibited non-homogeneous endometrial thickening and 56 exhibited homogeneous endometrial thickening, corresponding to a percentage of 46.7% and 53.3% of cases, respectively. These observations were made in the light of homogeneous or non-homogeneous echogenicity. The hysteroscopic exam of the 105 patients revealed different patterns: 10 patients (9.5%) exhibited a status of normal endometrium (*i.e.*, an endometrium which is still not totally atrophic), 23 patients (21.9%) had atrophic endometrium, 52 patients (49.5%) had a single benign polyp, 9 patients (8.6%) had multiple polyps, 2 patients (1.9%) had myoma, 6 patients (5.7%) had focal hyperplasia, 1 patient (0.9%) had diffuse hyperplasia and 2 patients (1.9%) had endometrial carcinoma (**Figure 1**). Atrophic endometrium was defined as a non-vascularized, homogeneous, whitish-looking surface of the uterine lining, so thin that it is not easily scratched or subject to biopsy. The visual aspect of focal or diffuse hyperplasia is to be understood as an endometrial area with an inhomogeneous appearance (polypoid or papillary), with abnormal vascularization, with glandular cysts or with anomalous architecture of the glandular outlets. It was defined as diffuse or focal if it involved the entire cavity or not. The histopathological analysis, assumed as diagnosis of certainty, showed that the 105 patients in this study had normal endometrium in 8.6% of cases, atrophic endometrium in 26.7% of cases, single benign polyp in 47.6% of cases, multiple polyps in 8.6% of cases, myoma in 1.9% of cases, focal hyperplasia in 3.8% of cases, diffuse hyperplasia in 0.9% of cases and endometrial carcinoma in 1.9% of cases (**Table 1**). Considering the results, it is noteworthy that, in this particular sample of totally asymptomatic menopausal patients, the endometrial single benign polyp is by far the prevalent pathology, with a percentage of 47.6% of cases.

Within the 105 patients' sample, all of the 10 women taking Tamoxifen and under therapy for breast cancer exhibited an inhomogeneous endometrial thickening in the transvaginal ultrasound. For the same group of patients, the hysteroscopic exam showed normal endometrium in 5 cases (50%), multiple polyps in 2 cases (20%), focal hyperplasia in other 2 cases (20%) and diffuse hyperplasia in one single case (10%). For this subcategory of patients, the histopathological analysis confirmed the hysteroscopic diagnosis in 100% of cases. A comparison between the ultrasound data with the hysteroscopic ones first and then with the histopathological ones was

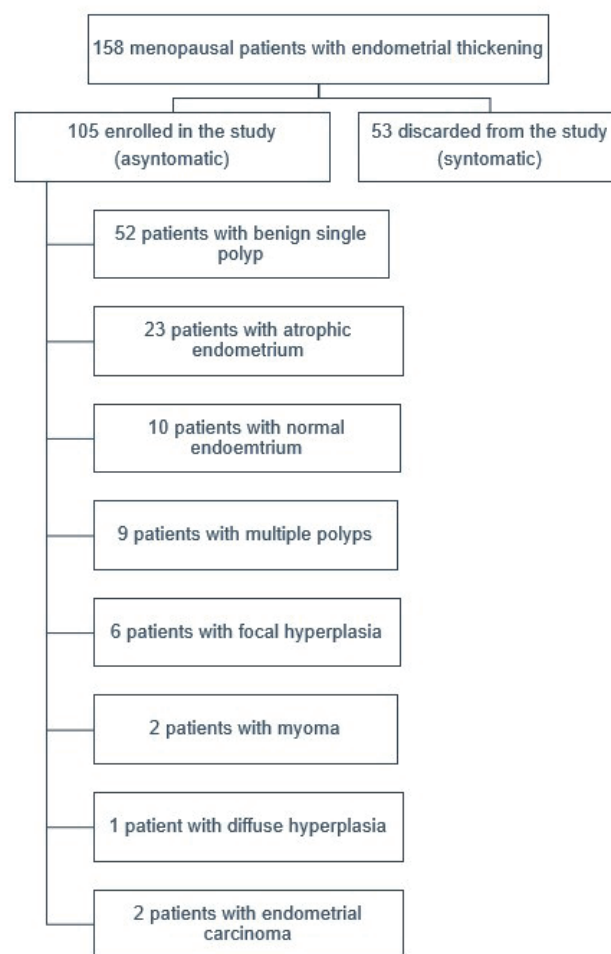


Figure 1. Study population and distribution of pathologies diagnosed on histological examination.

performed. This analysis was conducted with the assumption (frequently used in clinical practice) of associating the finding of a homogeneous thickening with the suspicion of polyp and the finding of an inhomogeneous thickening with the suspicion of all the other pathologies except polyp. For this purpose, the test of McNemar was used to compare the ultrasound data with the hysteroscopic ones first and then with the histopathological ones. In both comparisons, the results of the test were not statistically significant ($p = 0.439$, $p = 0.599$, respectively). The Cohen's Kappa Statistic was then used to assess the agreement between the results of the compared diagnostic tests. The negative value of the simple kappa, both in the ultrasonography/hysteroscopy comparison (-0.1041 ; 95%CI -0.294 to 0.086) and in the ultrasonography/histopathology comparison (-0.1392 , 95%CI -0.328 to 0.0491), suggests that the agreement between the variables in both tests is "worse than chance", in a non-statistically significant way (**Figure 2a,b**).

Table 1. Final histopathological diagnosis of the 105 patients in this study with asymptomatic endometrial thickening.

Histopathological diagnosis	Frequency	Percentage	Cumulative frequency	Cumulative percentage
Normal Endometrium	9	8.6	9	8.6
Atrophic Endometrium	28	26.7	37	35.3
Single benign polyp	50	47.6	87	82.9
Multiple polyps	9	8.6	96	91.5
Myoma	2	1.9	98	93.4
Focal hyperplasia	4	3.8	102	97.2
Diffuse hyperplasia	1	0.9	103	98.1
Endometrial carcinoma	2	1.9	105	100.00

This implies that it is not statistically valid to give a direct association with the suspicion of polyp to the homogeneity data of the endometrial thickening, as well as the ascription of a direct association of all the other suspicions except polyp with a non-homogeneous thickening cannot be considered statistically

valid. Within the ultrasound area, the Kruskal-Wallis non-parametric test was performed, in an attempt to compare the medians of the endometrial ultrasound thickness values for each type of intracavitary uterine pathology later identified by histopathology. The value of $p = 0.000909$ means that the differences in the ultrasound thickness between all the later histopathologically-diagnosed pathologies proved to be statistically significant (Table 2). We then identified the differences among the types of pathologies by performing a post-hoc Conover test (Table 3).

In an attempt to identify a cut-off of endometrial thickening with a greater confidence in suspecting a polyp, we tried to draw a ROC curve. However, it provided discouraging results in that the Area Under the Curve (AUC) was 0.611 ($p = 0.045$). Therefore, we can infer that the value we obtained in this case has a limited diagnostic validity. Nevertheless, the performed ROC analysis shows that the best cut-off for suspected polyp in ultrasonography is ≤ 6 mm, with a sensitivity of just 66.0% and a specificity of just 58.18% (Figure 3).

One of the main goals of the study was to statistically demonstrate the almost perfect correspondence of the hysteroscopic diagnosis with the histopathological diagnosis performed on the tissue sample collected by targeted biopsy. The non-dichotomous qualitative variables relative to the hysteroscopic findings and the histopathological findings were compared with the weighted Cohen's Kappa statistic. The obtained weighted kappa value of 0.9202 (95%CI 0.838; 1.000) shows the almost total agreement between the hysteroscopic and histopathological diagnosis, confirming that hysteroscopy, as a direct endoscopic exam of the uterine cavity, is the only valid exam in the diagnosis of the intracavitary pathologies, especially in asymptomatic postmenopausal patients (Figure 4). Part of our study attempted to identify a cut-off of ultrasound thickness effective for suspecting endometrial carcinoma – a crucial goal that has

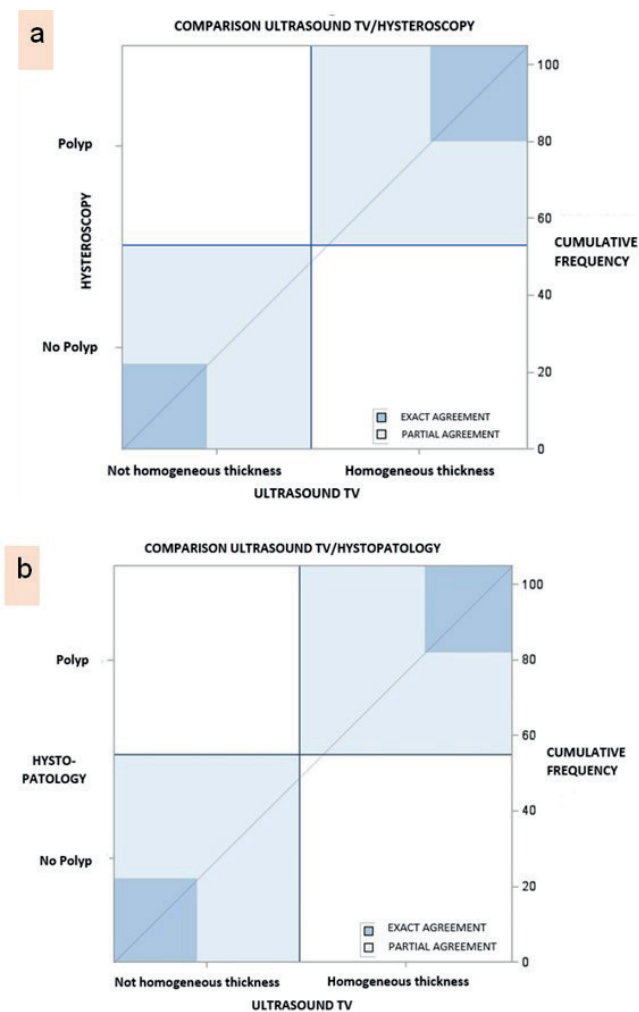


Figure 2. (a) Agreement test chart for ultrasound TV/hysteroscopy and (b) ultrasound TV/histopathology comparison. In the two graphs, the exact match area is dark blue. In both graphs, the dark blue areas are small. In each of the two concordance squares (dark blue), we note the area of the exact concordance between non-homogeneous thickening/no polyp and homogeneous thickening/polyp. In light blue, on the other hand, the area of partial agreement between the compared methods is observed, which is larger than dark blue regions.

Table 2. Results of the Kruskal-Wallis test.

Histopathological diagnosis	Frequency	Minimum thickness (mm)	25 th percentile	Median	75 th percentile	Maximum thickness (mm)
Normal Endometrium	9	4.5000	5.000	6.000	6.000	6.200
Atrophic Endometrium	28	4.2000	5.100	6.200	7.000	11.000
Single benign polyp	50	4.2000	5.000	6.000	7.500	15.000
Multiple polyps	9	6.0000	7.150	8.200	10.625	11.000
Myoma	2	8.0000	8.000	11.500	15.000	15.000
Focal hyperplasia	4	6.0000	6.600	7.700	8.550	8.900
Diffuse hyperplasia	1	8.0000	8.000	8.000	8.000	8.000
Endometrial carcinoma	2	8.2000	8.200	8.600	9.000	9.000

Frequency values, minimum and maximum ultrasound thickness, 25th and 75th percentile and median of thickness values for each of the intracavitary pathologies diagnosed by hysteroscopy and confirmed by histopathological analysis of the tissue sample.

Table 3. Results of the post-hoc analysis of the Kruskal Wallis test according to Conover.

Histopathological diagnosis	Frequency	Statistically significant (P-value < 0.05) difference in thickness in comparison with
Normal endometrium	9	Multiple polyps, Myoma, Focal Hyperplasia, Endometrial Carcinoma
Atrophic endometrium	28	Multiple polyps, Myoma, Endometrial Carcinoma
Single benign polyp	50	Multiple polyps, Myoma, Endometrial Carcinoma
Multiple polyps	9	Normal endometrium, Atrophic endometrium, Single benign polyp
Myoma	2	Normal endometrium, Atrophic endometrium, Single benign polyp
Focal hyperplasia	4	Normal endometrium
Diffuse hyperplasia	1	Normal endometrium
Endometrial carcinoma	2	Normal endometrium, Atrophic endometrium, Single benign polyp

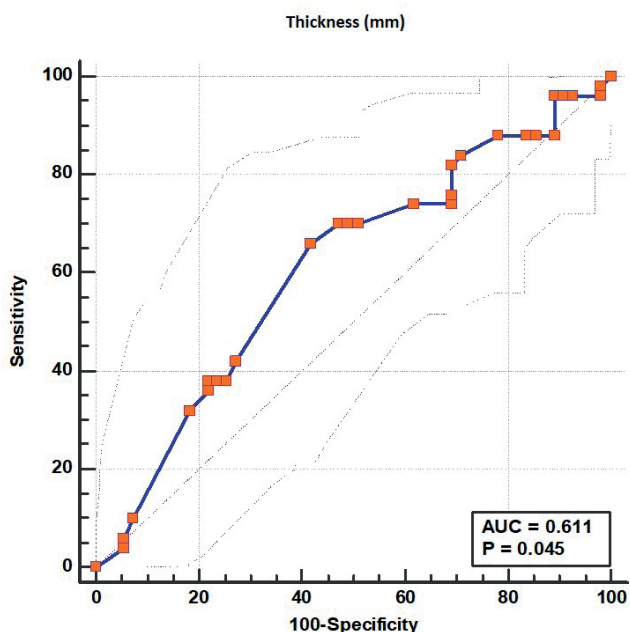


Figure 3. ROC curve for the ultrasound cut-off of the single benign polyp.

long been sought in literature and about which the results are still mixed, particularly for the totally asymptomatic patients. By the ROC analysis, an 8 mm cut-off of ultrasound thickness was identified, above which the suspicion of endometrial carcinoma is strongly solid (Figure 5).

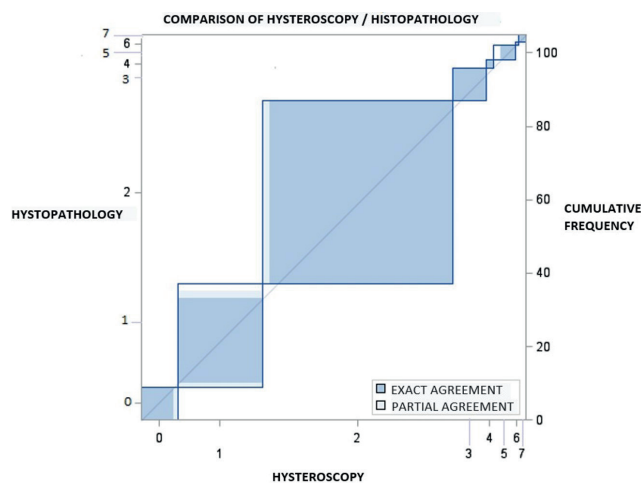


Figure 4. Agreement test chart for hysteroscopy/histopathology comparison. Within each square of the agreement for each pathology, the dark blue area that represents the perfect correspondence of the hysteroscopic diagnosis with the histopathological one is noted. In light blue the infinitesimal area of partial correspondence, only present for some pathologies. 0 = Normal endometrium, 1 = Atrophic endometrium, 2 = Isolated benign polyp, 3 = Multiple polyps, 4 = Myoma, 5 = Focal hyperplasia, 6 = Diffuse hyperplasia, 7 = Endometrial carcinoma.

The same analysis resulted in an AUC of 0.867 (95%CI 0.786-0.925) and a P-value = 0.001. Therefore, the 8 mm cut-off proved to have a specificity of 84.47% and a sensitivity of 100%. We also assessed the effectiveness of the hysteroscopy in predicting the malignancy of the lesion from a statistical point

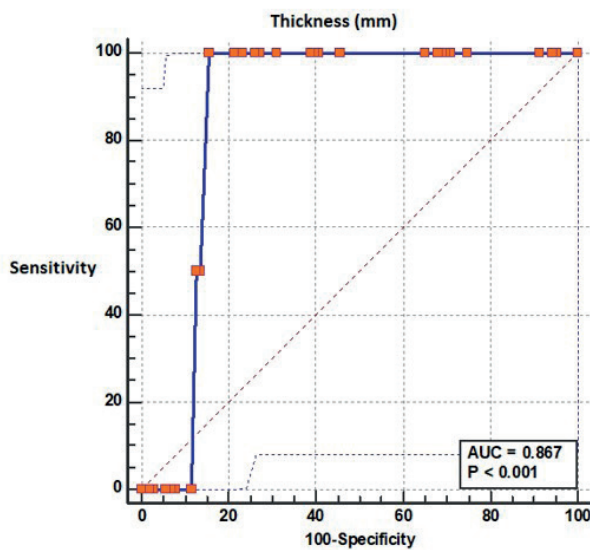


Figure 5. ROC curve for the 8 mm cut-off of endometrial carcinoma.

of view. We considered pathologies representing the risk of malignancy: focal hyperplasia, diffuse hyperplasia and, of course, endometrial carcinoma. Based on the prevalence of the pathologies at risk of malignancy in the sample (6.6%), which represents the pre-test probability, the hysteroscopy was found to have a positive predictive value (PPV) of 100% and a negative predictive value (NPV) of 97.952%, with a specificity of 100% and a sensitivity of 77.78%. These high values demonstrate that hysteroscopy is an extremely valuable diagnostic examination in identifying the risk of malignancy of an endometrial lesion, as also demonstrated by the AUC value of 0.889 for the test validity.

DISCUSSION

We demonstrated that when the thickening in transvaginal ultrasound is identified during a routine check-up in asymptomatic postmenopausal women, there is a minor probability of finding a malignant pathology in subsequent diagnostic tests, *i.e.*, hysteroscopy and histopathological analysis on the biopsy tissue sample. It is noteworthy that we found a malignant pathology or a high risk of preneoplastic lesions only in 6.6% of the patients' sample. The histopathological analysis, considered as a diagnosis of certainty, recognized only 4 cases of focal hyperplasia, 1 case of diffuse hyperplasia and 2 cases of endometrial carcinoma. Among the 105 patients in this study, we mostly

found benign pathologies, even in the 10 asymptomatic patients taking Tamoxifen for mammary carcinoma. The most prevalent pathology in the sample of this study was the single benign polyp, with 50 cases and a percentage of 47.6%. This is a notable result, since it is in agreement with most of the literature reports on asymptomatic postmenopausal patients, where it is largely demonstrated that the benign pathology, and in particular the polyp, is prevalent, compared with the malignant pathology. In the area of ultrasound examination, we attempted to assess if the homogeneity of the endometrium could be the decisive characteristic for suspecting an endometrial polyp with more confidence, in absence of any other elements, except for an endometrial thickening > 4 mm. The comparison between ultrasonography and hysteroscopy first and then between ultrasonography and histopathology did not provide statistically valid results on this issue. In the presence of only endometrial thickening in postmenopausal no bleeding patients, without other ultrasound findings that might raise the suspicion of polyp, the hysteroscopic exam is then crucial to assess which is the actual intracavitary uterine pathology. In the presence of homogeneous endometrial thickening, the ultrasonography cannot exclude all the rest of the pathologies other than polyp. Still using ultrasonography, in this study we could identify statistically significant differences in thickness among the various intracavitary uterine pathologies. From a clinical point of view, this result is particularly relevant in discriminating between benign and malignant pathologies when making a suspected diagnosis in ultrasonography, and in considering whether necessary and urgent or not the subsequent hysteroscopic and histopathological examinations may be. The ROC analysis, performed to identify a possible better thickness cut-off within which a suspect for polyp should be raised in ultrasonography, found a ≤ 6 mm thickness, with an AUC of 0.611, a sensitivity of 66.0% and a specificity of only 58.18%. These results are statistically insufficient to state with certainty the suspicion of polyp upon ultrasonography based only on thickness measurements. Similarly, the same assessment is also not possible considering the homogeneity of the endometrium alone. Concerning the ROC analysis performed to obtain a cut-off value above which it would be possible to raise a more likely suspect of endometrial carcinoma, the analysis provided extremely valid results. The AUC of 0.867 and the P-value of 0.001

demonstrate how an 8 mm thickness cut-off turned out to have a specificity of 84.47% and a sensitivity of 100%. This study points out that in asymptomatic women with an endometrial thickness > 8 mm, the probability of diagnosing endometrial cancer is high, so it is necessary to consider the hysteroscopy urgent, in order to obtain a diagnosis as early as possible. This statement is in agreement with the findings of Seckin *et al.* [20]. The cut-off obtained in our study (8 mm) is, on the other hand, lower than that declared in another scientific study, with a 9 times greater sample, in which it was fixed at 11 mm [21]. In contrast to these numerical determinations is the systematic review conducted by Breijer *et al.*, which, despite the large number of studies analysed, could not define a certain cut-off due to the imprecision of the data reported in the literature and leaned towards cut-off values lower than 8 mm [22]. Changes of a few millimetres significantly shift clinical practice. By decreasing the cut-off from 11 to 7 mm, the cancer detection rate would increase slightly (from 87% to 95%), but the false-positive rate would nearly quadruple (from 0.25% to 0.90%) [8].

For all these reasons, it will be necessary to expand the sample analysed in our research with the aim of producing scientific material that is more reliable and more easily comparable with studies with larger samples. One limitation of the study is, in fact, the number of the patients in the sample.

The main goal of the study was to analyse the extent of correlation between the hysteroscopic and histopathological diagnosis, performed on a tissue sample harvested by targeted biopsy. The analyses performed on our 105 patients sample highlight an almost perfect agreement between the two variables, demonstrating that hysteroscopy, being a direct endoscopic exam of the uterine cavity, allows to perform a correct and reliable diagnosis in almost all cases, which will then be confirmed by pathological anatomy.

It can be assumed that diagnostic improvements could result from the use of high-definition cameras, but also from additional procedural methods such as using carbon dioxide for uterine distension. Carbon dioxide has the same refractive index as air, therefore provides clear images of the endometrial cavity, making it an excellent endoscopic means for visualizing the uterine cavity. Its use reduces pain in patients and the time of the diagnostic procedure, allowing the operator to act in the best possible conditions [23].

CONCLUSIONS

The results of this study don't justify the use of endometrial thickness as a screening test for endometrial carcinoma and atypical endometrial hyperplasia in any asymptomatic postmenopausal woman. Endometrial cancer is usually associated with vaginal bleeding and the risk of cancer is very low in women without symptoms. In asymptomatic women the index of suspicion for underlying cancer should be extremely high to warrant an invasive endometrial biopsy on the basis of imaging findings alone. The decision to perform a hysteroscopy with biopsy should therefore take into account the patient's age, parity, BMI and pathological and family anamnesis. Lowering the cut-off threshold of the endometrial thickness too much, on the other hand, is equivalent to increasing the number of biopsies, most of which are superfluous, with a minimal advantage in terms of early diagnosis. No cut-off could ever guarantee 100% sensitivity and specificity, since any endometrial thickening is a potential tumour indicator, albeit with increasing probabilities. It is neither convenient nor strategic to exceed in diagnostic biopsies [8].

Within this study, we further demonstrated the effectiveness of hysteroscopy in predicting the risk of malignancy, considering for this point the hysteroscopic findings of focal hyperplasia, diffuse hyperplasia and endometrial carcinoma, and comparing them with the histopathological diagnosis. We found that the hysteroscopy has a positive predictive value (PPV) of 100% and a negative predictive value (NPV) of 97.952%, with a specificity of 100% and a sensitivity of 77.78%. These values demonstrate that the hysteroscopy could be considered the gold standard for the diagnosis of malignant endometrial pathology or an endometrial condition at severe risk of malignancy, since it has a positive predictive value of 100%, a negative predictive value around 90-100% and very high values of sensitivity and specificity.

Our study allows to obtain a great benefit on the planning of surgeries in medical practice. The hysteroscopic patterns that suggest a malignant pathology allow to guide patients, especially asymptomatic ones, early on to the presurgical path, thus saving time, while waiting for the validating histological report in a more rapid regime.

COMPLIANCE WITH ETHICAL STANDARDS

Authors contributions

P.P.: Study design, clinical participation, supervision. A.S., G.C.: Data collection, clinical participation, writing – original draft. A.D'A.: Supervision. S.N.: Statistical evaluation. M.G.: Study design, clinical participation, supervision.

Funding

None.

Study registration

The IRB of the University of L'Aquila gave approval to this case study with protocol number: 032019.

Disclosure of interests

The authors declare that they have no conflict of interests.

Ethical approval

All procedures performed in studies involving human participants were in accordance with the ethical standards of the institutional and/or national research committee and with the 1964 Helsinki declaration and its later amendments or comparable ethical standards. "Standards for Reporting Diagnostic accuracy studies" (STARD 2015) were adopted by authors.

Informed consent

Informed consent was obtained from all individual participants included in the study.

Data sharing

Data are available under reasonable request to the corresponding author.

REFERENCES

1. Bachmann LM, ter Riet G, Clark TJ, Gupta JK, Khan KS. Probability analysis for diagnosis of endometrial hyperplasia and cancer in postmenopausal bleeding: an approach for a rational diagnostic workup. *Acta Obstet Gynecol Scand.* 2003;82(6):564-9. doi: 10.1034/j.1600-0412.2003.00176.
2. Carta G, Iovenitti P, Buttari F, D'Alfonso A, Pestilli S. L'isteroscopia diagnostica nel terzo millennio. Indicazioni e ruolo [Diagnostic hysteroscopy in the third millennium. Indications and role]. *Minerva Ginecol.* 2003;55(2):159-65. Italian. Available at: <https://pubmed.ncbi.nlm.nih.gov/12712001/>.
3. Lev-Sagie A, Hamani Y, Imbar T, Hurwitz A, Lavy Y. The significance of intrauterine lesions detected by ultrasound in asymptomatic postmenopausal patients. *BJOG.* 2005;112(3):379-81. doi: 10.1111/j.1471-0528.2004.00444.x.
4. Goldstein SR, Monteagudo A, Popiolek D, Mayberry P, Timor-Tritsch I. Evaluation of endometrial polyps. *Am J Obstet Gynecol.* 2002;186(4):669-74. doi: 10.1067/mob.2002.122128.
5. Ferrazzi E, Zupi E, Leone FP, Savelli L, Omodei U, Moscarini M, et al., How often are endometrial polyps malignant in asymptomatic postmenopausal women? A multicenter study. *Am J Obstet Gynecol.* 2009;200(3):235.e1-6. doi: 10.1016/j.ajog.2008.09.876.
6. Adomaitienė L, Nadišauskienė R, Nickkho-Amiry M, Čižauskas A, Palubinskienė J, Holland C, et al. Proliferation in Postmenopausal Endometrial Polyps-A Potential for Malignant Transformation. *Medicina (Kaunas).* 2019;55(9):543. doi: 10.3390/medicina55090543.
7. Gambacciani M, Monteleone P, Ciaponi M, Sacco A, Genazzani AR. Clinical usefulness of endometrial screening by ultrasound in asymptomatic postmenopausal women. *Maturitas.* 2004;48(4):421-4. doi: 10.1016/j.maturitas.2003.10.006.
8. Smith-Bindman R, Weiss E, Feldstein V. How thick is too thick? When endometrial thickness should prompt biopsy in postmenopausal women without vaginal bleeding. *Ultrasound Obstet Gynecol.* 2004;24(5):558-65. doi: 10.1002/uog.1704.
9. Di Luigi G, D'Alfonso A, Patacchiola F, Di Stefano L, Palermo P, Carta G. Leiomyosarcoma: a rare malignant transformation of a uterine leiomyoma. *Eur J Gynaecol Oncol.* 2015;36(1):84-7. Available at: <https://pubmed.ncbi.nlm.nih.gov/25872341/>.
10. American College of Obstetricians and Gynecologists Committee on Gynecologic Practice. ACOG committee opinion. No. 336: Tamoxifen and uterine cancer. *Obstet Gynecol.* 2006;107(6):1475-8. doi: 10.1097/00006250-200606000-00057.

11. Cohen I. Endometrial pathologies associated with postmenopausal tamoxifen treatment. *Gynecol Oncol.* 2004;94(2):256-66. doi: 10.1016/j.ygyno.2004.03.048.
12. Pérez-Medina T, Salazar FJ, San-Frutos L, Ríos M, Jiménez JS, Troyano J et al. Hysteroscopic dynamic assessment of the endometrium in patients treated with long-term tamoxifen. *J Minim Invasive Gynecol.* 2011;18(3):349-54. doi: 10.1016/j.jmig.2010.12.014.
13. Chiofalo B, Mazzon I, Di Angelo Antonio S, Amadore D, Vizza E, Laganà AS, et al. Hysteroscopic Evaluation of Endometrial Changes in Breast Cancer Women with or without Hormone Therapies: Results from a Large Multi-center Cohort Study. *J Minim Invasive Gynecol.* 2020;27(4):832-9. doi: 10.1016/j.jmig.2019.08.007.
14. Mangano U, Garofalo A, Cannavò A, Santocinto V, Rapisarda V, Coco L, et al. Confronto tra ecografia vaginale ed isteroscopia diagnostica nella valutazione delle patologie uterine intracavitari in donne in post menopausa. *Giornale Italiano di Ostetricia e Ginecologia.* 2010;32(3):170-5. Available at: <http://eprints.bice.rm.cnr.it/6405/>.
15. Benati M, Montagnana M, Danese E, Mazzon M, Paviati E, Garzon S, et al. Aberrant Telomere Length in Circulating Cell-Free DNA as Possible Blood Biomarker with High Diagnostic Performance in Endometrial Cancer. *Pathol Oncol Res.* 2020;26(4):2281-9. doi: 10.1007/s12253-020-00819-x.
16. Cignini P, Vitale SG, Laganà AS, Biondi A, La Rosa VL, Cutillo G. Preoperative work-up for definition of lymph node risk involvement in early stage endometrial cancer: 5-year follow-up. *Updates Surg.* 2017;69(1):75-82. doi: 10.1007/s13304-017-0418-z.
17. Casarin J, Bogani G, Piovano E, Falcone F, Ferrari F, Odicino F, et al. Survival implication of lymphadenectomy in patients surgically treated for apparent early-stage uterine serous carcinoma. *J Gynecol Oncol.* 2020;31(5):e64. doi: 10.3802/jgo.2020.31.e64.
18. Casarin J, Bogani G, Serati M, Pinelli C, Laganà AS, Garzon S, et al. Presence of Glandular Cells at the Preoperative Cervical Cytology and Local Recurrence in Endometrial Cancer. *Int J Gynecol Pathol.* 2020;39(6):522-8. doi: 10.1097/PGP.0000000000000642.
19. Carta G, Palermo P, Marinangeli F, Piroli A, Necozone S, De Lellis V, Patacchiola F. Waiting time and pain during office hysteroscopy. *J Minim Invasive Gynecol.* 2012;19(3):360-4. doi: 10.1016/j.jmig.2012.01.017.
20. Seckin B, Cicek MN, Dikmen AU, Bostancı EI, Muftuoglu KH. Diagnostic value of sonography for detecting endometrial pathologies in postmenopausal women with and without bleeding. *J Clin Ultrasound.* 2016;44(6):339-46. doi: 10.1002/jcu.22329.
21. Hefler L, Lafleur J, Kickmaier S, Leipold H, Siebenhofer C, Tringler B, et al. Risk of endometrial cancer in asymptomatic postmenopausal patients with thickened endometrium: data from the FAME-Endo study: an observational register study. *Arch Gynecol Obstet.* 2018;298(4):813-20. doi: 10.1007/s00404-018-4885-3.
22. Breijer MC, Peeters JA, Opmeer BC, Clark TJ, Verheijen RH, Mol BW, Timmermans A. Capacity of endometrial thickness measurement to diagnose endometrial carcinoma in asymptomatic postmenopausal women: a systematic review and meta-analysis. *Ultrasound Obstet Gynecol.* 2012;40(6):621-9. doi: 10.1002/uog.12306.
23. Tagliaferri V, Ricciardi L, Ricciardi R, Pinto LR, Lanzone A, Scambia G, et al. Carbon dioxide in office diagnostic hysteroscopy: An open question. A multicenter randomized trial on 1982 procedures. *Eur J Obstet Gynecol Reprod Biol.* 2019;235:97-101. doi: 10.1016/j.ejogrb.2018.09.041.